



Original Research Paper Journal homepage: <https://journal.uokufa.edu.iq/index.php/ajb/index>

Cytotoxicity Effects of Azithromycin and Curative of Garlic on Sperm Mortality and Testicular Tissue of Albino Male Rats

Jasim S. M. A.

Biology Department, Faculty of Science, University of Kufa, Iraq

Article history

Received: 10 / 6 /2023

Revised: 17 / 7 /2023

Accepted: 19 / 6 /2023

DOI:

10.36320/ajb/v15.i2.13330

*Corresponding Author:

Email:

shimaam.jasim@uokufa.edu.iq

Abstract: *The current study aimed to identify the adverse effects of azithromycin drug and the protective role of garlic in cytotoxicity tests that included sperm deformation and histological changes in testes tissue of male albino rats. Twenty-four mature male rat animals (*Rattus norvegicus*) were used in the present study, their age was (2.5 – 3) months, and their weight ranged from 148 to 280 gm they were divided into four groups as follows:*

The first group was the control group contained four rats and was administered distilled water only. In contrast, the second group containing four rats was administered garlic at 480 mg/kg body weight. The third group included eight rats, was administered Azithromycin at the dose of 500 mg/kg body weight. The fourth group contained eight rats, and Azithromycin was administered at 500 mg/kg mg+ garlic at 480 mg/kg body weight. The groups were treated with Azithromycin and garlic daily. The results recorded a significant increase ($p \leq 0.05$) in sperm head and tail deformation rate in the group administered Azithromycin + garlic compared with the control groups that were administered distilled water and garlic. Furthermore, the results reported a significant decrease ($p \leq 0.05$) in sperm head and tail deformation rates in the group administered Azithromycin + garlic compared with the only Azithromycin administered group. Moreover, the study indicated histological changes in testes tissue included degenerative changes represented by depletion of the spermatogonial cells (some seminiferous tubules appeared with one or two layers of spermatogonia) in the group that was administered Azithromycin compared with the control group, which was administered distilled water and garlic. In addition, the study indicated slight histological changes in testes tissue compared with standard testes architecture, somniferous tubules with the maturation of spermatogony, and sperms inside the lumen in groups administered Azithromycin and garlic compared with control groups, which were administered distilled water and garlic. Finally, the findings showed a reduction in histological changes in testes tissue in the group that was administered azithromycin+garlic compared with the group that was administered Azithromycin only..

Keywords: *Azithromycin, Garlic, testicular damage, testis, sperms*

1. Introduction

Azithromycin is one of the cytotoxic drugs; it is known as a broad-spectrum bacteriostatic antibiotic, belongs to macrolides with a long half-life, and has an excellent ability to penetrate tissue [1]. This macrolide has shown antibacterial, antiviral, and immunomodulatory activities that could interest viral infections, including COVID-19 [2].

Azithromycin can also cause tissue damage through direct cytotoxic effects on the infected cells; morbidity and mortality in severe diseases are typically attributable to the host inflammatory response [3]. Azithromycin had adverse side effects on the male rat genital system by decreasing the reproductive organs' index weight and sperm motility. Sperm abnormalities increased at varying times post-treatment with azithromycin administration [4].

Garlic (*Allium sativum* L.) has been widely accepted as an essential dietary component for centuries and an excellent source of pharmacologically active ingredients [5]. Phytochemicals of garlic have the potential for the improvement of the immune system against diseases in humans. Diverse bioactive compounds, such as allicin, alliin, diallyl sulfide, diallyl disulfide, diallyl trisulfide, ajoene, and S-allyl-cysteine exhibit antioxidant, anti-inflammatory, antibacterial, antifungal, immunomodulatory, cardiovascular protective, anticancer, hepatoprotective, digestive system protective, anti-diabetic, anti-obesity, neuroprotective, and renal protective properties [6].

The aim of this study to identify the cytotoxic effect of Azithromycin drug and the protective role of garlic by improving and enhancing Azithromycin's adverse effects.

2. Methodology

Experimental Design: The animal groups were administered the azithromycin drug and garlic orally for two weeks, divided into four groups, and classified according to the dose of the treatment as follows:

The first group, the control group, contained four rats and was administered distilled water only, while the second group included four rats and was administered garlic at 480 mg/kg body weight. The third group, which contained eight rats, was administered Azithromycin at 500 mg/kg body weight. The fourth group, which included eight rats, was administered azithromycin 500 mg/kg and Garlic 480 mg/Kg body weight.

Solutions:

1. Azithromycin solution was prepared by dissolving tablets directly in a concentration of 500 mg per 5 ml of distilled water.
2. A garlic solution was prepared by dissolving 480 mg/kg body weight of garlic powder in 13 ml of distilled water and was administered for two weeks by oral route.

Sperm Preparation:

Sperm cells have been prepared according to [7], as follows:

1. The animal was anaesthetized with chloroform, as evidenced on a platter of anatomy; it was cut at the bottom of the abdominal cavity, and the testes and epididymis were extracted.
2. The white coat was removed, and the epididymis were crushed in the Phosphate Buffer saline.
3. The swab slide was worked on and left to dry in the air.
4. The smears were fixed with some drops of methanol for two minutes.
5. Slides were stained with Methyl blue stain for 13 minutes, then washed with Phosphate buffer solution.
6. Slides were left to dry and then examined under the microscope at 40x to observe the abnormalities in sperm cells in both the head and tail per 100 cells.

Histopathological study:

Tissue specimens were prepared to study histological changes in testis tissues of experimental animals that were dehydrated in 70% ethanol, embedded in paraffin, and cut into six mm-thick sections using a rotary microtome, according to [8]. The tissue

sections were stained with hematoxylin and eosin dyes and visualized under a light microscope to observe histological changes in the testis.

Statistical Analysis:

The data were statistically analyzed using SPSS (a statistical package for social sciences). The independent sample t-test, ANOVA (one-way analysis of variance), All values were expressed as means ± standard deviation of the mean. p –value less than 0.05 was considered statistically significant.

3.Results and Discussion

Maceration method

The findings of the present research recorded a significant increase (p≥0.05) in sperm head and tail deformation rate per 100 cells in groups that were administered azithromycin and azithromycin+ garlic for two weeks in comparison with the control group, which was administered distilled water and garlic, as shown in table (1) and (2).

While the study revealed a significant decrease (p≥0.05) in sperm head and tail deformation rate per 100 cells in groups administered Azithromycin + garlic for two weeks compared with groups administered Azithromycin only.

Table (1) Effect of Azithromycin and garlic for two weeks on the sperm head deformation rate in male albino rats.

Groups Type of deformation	Control (Distilled water)	Garlic	Azithromycin	Azithromycin +Garlic
Amorphous shape	9.0±0.00	0.00±0.00	18.3±1.80 ac	14.7±0.50 abc
Banana shape	9.3±1.44	0.00±0.00	13.3±0.90 ad	9.5±0.50 abc
Hummer shape	0.00±0.00	0.00±0.00	11.2±1.30 ac	6.3±0.00 abc
Head less	8.30±0.37	0.00±0.00	14.7±1.90 ac	9.00±0.00 abc
Striate shape	0.00±0.00	0.00±0.00	14.5±2.1 ac	9.5±0.50 abc

Swollen head	0.00±0.00	0.00±0.00	7.6±0.70 ac	0.00±0.00 c
Blunt hook	8.3±0.00	2.35±0.16	13.3±0.90 ac	7.6±0.00 abc
Total	34.9±1.81	2.35±0.16	92.9±9.6	56.6±0.10

The mean values for the mean ± the standard deviation (Mean ± S.D) (a) significant difference (p≤0.05) with the control treated with distilled water (b): significant p≤0.05 difference with control treated with garlic c: significant difference (p≤0.05) between azithromycin+garlic and Azithromycin groups. Table (2) Effect of Azithromycin and garlic for two weeks on the sperm tail deformation rate in male albino rats.

Groups Type of deformation	Control (Distilled water)	Garlic	Azithromycin	Azithromycin +Garlic
Tail less	0.00±0.00	2.27±0.1	12.5±0.00a c	9.0±0.00abc
Double tail	0.00±0.00	0.00±0.00	0.00±0.00	0.00±0.00
Bent tail	0.00±0.00	0.00±0.00	14.2±0.00a c	7.60±0.00ab c
Curved tail	8.90±0.74	2.35±0.16	13.9±1.30a	12.20±3.70a b
Coiled tail	8.30±0.00	0.00±0.00	20.0±2.00a c	15.30±0.00 abc
Short tail	0.00±0.00	0.00±0.00	11.0±1.00a c	5.9±1.30c
Total	17.2±0.74	4.62±0.26	66.5±4.00	50.00±5.00

The mean values for the mean ± the standard deviation (Mean ± S.D) (a) significant difference (p≤0.05) with control treated with distilled water (b): significant difference (p≤0.05) with control treated with garlic; c: significant difference (p≤0.05) between azithromycin+garlic and Azithromycin groups.

Sperms abnormalities:

The findings in Tables (1) and (2) agree with [9], who mentioned that Azithromycin had a negative impact on sperm motility and the quantity of spermatozoa in male albino rats. In addition, the results agree with [10], who recorded that azithromycin administration after a few days has an adverse effect on the male reproductive organs, spermogram, by increasing sperm abnormalities and altering testicular oxidative stress markers of adults’

male albino rats by decreasing malondialdehyde level and superoxide dismutase enzyme activity.

Furthermore, the results agree with [11], who found that Azithromycin had a negative impact on white rats by causing breakdowns and DNA abnormalities.

The current research indicated several types of sperm head abnormalities in groups administered Azithromycin and Azithromycin + garlic, including amorphous shape, banana shape, hummer shape, headless shape, striate shape, swollen head, and blunt hook head Figure (1).

Moreover, the present research indicated several types of sperm tail abnormalities in groups administered azithromycin drug and azithromycin+ garlic, including tail-less sperm, double tail, bent tail, curved, coiled, and short tail Figure (2).




Figure (1): Head Sperm abnormalities in male albino rats. A: normal head sperm from the control group treated with distilled water. B: banana shape head. C: hummer-shaped head. D: amorphous head; E: the pointed heads show striate, missed, and detached heads; F: striate head; G: Blunted hook. H: Swollen head from the group treated with Azithromycin. I: a: amorphous head; b: blunt hook from the group treated with azithromycin+garlic (40x).




Figure (2): Tail Sperm abnormalities in male albino rats A: normal tail sperm from the control group treated with distilled water. B-C: tail-less sperm. D: coiled tail. E: coiled tail from the group. F: bent tail. G: double tail from the group treated with Azithromycin. H: short tail from the group treated with Azithromycin and garlic. I: curved tail from the group treated with Azithromycin (40x).

Histopathological study:

The current research indicated the presence of histological changes induced by azithromycin drug administration on testes through a study of testes tissue in male albino rats when they were administered Azithromycin at 500 mg/Kg body weight for two weeks. Furthermore, the results also indicated the protective role of garlic and its ability to reduce the histological changes in the testes tissue Figure (3).

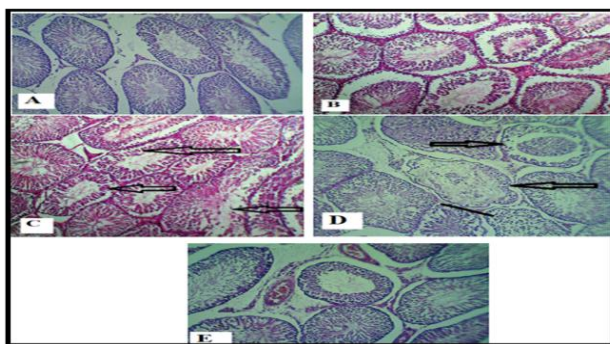


Figure (3) Cross-section of testes in male albino rats A: control group treated with distilled water showing no change in testes architecture. B-D from the group treated with Azithromycin showing degenerative changes represented depletion of the spermatogonial cells (some seminiferous tubules appeared with one or two layers of spermatogonia and in picture D: absence of Leydig cells. E: from the group treated with Azithromycin + garlic showing the slight change from typical testes architecture, somniferous tubules with the maturation of spermatogony and sperms inside the lumen (H&E X 100).

The results of the study shown in Figure 3 are supported by [12], who mentioned that although drugs are beneficial when used at therapeutic levels, the adverse side effects lead to impairment of hypothalamic-pituitary-

gonadal functions, increased sperm DNA fragmentation and apoptosis, and reduced sperm quality.

In addition, the findings agree with [13], who mentioned that azithromycin treatment induced testicular dysfunction by causing histopathological changes in the reproductive organs (testes, epididymis, seminal vesicle) and prostate in male albino rats.

The results of the study shown in Figure 3 are supported by [12], who mentioned that although drugs are beneficial when used at therapeutic levels, the adverse side effects lead to impairment of hypothalamic-pituitary-gonadal functions, increased sperm DNA fragmentation and apoptosis, and reduced sperm quality. Moreover, the results agreed with [14], who said that macrolide antibiotics (Azithromycin is one of its macrolide members) induced oxidative damage mechanisms and lipid peroxidation by altering physiological redox homeostasis.

Furthermore, the findings agree with [6], who recorded that garlic possesses several biological properties, including renoprotective, antioxidant, anticarcinogenic, and anti-diabetic activities in traditional medicines. Finally, the results agree with [15, 16 and 17], who mentioned that aged garlic extract contains natural disulfoxide compounds that act as antioxidants, regenerate peripheral tissue perfusion, and increase microcirculation in patients with arteriosclerosis—this induced tissue repair by reducing lipid peroxidation.

Conclusions

Azithromycin drug administration at a dose of 500 mg/kg body weight for two weeks significantly increased the sperm head and tail deformation rate per 100 cells in male albino rats compared with controls. Garlic reduced the histological changes in rat testes and showed a protective and improving role against azithromycin cytotoxicity and testicular damage. This positive effect of garlic was achieved during administration for two weeks at a dose of 480 mg/kg body weight.

Ethics statement:

All animal experiments were performed according to guidelines by the Guide for the Care and Use of Laboratory Animals after approval had been obtained from the Central Committee for Bioethics of Kufa University.

References

1. Doan, T., Hinterwirth, A., Arzika, A. M., Cotter, S. Y., Ray, K. J., O'Brien, K. S., ... & Lietman, T. M. (2018), Mass azithromycin distribution and community microbiome: a cluster-randomized trial. In *Open forum infectious diseases* August. (Vol. 5, No. 8, p. ofy182). US: Oxford University Press. <https://doi.org/10.1093/ofid/ofy182>
2. Echeverría-Esnal, D., Martín-Ontiyuelo, C., Navarrete-Rouco, M. E., De-Antonio Cuscó, M., Ferrández, O., Horcajada, J. P., & Grau, S. (2020). Azithromycin in the treatment of covid-19 a review. *Expert review of anti-infective therapy*, 1-17. <https://doi.org/10.1080/14787210.2020.1813024>
3. Oliver, M. E., & Hinks, T. S. (2020). Azithromycin in viral infections. *Reviews in medical virology*. e2163. <https://doi.org/10.1002/rmv.2163>
4. El-Sayed, M., Kandiel, M., & Ebied, D. (2017). Changes in reproductive organs, semen characteristics and intra-testicular oxidative stress in adult male rats caused by Azithromycin. *International Journal of Pharmacology and Toxicology*. 2017 . 5(2), 72–79. doi: 10.14419/ijpt.v5i2.7778
5. Shang, A., Cao, S. Y., Xu, X. Y., Gan, R. Y., Tang, G. Y., Corke, H., ... & Li, H. B. (2019). Bioactive compounds and biological functions of garlic (*Allium sativum* L.). *Foods*. 8(7), 246. <https://doi.org/10.3390/foods8070246>
6. El-Saber Batiha, G., Magdy Beshbishy, A., G Wasef, L., Elewa, Y. H., Al-Sagan, A., El-Hack, A., ... & Prasad Devkota, H. (2020). Chemical constituents and pharmacological activities of garlic (*Allium sativum* L.): A review. *Nutrients*. 12(3), 872. <https://doi.org/10.3390/nu12030872>
7. Seed J, Chapi RE, Clegg ED, Dostal LA, Foote RE, Hurtt ME, Klinefelter GR, Makris SL, Perreault SD, Schrader S, Seyler D, Sprando R, Treinen K A, Rao Veerama -chaneni DN, Wise LD: (1996). Methods for assessing sperm

- motility, morphology, and counts in the rat, rabbit, and dog: a consensus report. *Reprod Toxicol.* . 10 (3): 237-244. 10.1016/0890-6238(96)00028-7. [https://doi.org/10.1016/0890-6238\(96\)00028-7](https://doi.org/10.1016/0890-6238(96)00028-7)
8. Bancroft J. and Stevens A. **.(1999)**. Theory and practice of Histological Technique .4th .New York : *Churchill Livingstone* 1999,113-118. <https://doi.org/10.1111/j.1365-2559.tb00755.x>
 9. Chi-Gunchzhi, U. A., Omelich, E. V., Pchelina, K. E., Barannikov, S. V., Baldanov, E. V., Shikulskiy, A. S., ... & Tseluyko, S. S. **.(2017)**. The effect of Azithromycin on sperm motility and quantity of spermatozoa. *Амурский медицинский журнал.* 2017. (4 (20)), 13-14. DOI: 10.22448/AMJ.4.13-14
 10. Kandiel, M., & Ebied, D. D. I. A. **.(2017)**. Changes in reproductive organs, semen characteristics and intra-testicular oxidative stress in adult male rats caused by Azithromycin. *International Journal of Pharmacology and Toxicology.* . 5(2), 72-79. doi: 10.14419/ijpt.v5i2.7778
 11. Jassab, H. K., Alghanimi, Y. K., & Alsafy, A. H. M. **.(2021)**. effect of Azithromycin on some genetic parameters and protective role of vitamin c in male white rats. docid: <https://connectjournals.com/03896..21.4789>
 12. Ajayi, A. F., & Akhigbe, R. E. (2020). Staging of the estrous cycle and induction of estrus in experimental rodents: an update. *Fertility research and practice*, 6(1), 1-15.
 13. Abeer, M. N. H.. (2015). The protective effect of some natural antioxidants against Azithromycin induced testicular dysfunction in rats. *American International Journal of Contemporary Scientific Research.* . 2(5), 39-40.
 14. Kumar V, Harjai K, and Chhibber S. **.(2008)**. Effect of clarithromycin on lung inflammation and alveolar macrophage function in Klebsiellapneumoniae B5055-induced acute lung infection in Balb/C mice. *J Chemother.* . 20:609-614. <https://doi.org/10.1179/joc.2008.20.5.609>
 15. Lindstedt, S., Wlosinska, M., Nilsson, A. C., Hlebowicz, J., Fakhro, M., & Sheikh, R. **.(2021)**. Successful improved peripheral tissue perfusion was seen in patients with atherosclerosis after 12 months of treatment with aged garlic extract. *International Wound Journal.* . 18(5), 681-691. <https://doi.org/10.1111/iwj.13570>
 16. Khan, M. S., Qureshi, N. A., Jabeen, F., Wajid, M., Sabri, S., & Shakir, M. **.(2020)**. The role of garlic oil in the amelioration of oxidative stress and tissue damage in rohu *Labeo rohita* treated with silver nanoparticles. *Fisheries Science.*, 86(2), 255-269. <https://doi.org/10.1007/s12562-020-01403-7>
 17. Sajitha, G. R., Augusti, K. T., & Jose, R. **.(2016)**. Prophylactic effects of garlic oil and onion oil fractions as compared to vitamin E on rats orally fed with lead acetate solution. *Indian Journal of Clinical Biochemistry.* .31(3), 260-269. <https://doi.org/10.1007/s12291-015-0526-9>