

# Some Histological description of lingual papillae in the Millivora capenesis tongue

Tawfeeq jawad ali

Lectural community health department Technical institute of kufa

## Abstract

The present study was conducted on three tongues of Millivora capenesis animal. Histologically, the dorsal surface was covered by keratinized stratified squamous epithelium, while the ventral surface which covered via non-keratinized stratified squamous epithelium. Five types (filliform, conical, fungi form, circumvallate and foliate) papillae were project and distributed on dorsal and lateral surface. The filliform was similarly to threads or like hairs, while conical was cylindrical shaped. The fungi form papillae like the mushroom, the wall contain taste buds, but the circumvallates papillae circular in shape and embedded in the epithelium, the foliate papillae was similar ridges, both circumvallate and foliate papillae were contain taste buds.

## Introduction

The morphology and histology description of the tongue of domestic mammals was studied (1). Much researches has been carried out on the dorsal surface of tongue in different animals such as cow(2), buffaloes(3), one\_humped camel(4), horse(5), goat(6), and lesser mouse deer(7). The Millivora capenesis belonged to kingdom

:Animal, phylum: chordate, class: Mammals, Order: Carnivora, Family: Mustelidae, Subfamily: Mellivorina, Genus: Mellivora and Species: Capenesis (8). These wild animals which called honey badger and are Omnivorous and feed on insects, amphibians, reptiles, birds, and mammals, besides roots, bulbs, berries and fruits(9), favorite foods are honey and larvae of honeybees (10).

There are three types of gustatory papillae in mammals distributed in a rostral-caudal axis, the fungiform Papillae are distributed on the anterior two-third of the tongue, the foliate papillae are found at the junction of the anterior two-third and the posterior of one-third of the tongue, and the circumvallate papillae are found in the posterior one-third of the tongue (11). Under the lingual epithelium of all domestic mammals is loose connective tissue, which makes up the lamina propria and extends to continue as the epimysium and perimysium that surrounds the various muscle bundles(12).

The aim of present study to understand the kind of lingual papillae and histological description of millivora capenesis tongue.

## Materials and Methods

Three tongues from adult females Millivora capenesis animals was killed by farmers which live in agriculture regions which surrounding the Diwaniya and Najaf cities. The average weight was ranged (15-20)kg, and animal age (three-four) years old, was determined according to (13). The tongues were removed from the head of

animals, then washed with normal saline after that fixed in (10%) formalin, the routine histological preparations such as dehydration by graduated conc. Of ethyl alcohol, clearing by xylol and embedding via paraffin wax was carried out to make up histological blocks. The tissue sections were cut at (six) micrometer via using rotatory microtome, and the histological slides were stained with routine stains (Hematoxylin and Eosin) according to method(14).

## Results and Discussion

Histologically, the present study was revealed, the dorsal and ventral surface of Millivora capensis tongue covered by Keratinized stratified squamous epithelium, and the sub epithelium layer consist of loose connective tissue which revealed, small blood vessels and nerve endings, the lingual papillae were projected from the dorsal surface of Millivora capensis tongue (figure 1) , which included, filiform papillae, conical papillae that represented the mechanical papillae without taste – buds. Our present study differed with previous study (15), they mentioned, the filliform papillae of dogs and cats had heavy stratum corneum, and our findings not agreement with previous investigators which done on the filiform of rats , they mentioned, the filiform and conical(16) papillae were found in large number on the dorsal surface of rat tongue. The gustatory lingual papillae of Millivora capensis tongue was involved, fungi form, circumvallated and foliate papillae were distributed among the filiform and conical papillae (figure 2) . the wall of, fungi form papillae and foliate was resemble to threads, while the shape of conical papillae was cylindrical, the fungi form papillae like cone or mashroom- shape which located at apex and dorsal surface of Millivora capensis tongue( Figure3,4).

The circumvallate papillae were circular – shape (figure 4) and embedded in the lingual epithelium these our observations was similar to previous works which done on small and large ruminant (17,18).The our findings about lingual epithelium was appeared on the ventral surface of millivora tongue was non-kerattinized stratified squamous epithelium. While dorsal surface that covered via keratinized stratified squamous epithelium ,which resemble in to the most mammals tongue like ruminant , monkey , dog ,rabbit ,rat and mouse (15, 19 ,20 ,21, 22, 23).The bundle of skeletal muscles fibers was occupied the core of Millivora Capensis tongue( figure2) arranged in all direction , these observation came to correspond the previous study on human tongue (24).The foliate papillae was rudimentary in human tongue , while well developed in the rabbit tongue (21).The circumvallate papillae of Millivora Capensis tongue which surrounded by groove ,these observations was identical to the circumvallate papillae of rodents and ferret (22, 23, 25).

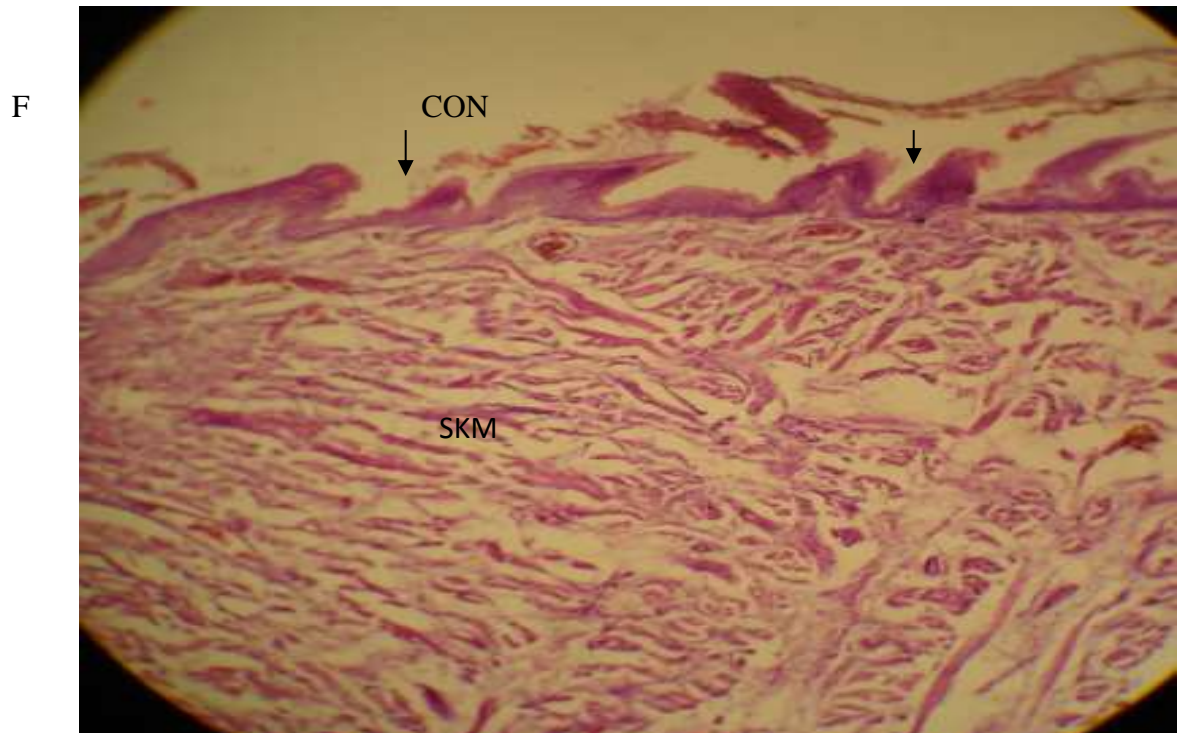


Figure1 :Show the dorsal surface of Millivora capensis tongue ,which composed of mechanical papillae such as filiform papillae (F) ,conical papillae(CON), and the core of the tongue consist of striated muscle fiber (SKM) arranged in all directions. H & E . 250 X.

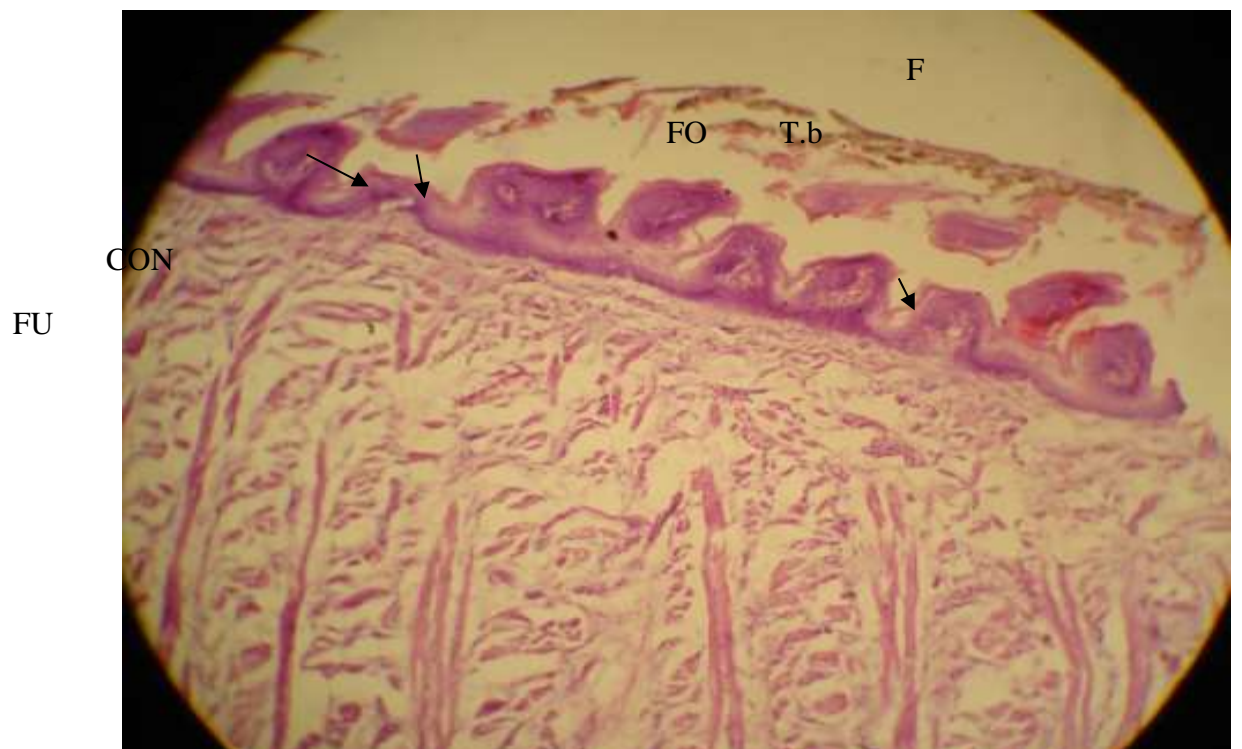


Figure2: The surface of Millivora capenesis tongue, contains both mechanical and gustatory lingual papillae, filliform (F), conical (CON), fungiform papillae (FU), foliate papillae (FO) with taste buds (T.b), and core of the tongue composed of unique pattern of skeletal muscle fibers (SKN), that arranged , vertical , circular , transverse and longitudinal in direction. H&E.250X.

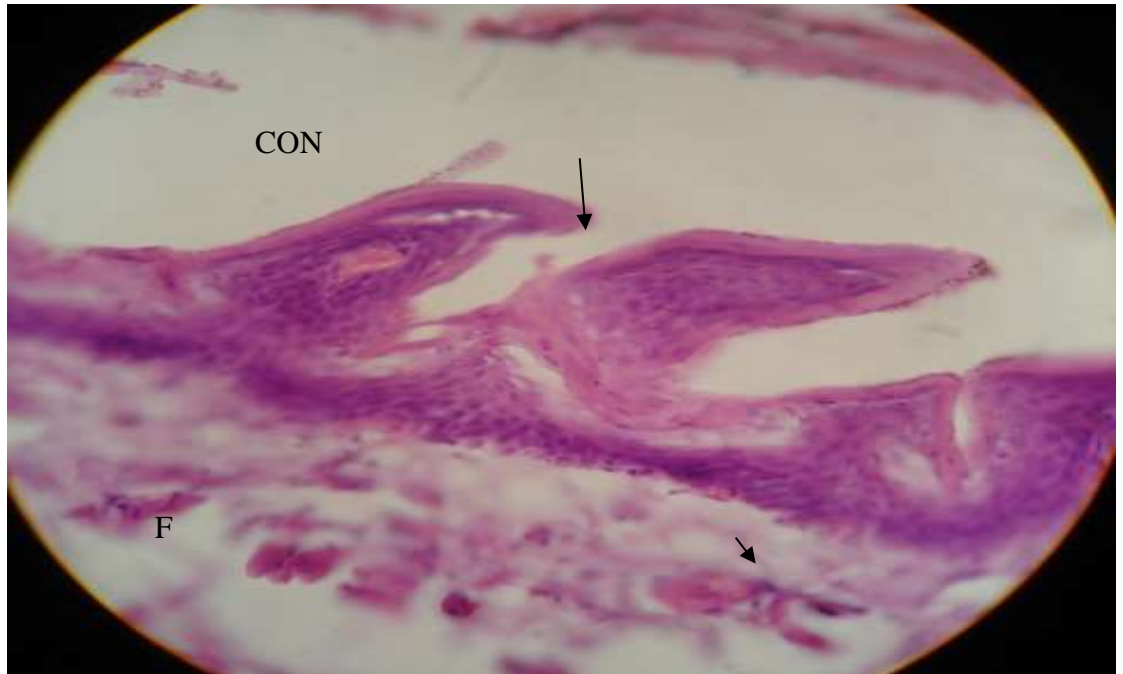


Figure3: Revealed the high power field of dorsal surface of Millivora capenesis tongue with filliform (F) and conical (CON) papillae H&E .

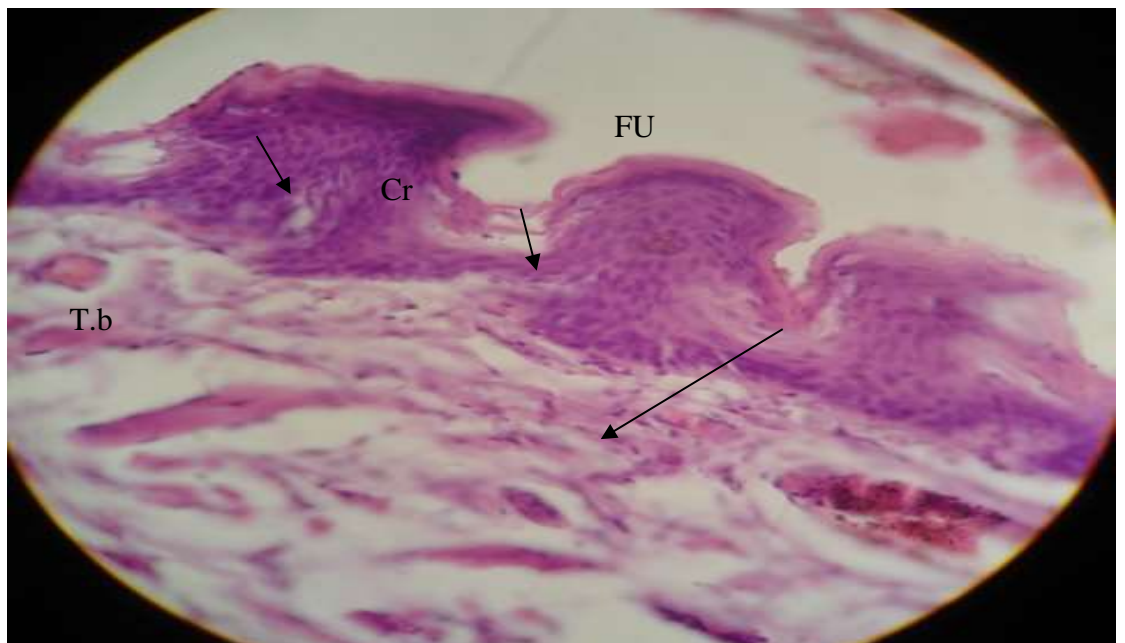


Figure4: Show lingual surface( dorsum) of Millivora capenesis tongue with gustatory papillae, fungiform (FU) and circum vallate (Cir) papillae which contain taste buds (T.b). H&E.450X.

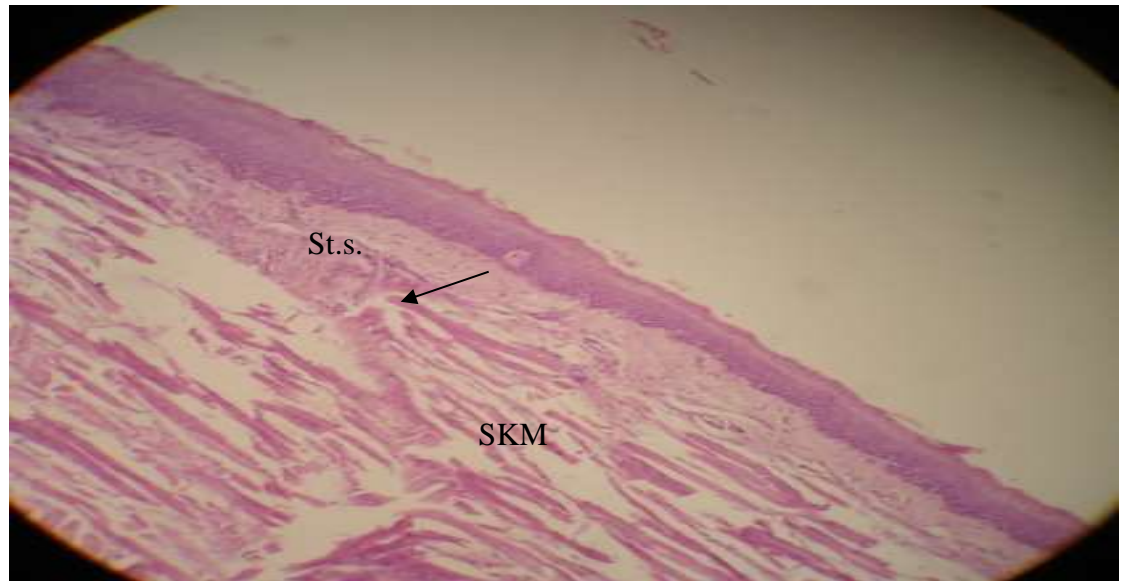


Figure5: Appear the ventral surface of Millivora capenesis tongue which covered with stratified squamous epithelium (non-keratinized) (st. s), the core of tongue consist of skeletal muscle fibers ( SKM) , that arranged in all direction. H&E.250X.

#### Reference

- 1-Dellmann ,H.(2006).text book of Veterinary histology .philadelphia ,lea and febiger.pp:477- 438.
- 2-Fernandez,M.(1988).Comparative scanning electron microscopic study of the lingual papillae in two species of domestic mammals (Equus cabullus and Bos Taurus)
- 3-Scala ,Co. ;vittoria, V. and Cirolamo, p.(1993).Study of morphological structure of lingual papillae in (Bubulus bubulus) .Anat .Hist.Embyol; 22: 264-272.
- 4-Qayyum,M . ;Fatani, A. and Mohajir, M.(1988) .Scanning electron micr- oscopic study of lingual papillae of the one humped camel (Camelus dromedaries).J.Anat. ; 160:21-26.
- 5-Chamorro, c. ;de pas, p. ; Snad val, J. and Fernandez, G.(1986).Comparative scanning electron-microscopic study of the lingual papillae i n two species of domestic Mammals ( Equus Cabullus and Bos Taurus ).1. Gustatory papillae ,Acta.Anat. ;125:83-87.
- 6-Igbokwe, C.and Okeoli, C.(2009).The morphological observation of some lingual papillae in the prenatal and prepuberal stages of red sokoto goat (Capra hircus).Int.J.Morphol .;27:145-150.
- 7-Agungpriyono ,S. ; Yamada ,J. ;Kitamura,N. ;Nisa, C. ;Sigit,K.and yamamoto, Y.(1995).Morphplogy of the dorsal linqual papillae in the lesser mouse deer.J.Anat. ; 187:634-640.
- 8-Begg,K. ;Begg,C.and Abramov,A.(2oo8).Milivora Capenesis.In LUCN (2008). LUCN Red list of threatened speciepp:1.
- 9-Roberts,T. (1977). The mammals of Pakistan, Ernest Benn. Limited- london.UK.
- 10-Smithers, R.(1971).The mammals of Bostswana. The Trustees of the national Museum of Rodesia-Museum. Memoir 4:1-340.

- 11-Gung,H. ; Oropeza,v and The Sleff,I.(1999).Shh,Bmp-2,Bmp-4 and Fgf- B are associated with intiation and patterning of mouse tongue papillae.Mech. Develo. ;81:179-182.
- 12-Heath,J.(1993).Oral tissue .In:Young,B. and Heath,J.(Ed).Wheater s functional Histology .3<sup>rd</sup>.ed.Edinburgh, Churchill Livingstone ,pp:242-244.
- 13-Heran, I.(1971) Some notes on dention in Mustelidae- Vest.Cesko.Spol.Zool. ;35:199-204.
- 14-Vacca,L.(1985).Laborator manual of Histochemistry .1st.ed. Ravan press.New York.pp:139.
- 15-Dellmann,H. and Brown,E.(1976).Text book of Veterinary histology.Lea and Febiger, pheladphia.
- 16-Lida,M.; Yoshioka,I. and Muto,H.(1985).Three dimensional and surfaces structures of rat filiform papillae .Acta.Anat.;121:237-244.
- 17-Qayum,M. and Beg,M.(1975).Anatomical and neurological observation on the tongue of Indian goat .Acta. Acta.Anat.93:554-567.
- 18-Saleem, N.(1978).Morophological and histochemical studies on the tongue of Camel (camelus dromedaries).Msc.thesis. Vet.Med .college. Bagdad University.
- 19-Li-sei,w.;Tetsuo,I.;Masao,H: and Eichi,Y.(1995).Three dimensional organization of epithelium and connective tissue interface of tongue and soft palate in Monkey (Macaca fuscata). Acta Microscopica.; 4:59-73.
- 20-Kobayashi, k.; Miyata,K. and Lino,Y.(1987). Three dimensionl structures of connective tissue papillae of the tongue in new born dogs.Histo.Arch. Jpn.;50:317-357.
- 21-Kobayashi,K.(1992).Stereo-architecture of the interface of the epithelial layer and connective tissue core of foliate papillae in the rabbit tongue .Acta.Anat.; 143:109-117.
- 22-Iwasaki,S.;Yashizawa,H. and Kawahara,I.(2009).Ultrastructural study and relationship between morphogenesis of filiform papillae and the keratinization oflingual epithelium in the rat , J.Anat.;195: 27-38.
- 23- Iwasaki, S. Yashizawa, H. and Kawahara, I.(2006) study by scanning electron microscopy of the morphogenesis of the three types of lingual papillae in the mouse. Acta. Anat.; 157: 41-52.
- 24- Barbara, Y.; James, S.; Alan, S. and John, W.(2006). Wheater's functional Histology, 4<sup>th</sup>.ed. Churchill livingstone. Pp:285
- 25- Mohammed,A.; Salih, K. and Dalal, K.(2009). Some microscopic and morphologic aspects of the lingual papillae in the tongue of ferret( Mustela putrious furo). Scient. Conf. 11. 2009. Pp:130- 138.

بعض الوصف النسيجي للحليمات اللسانية في لسان حيوان الغريزي

توفيق جواد علي شكر

مدرس قسم صحة المجتمع

المعهد التقني- كوفة

الخلاصة

نفذت الدراسة الحالية على ثلاثة السنة لحيوان الغريري نسيجيا. السطح الظهري للسان مغطى بظهارة طباقية حرشفية متقرنة، بينما السطح البطني مغطى بظهارة طباقية حرشفية غير متقرنة. وجدت خمسة انواع من الحليمات اللسانية، والتي شملت الحليمات الميكانيكية والحليمات الذوقية ( الخيطية، الدورقية، الفطرائية، المحوطة والورقية) تتوزع وتبرز الحليمات على السطح الظهري والوحشي للسان. الحليمات الخيطية تشبه الخيوط او الشعرات، بينما تكون الحليمات الدورقية اسطوانية الشكل. الحليمات الفطرائية تشبه المشروم ويحتوي جدارها على براعم ذوقية، ولكن الحليمات المحوطة دائرية ومطمورة في الظهارة. تكون الحليمات الورقية شبيهه بالجسور، وكلتا الحليمات المحوطة والورقية احتوت على البراعم الذوقية.