

The protective effect of probiotics (*Lactobacillus acidophilus* against urinary tract infections caused by *Proteus mirabilis* in vitro

Ali H. Alwan

Dept. of Biology / College of Science / Al-Mustansiriya University

BAGHDAD - IRAQ

Abstract

Experiment studied the protective effect of probiotics bacteria *Lactobacillus acidophilus* against urinary tract infections in laboratory mice caused by *Proteus mirabilis*, by the preparation of heat-killed bacteria *Lactobacillus acidophilus*. 13 animals were divided into three groups, the first group contained five animals not treated, the second group contained five animals treated with the *Lactobacillus acidophilus*, in addition to the control group, which contained two animals. The second group was injected over a five-day by (0.5) ml of stuck cells of heat killed *L. acidophilus* before challenge with 0.2 ml of the *Proteus mirabilis* (10^8 /cells per ml). The results showed that there was no evolution of infection with the *Proteus mirabilis* in the second group of animals, while injury has evolved significantly in the animals of first group non-treated with probiotic bacteria through not observing of the growth of the *Proteus mirabilis* on the culture media for blood and tissue samples taken from animals treated. A differential count of white blood cells results showed, an increase in the number of cells, particularly neutrophils in all the results examined. On the other hand study showed the results of the tissue sections of animals treated and non-treated for histological changes significantly for the untreated animals with the probiotics in compare with animals were simple changes.

Introduction

Proteus species are part of the Enterobacteriaceae family of gram-negative bacilli most commonly found in the human intestinal tract as part of normal human intestinal flora, along with *Escherichia coli* and *Klebsiella* species, of which *E. coli* is the predominant resident. *Proteus* species is also found in multiple environmental habitats, including long-term care facilities and hospitals (Stickler *et al.* 2005).

Pneumonia, Urinary tract infections (UTIs) are the most common bacterial infection seen in clinical practice and in long-term hospital patients ((Stickler *et al.* 2005 ; Kunin, 1994). *Proteus mirabilis* is an important pathogen of the urinary tract, accounts for most of the urinary tract infections that occur in hospital settings (especially in patients with indwelling catheters) and for 90% of *Proteus* infections (Mobley and Warren, 1987; Gonzales, 2006). Urinary tract infection with *Proteus mirabilis* usually start with colonization of the bladder, causing bacteriuria and cystitis (Bahrani, 1991). The infection can ascend rapidly to the kidneys, which in turn may lead to acute pyelonephritis (Smeets and Gower 1987), Chronic inflammation and renal failure (Holmgren *et al.* 1987).

The widespread antibiotics usage exerts a selective pressure that acts as a driving force in the development of antibiotics resistance (Beovi, 2006). *P. mirabilis* infections are becoming more difficult to treat because 48% of *P. mirabilis* strains are resistant to amoxicillin, penicillin, fluoroquinolones and other broad-range activity

antibiotics(Stickler *et al.*2005). A multi-resistant strain becomes a serious global problem, which constrains scientists to search for new effective therapeutic agents. Alternative therapeutic options should use strategies to prevent the selective development of antibiotic resistant bacterial strains , restore a balanced microbial flora and enhance the defence mechanisms of the human body. These criteria are best fulfilled by live microorganisms which are naturally hosted by the human body already (Rayes N. *et al* 2002).

Lactic acid bacteria (LAB) are present in the intestine of most animals , recently LAB have become an attractive option of modern medical practice and the attention has been paid to their health-promoting properties of particular importance are their probiotics properties and specially the ability to compete with pathogens *in vivo* (M. Petrova, *et al.*2009). Although most research concerning probiotic-mediated enhanced immune protection is focused on gastrointestinal tract pathogens, a few recent studies tested whether probiotics might sufficiently stimulate the common mucosal immune system to provide protection to other mucosal sites as well (Cross, M. 2002). The fact that certain lactic acid bacteria activate and modulate the immune system (Kato I. *et al.* 1983 ; Kato I. *et al.* 1984) opens a promising perspective concerning the use of such microorganisms as immune modulators (Erickson KL, and Hubbard NE. 2000). When these microorganisms are ingested, the gut-associated immune system (GALT) is particularly involved in activating and modulating the immune system (Matsuzaki T, and Chin J. 2000 ; Villena *et al.* 2006). The search for effects of immune system modulation in other parts of the MALT presents an interesting challenge.

The aim of this work was to study the effect of the probiotics *L.acidophilus* on the resistance to *Proteus mirabilis* infection in mice .

Materials and methods

Animals

13mice (Male 6 weeks-old Swiss blab\c) divided into 3 groups consisting of 5 mice, in addition to control group consisting of 2 mice.

Bacterial isolates

1- *Lactobacillus acidophilus*: (LBA) cultured on De man Rogsa sharp medium (MRS) at 37C for 48hrs.Washed with distilled water , killed at 100c for 30 min, and suspended in phosphate buffer saline (PBS) at desired concentration just before use(Takashi A. *et al.*200) .

2- *Proteus mirabilis* :isolated from chronic urinary tract infection patients. *Proteus mirabilis* first grown on blood agar for 18 hrs; freshly grown colonies were suspended in brain hart infusion broth and incubated at 37 C overnight. The pathogens harvested through centrifugation at 3000 rpm for 10 min and then washed 3 times with sterile PBS. The infecting dose was chosen according to Takashi (Takashi A. *et al.*2001).

Experimental infection

Five days before challenge with *Proteus mirabilis*, 0.5 ml of heat –killed LBA was injected intraperitoneally (IP) (Miake S. *et al.*1985). After sterilization of the

periurethral area with 70% ethanol, a sterile 24-gauge Teflon catheter (yellow color I.V Cannula: outer diameter, 0.7 mm; length, 19 mm) inserted into the bladder through the urethra. Before inoculation of bacteria, the bladder mucosa are traumatized by infusing 100 µl of 0.1 N HCl solution for 45 s, followed by neutralization with 100 µl of 0.1 N KOH and flushing with sterile saline). A 20-µl inoculum's containing 1×10^6 to 2×10^6 organisms was infused into the bladder through a catheter over 30 sec. Through a microsyringe. Mice are killed on day 0 (before infection) and on day 2, 5, 10, post infection (Chin, J. L. *et al.* 1996).

Determination of bacterial growth in kidney ,spleen ,and liver homogenates and blood:

The challenge of *Proteus mirabilis* was to positive control mice and mice that had been treated with Lactic acid bacteria(LBA). After challenge, mice were killed by cervical dislocation; kidney ,spleen and liver were excised to determine the bacterial growth by homogenization in sterile normal saline and plated on blood agar. Bacteraemia was monitored by sampling the blood via cardiac puncture by a heparinized syringe and cultured on blood agar. Result was reported after 18h and 37C incubation period as negative or positive haemocultured.

Determination of total and differential numbers of leukocytes in the blood:

The total numbers of leukocytes was determined with haemocytometer and differential cell count was performed by counting 200 cells in blood smears with giemsa stain (Bergeron, Y. *et al.*1998).Inflammatory responses in urin: After infection with *Proteus mirabilis*, urine was collected from individual anesthetized mice. The number of leukocytes in urine was examined microscopically using a hemocytometer (Bergeron, Y. *et al.*1998). For morphologic analysis, fresh urine samples were centrifuged once at $1,000 \times g$, and the pellet was resuspended in Hanks' balanced salt solution supplemented with 10% FBS at a concentration of 10^5 cells/ml. The cells were spun onto glass slides in a Cytospin 11 centrifuge at $100 \times g$ for 5 min. The slides were air dried, stained with Giemsa stain (Sigma), and then inspected by light microscopy.

Histology: Kidney ,spleen, and liver samples from the control, treated, and untreated mice were excised and washed with phosphate buffer saline (PBS).Tissues were immersed in formalin saline solution ,once fixed ,samples were dehydrated and embedded in paraffin wax at 56c .Finally were cut and into sections and stained with haematoxililn –eosinfor light microscopy examination (Villena *et al.* 2006).

Results and Discussion

Probiotics are considered as live administrated that promote health of the host including prevention or treatment against infections , lactose in tolerance cases , decrease of blood cholesterol and immunity modulation (Villena, J *et al.* 2005).

The protective effect of heat –killed *Lactobacillus acidophilus* against *Proteus mirabilis* infection in swiss mice with age of 6 weeks was study .Heat-killed *L.acidophilus* was injected intraperitonally 7 days before challenge with vital *P. mirabilis* .

Survival of mice after intraperitoneally infection with *P.mirabilis* was augmented in mice that had been pretreated with *L.acidophilus* 7 days earlier .Mice become resistant to infection with *P.mirabilis* after pretreated with *L.acidophilus* .

The results of the bacterial culture of the blood and tissues homogenates samples showed no growth only in one sample of blood culture .

Differential cell count of peritoneal leukocytes were studied consecutively after treatment with *L.acidophilus* , polymorphonuclear cells (especially neutrophils) were characteristically increased in *L.acidophilus* treated mice in compare with untreated and control mice (Fig.1).The results of inflammatory response in the urine showed inflammatory stimulation ,the number of leukocytes in the urine in the treated mice in compare with untreated and control mice .These findings are in several studies investigated the role of immune modulating probiotics in the control of microbial enterpathogens using rodent infection –challenge models (Hentges, D. J.1992) .*Lactobacillus acidophilus* exhibits resistance to gastric acid , bile and pancreatin. It protects the intestinal environment of human and contains more than 20 know peptidase (Vahjin, W. *et al* .2007) .

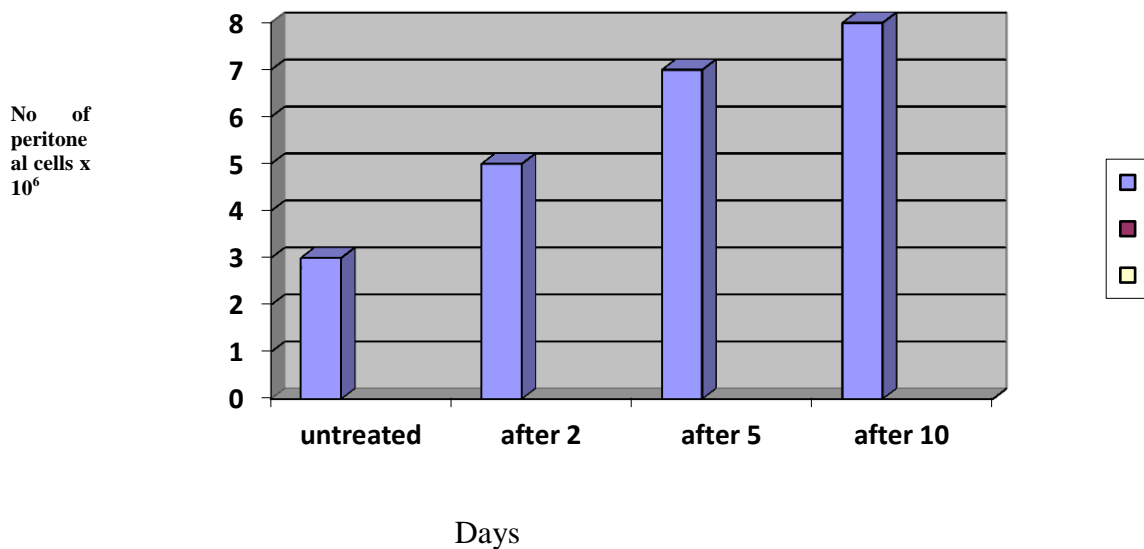


Fig 1. . Number of peritoneal Leukocytes in mice treated with *Lb. acidophilus*

Villena *et al*(Villena, J. *et al* . 2005) showed that the administration of yoghurt to young mice enhance the phagocytic activity of alveolar macrophage .

Lactobacillus casie was reported to induce both secretory immune response and to protect against enteric infections in well-nourished and malnourished mice (Gauffin Cano,p.; and Perdigon,G. 2003) .

Adminstration of *L.casie* protect the respiratory mucosa against pathogen and enhances the phagocytic activity of macrophages (Alvarez, S. *et al* .2003) .

There is evident to suggest that the probiotics increasing or improving the phagocytosis as well as increasing the protection of T-lymphocytes and natural killer cells, an observation thought to be in part due to the regulation of cytokine function(Reid G. *et al*.2003) .

Others investigators showed that the lactobacillus protects the vagina from colonization of uropathogens by competition for the adhesion receptors , competition for nutrients , and production of antimicrobial substances (H₂O₂,lactic acid, bactericins , and bacteriocin –like substances) (Pelletier,*etal.*1997). Other studies showed that *Lactobacillus salivarius* inhibit the growth of *Helicobacter pylori* in invitro by mechanism involving lactic acid secretion (Ryan, K.A.*etal.*2008) . However production of bacteriocin was identified as the mechanism whereby *L. salivarius* eliminated *Listeria monocytogenes* in a murine model , providing the first definitive mechanism for anti-infective activity of probiotic bacterium in invivo (Corr,S.C.*etal.*2007) . Histopathological changes of the sectioned tissues (kidney , liver , spleen) showed that the changes in the treated mice were simple sings in compare with untreated and control mice . histological examination of the kidney from treated mice showed that the kidney look like normal appearance of the histological structure of the glomeruli and renal tubules (Fig. 2,3) in compare with normal tissue of the control group mice (Fig.4).

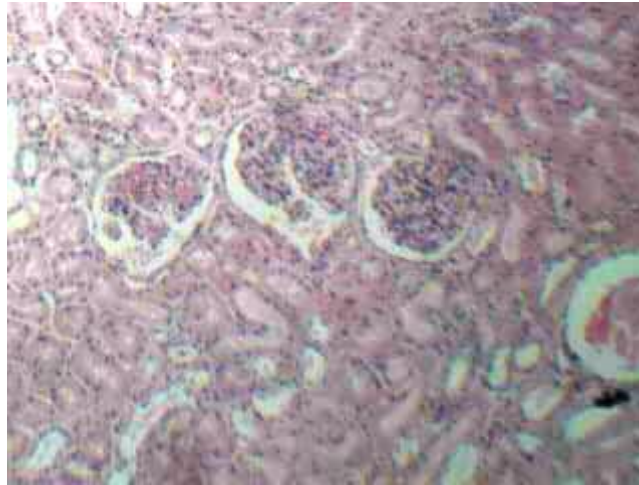


Fig.2. Kidney of treated mice (5 day after infection)

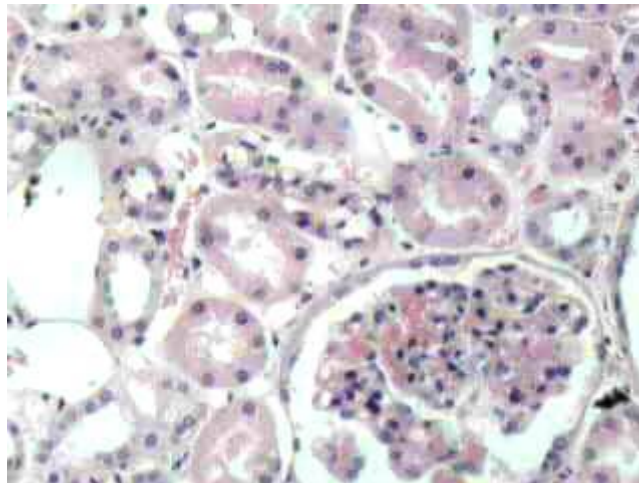


Fig.3. Kidney of treated mice (10 day after infection)

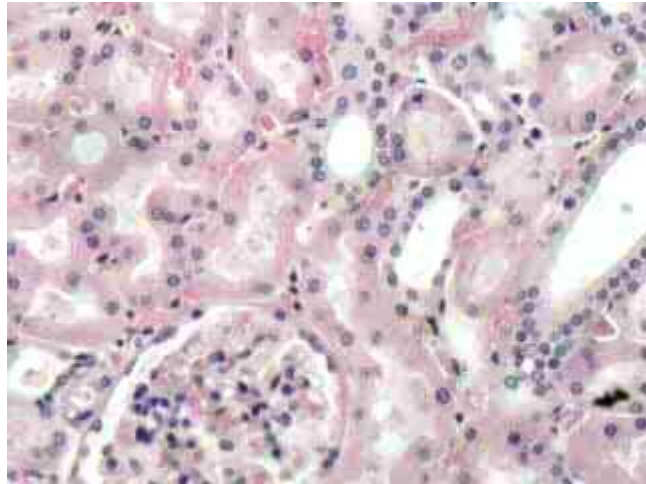


Fig.4.Kidney of normal mice (control)

While the changes in the untreated mice kidney showed degenerative changes of the epithelial lining of the renal tubules (Fig. 5,6) .

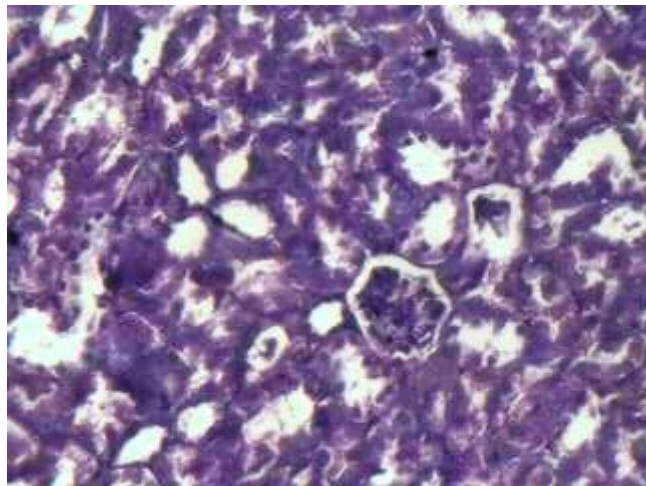


Fig.5. Kidney of untreated mice (2 day after infection)

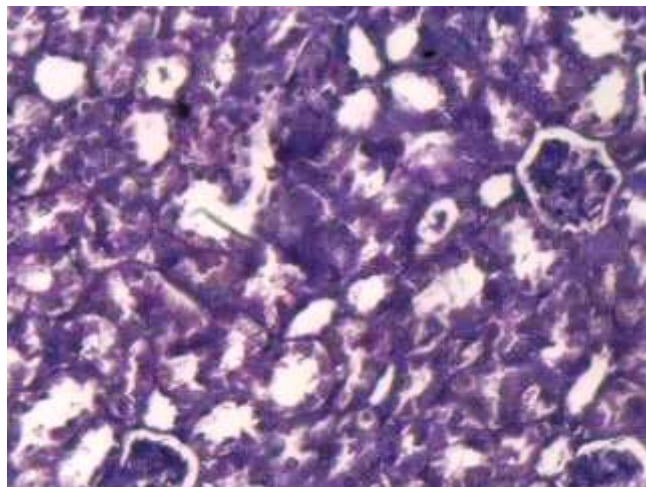


Fig.6. Kidney of untreated mice (5 day after infection)

On the other hand the changes in the spleen of the treated mice showed normal appearance in the white and red pulp (Fig. 7,8) which are the same structure in the control mice (Fig. 9) .

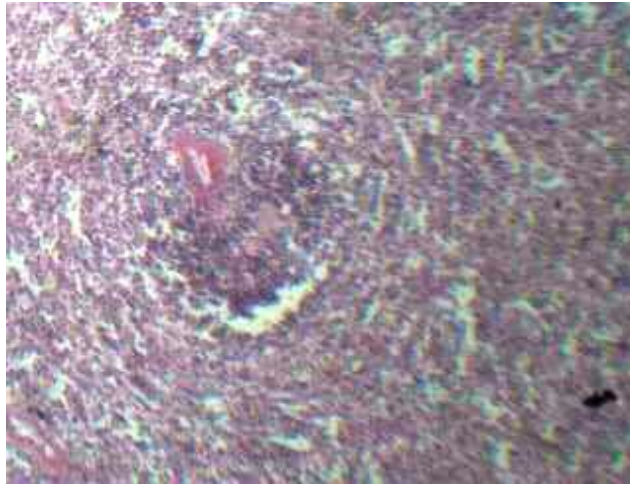


Fig.7. Spleen of treated mice (5 day after infection)

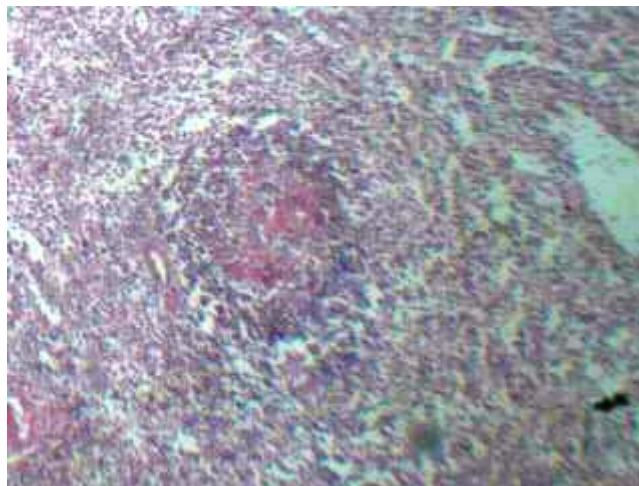


Fig.8. Spleen of treated mice (10 day after infection)

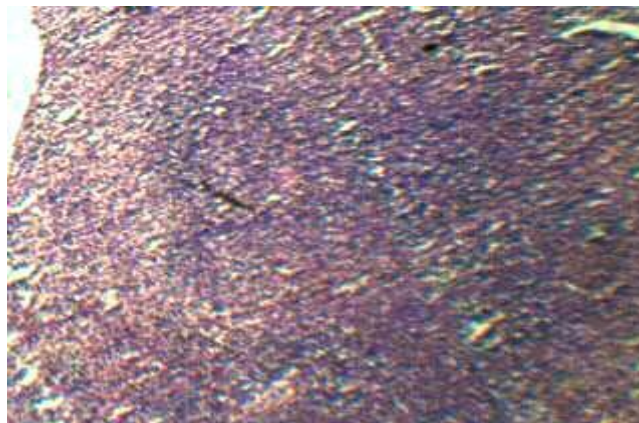


Fig.9. Spleen of normal mice (control)

The spleen of the untreated mice characterizing by the follicular hyperplasia with widding of the white pulp (Fig. 10,11).

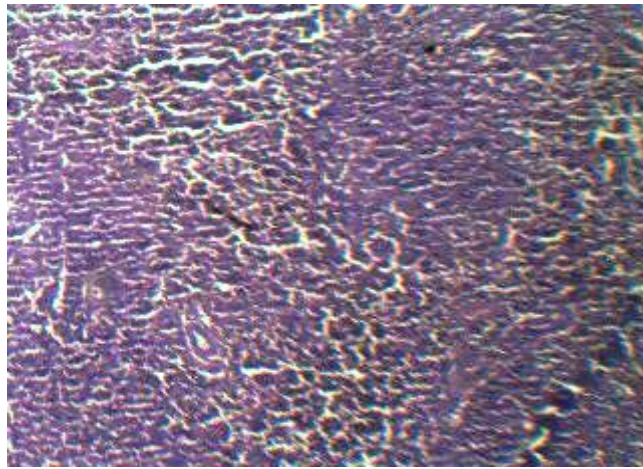


Fig.10. Spleen of untreated mice (2 day after infection)

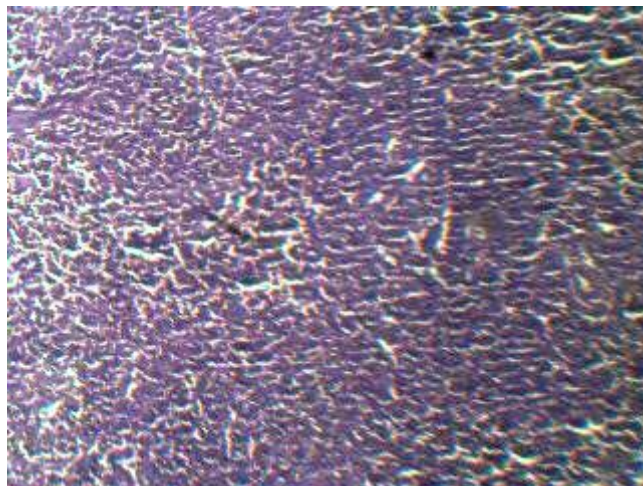


Fig.11 Spleen of treated mice (5 day after infection)

The results of the liver histological changes showed that the changes were simple in the treated and control mice(fig. 14) in compare with untreated mice ,which showed that there is marked degeneration and necrosis of the hepatocytes ,especially around central vein , with mild inflammatory cells infiltration(Fig. 12,13) .

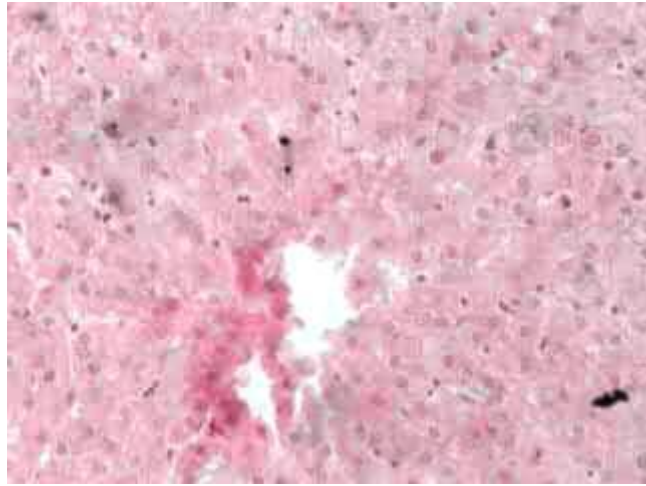


Fig.12.Liver of treated mice (5 day after infection)

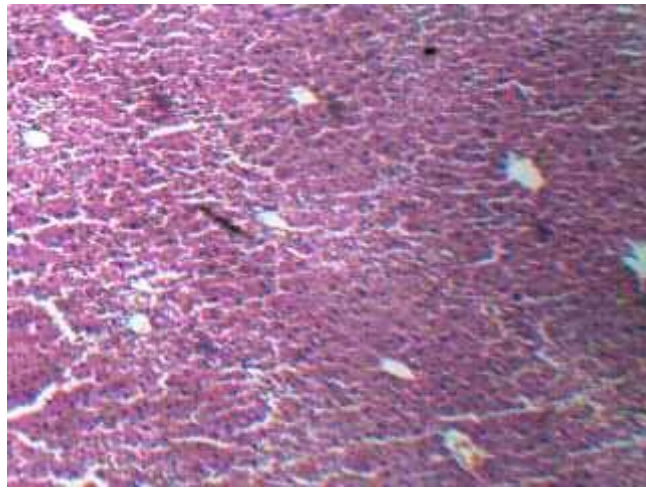


Fig.13.Liver of untreated mice (2 day after infection)

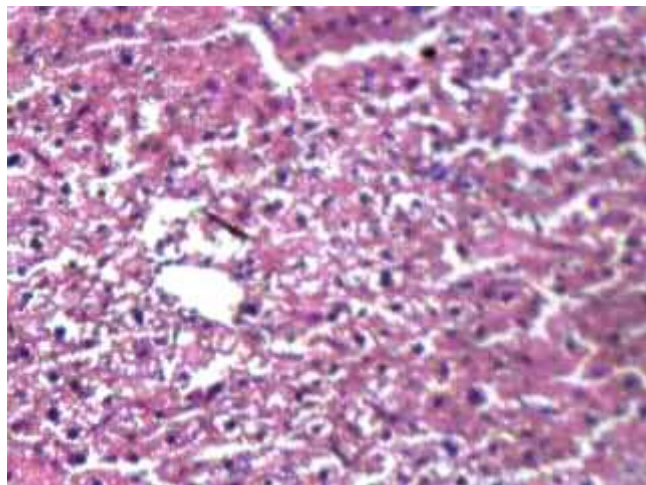


Fig.14.Liver of treated mice (5 day after infection)

The histopathological findings were less pronounced in the treated mice , referred to less susceptibility to infection by improving the immune status .

Lactobacilli can directly promote the gut mucosal barrier by the stimulation of the immune system(perdigon *et al.* 1998)

Some authors have reported that the immune system stimulation exerted by the LAB used in yoghurt production would allow the maintenance of an improved resistant against pathogens (Erickson KL and Hubbard NE.2000).

References

Allen SJ, Okoko B, Martinez E, Gregorio G, and Dans LF.(2001) . Probiotics for treating infectious diarrhea

Alvarez, S.; Herrero,C.; Bru,E. and Perdigon,G. “Effect of *Lactobacillus casei* and yogurt administration on prevention of *Pseudomonas aeruginosa* infection in young mice " *J.Food.Prot.* Vol. 64, No.11 , pp. 1768-74 .

Bacteriocin production as a mechanism for antiinfective activity of *Lactobacillus salivarius* , Proceedings of the National Academy of Science of the united states of America , vol.104 , no. 18,pp. 7617-7621, 2007 .

Bahrani FK, Johanson DE, Robbins D, and Mobley HLT(1991). *Proteus mirabilis flagella and MR/P fimbria ; isolation, purification .N-terminal analysis, and serum antibody response following experimental urinary tract infection. Infect. Immun.* 59:3574-3580.

Beovi , B. (2006). The issue of antimicrobial resistance in human medicine. *Intern. J. of Food Microbiology*, 112:280–287.

Bergeron, Y., Oullet, N., Deslauriers, A., Simard, M., Olivier, M. & Bergeron, M. G. (1998) Cytokine kinetics and other host factors in response to pneumococcal pulmonary infection in mice. *Infect. Immun.* 66:912-922.

Chin, J. L., S. A. Kadhim, E. Batislam, S. J. Karlik, B. M. Garcia, J. C. Nickel, and A. Morales (1996). Mycobacterium cell wall: an alternative to intravesical bacillus Calmette-Guérin (BCG) therapy in orthotopic murine bladder cancer. *J. Urol.* 156:1189-1193,.

Corr,S.C.;Li,Y.;l, Riedel,C.U.; Otoole,P.W.;Hill, C.and Gahan,C.G.M

Cross, M. (2002) Microbes versus microbes: immune signals generated by probiotic lactobacilli and their role in protection against microbial pathogens. *FEMS Immunol. M. Microbiol.* 34:245-253. 10.

D'Souza AL, Rajkumar C, Cooke J, and Bulpitt CJ.(2002). Probiotics in prevention of antibiotic associated diarrhoea: Meta-analysis. *BMJ.* 32435:1361.

Erickson KL and Hubbard NE(2000). Probiotic immunomodulation in health and disease . *J Nutr*130, 403s-409s .

Erickson KL, and Hubbard NE. (2000). Probiotic immunomodulation in health and disease. *J Nutr*;130(suppl):403S–9S.

Gauffin Cano,p.; and Perdigon,G(2003). Probiotics induce resistance to enteropathogens in a renourished mouse model . *J. Dairy Res.*70:433-440 .

Gonzales, Gus (2006). Proteus Infections. eMedicine from WebMD. Last edited 2 March. Accessed Nov. 30, 2008.

Hentges, D. J. (1992) Gut flora and disease resistance. Fuller, R. eds. Probiotics: The Scientific Basis 1992:87-110 Chapman and Hall London, UK. . 6

Holmgren K, Danielson BG, and fellstromB(1987). Infection-induced urinary calculi and renal failure . scand. J. urol. Nephrol.; 21: 291- 223.

Kato I, Yokokura T, and Mutai M(1983). Macrophage activation by *Lactobacillus casei* in mice. Microbiol Immunol;27:611–8.

Kato I, Yokokura T, and Mutai M(1984). Augmentation of mouse natural killer cell activity by *Lactobacillus casei* and its surface antigens. Microbiol Immunol;28:209–17.

Kunin, C. M. 1994. Urinary tract infections in females. Clin. Infect Dis. 18:1-12.

Lata J, Jurankova J, Pribramska V, Fric P, Senkyrik M, Dite P, *et al*(2006) . Effect of administration of *Escherichia coli* Nissle (Mutaflor) on intestinal colonisation, endotoxemia, liver function and minimal hepatic encephalopathy in patients with liver cirrhosis. *Vnitr Lek.*52:215–9.

M. Petrova, et al(2009). Lactic acid bacteria against pathogenic microbes. Trakia J. of Sciences, Vol. 7, No. 2, pp 33-39,

Matsuzaki T, and Chin J. Modulating immune responses with probiotic bacteria. Immunol . Cell Biol 2000;78:67–73.

Miake, S., K. Nomoto, T. Yokokura, Y. Yoshikai, M. Mutai, and K. Nomoto. (1985). Protective effect of *Lactobacillus casei* on *Pseudomonas aeruginosa* infection in mice. Infect. Immun. 48:480-485.

Mobley HLT , and Warren JW(1987). Urease-positive bacteriuria and obstruction of long-term urinary catheters. J. Clin. Microbial ;25;2216-2217.

Pelletier,C.;Bouley,C.;Cayuela,C.;Bouttier,S.;Bourlioux, P.;and Bellon-FontaineMN(1997).Cell surface characteristics of *Lactobacillus casei subbsp ,casei,Lactobacillus paracasei subsp.paracasei ,and Lactobacillus rahmnosus* strains .Appl Environ Microbiol.63:1725-31 .

Perdigon G, Vintini E, Alvarez S , Medina M and Medici M. Study of possible mechanisms involved in the mucosal immune system activation by lactic acid bacteria . J Dairy Sci 82, 1108-1114 , 1998.

Rayes N, Seehofer D, Muller AR, Hansen S, Bengmark S, and Neuhaus P(2002). Influence of probiotics and fibre on the incidence of bacterial infections following major abdominal surgery. *Z Gastroenterol.* 40:869–76.

Reid G, Jass J, Sebulsky MT, and McCormick JK (October 2003). "Potential uses of probiotics in clinical practice. *Clin. Microbiol. Rev.* 16 (4): 658–72.

Ryan, K.A.;Daly,P.; Li,Y.; Hooton,C. and OToole,P.W(1987). Strain-specific of *helicobacter pylori* by *Lactobacillus salivarius* and other lactobacillus , Journal of antimicrobial Chemotherapy ,vol.61,no.4,pp.831-834. 2008 .

Smeets F, and Gower PE(1973). The site of infection in 133 patients with bacteriuria .Clin. nephrol. 1;290-296.

Stickler, D.J, et al(2005). Observations on the adherence of *Proteus mirabilis* onto polymer surfaces. J. of Appl. Microbiol.. Accepted 24 October. pp. 1028–1033.

Takashi A. et al(June 2001). Antimicrobial Activity of Intraurethrally Administered Probiotic *Lactobacillus casei* in a Murine Model of *Escherichia coli* Urinary Tract Infection Antimicrobial Agents and Chemotherapy .p. 1751-1760, Vol. 45, No. 6.

Vahjin, W.; Taras , D.; and Simson, O(2007).Effect of the probiotic *Enterococcus faecium* on cell membrane of total *Enterococcus spp.*, *E. faecium* and *E. faecalis* In the intestine of the piglet,” Current Issues in Intestinal Microbiology , vol.8,no.1,pp. 1-8.

Vesterlund,S. ; Karp,M.; Salminen, S. and Arthur, C(2006). “ *Staphylococcus aureus* adheres to human intestinal mucus but can be displaced by certain lactic acid bacteria" *Microbiology* , Vol.152 , pp. 1819-1826 .

Villena, J. ; Racedo, S.;Aguero , G. ;Bru , E.; Medina , M. and Alvarez , S.(2005) “ *Lactobacillus casei* Improves Resistance to Pneumococcal Respiratory Infection in Malnourished Mice" , *J. Nutr.* Vol. 135 , pp. 1462-1469.

Villena, Julio , Racedo, Silvia Aguero, Graciela Alvarez, and Susana(March 2006) .Yoghurt accelerates the recovery of defence mechanisms against *Streptococcus pneumonia* in protein-malnourished mice. *British Journal of Nutrition.* 95(3):591-602

التأثيرات الوقائية الناتجة من استخدام المعزز الحيوي

Proteus mirabilis ضد التهابات المجاري البولية المتسببة عن بكتريا Lactobacillus acidophilus
داخل الجسم الحي

د. علي حسين علوان

مدرس/ قسم علوم الحياة / كلية العلوم / الجامعة المستنصرية / بغداد/ العراق

الخلاصة

تم دراسة التأثير الوقائي لبكتريا المعزز الحيوي *Lactobacillus acidophilus* ضد اصابات الجهاز البولي في الفئران المختبرية المتسببة عن بكتريا *Proteus mirabilis* ، وذلك بتحضير عالق البكتريا المقتولة بالحرارة لبكتريا المعزز الحيوي *Lactobacillus acidophilus* .

تضمنت الدراسة استخدام 13 حيوان مختبري ، ضمت المجموعة الاولى خمس حيوانات غير معاملة ، المجموعة الثانية احتوت خمس حيوانات عوملت ببكتريا المعزز الحيوي *Lactobacillus acidophilus* ، اضافة الى مجموعة السيطرة التي ضمت حيوانان . حققت المجموعة الثانية على مدى خمسة ايام ب (0.5) مل من عالق الخلايا المقتولة بالحرارة لبكتريا *L.acidophilus* قبل اصابتها ب 0.2 مل من بكتريا *Proteus mirabilis* (10^8 / خلية لكل مل) .

اظهرت النتائج عدم تطور الاصابة ببكتريا *Proteus mirabilis* عند حيوانات المجموعة الثانية ، فيما تطورت الاصابة بشكل ملحوظ في حيوانات المجموعة الاولى غير المعاملة بعالق بكتريا المعزز الحيوي من خلال عدم ملاحظة نمو لبكتريا *Proteus mirabilis* على الاوساط الزرعية لنماذج الدم والانسجة المأخوذة من الحيوانات المعاملة .

اظهرت نتائج العد التفريقي لخلايا الدم البيضاء حدوث زيادة في عدد الخلايا وبشكل خاص الخلايا العدلة *Neutrophils* في جميع النتائج التي فحصت . من جانب اخر اظهرت نتائج دراسة المقاطع النسيجية للحيوانات المعاملة وغير المعاملة حصول تغيرات نسيجية ملحوظة بالنسبة للحيوانات غير المعاملة بعالق بكتريا المعزز الحيوي مقارنة بالحيوانات المعاملة والتي كانت تغيرات بسيطة .