

Histological study of the effect of Thyroxin and Aqueous extract of Karkade on liver in Swiss male mice

د. عدنان وحيد محمد. استاذ مساعد ... كلية الطب / جامعة القادسية

نادية فاضل سلمان. بايولوجية اختصاص...معهد الطب العدلي / بغداد

ميسون عبد الامير احمد . مدرس مساعد.. كلية الطب / جامعة النهرين

Abstract:

The plant Karkade (*Hibiscus sabdariffa* L.) has been, for many years used in different countries around the world as a culinary and therapeutic resource, it has been used as antihypertensive, anti-hypercholesterolemia and as diuretic. This study aimed to determine the effect of thyroxin and the aqueous extract of Karkade alone and together on the histological and cytological structure of the liver and the inhibitory effect of the aqueous extract of Karkade on hyperthyroidism.

Forty Swiss albino mice were used in this study; animals were divided into four equal experimental groups. The experimental groups included: control group, animals treated with thyroxin, animals treated with aqueous extract of Karkade and animals treated with thyroxin and with the aqueous extract of Karkade together.

Results showed that the injection of thyroxin has negative effects on the liver, and that the active compounds of aqueous extract of Karkade have an important role in the inhibition of the negative effects of thyroxin

Key words: thyroxin, *Hibiscus sabdariffa*, karkade, liver, inhibition.

Introduction

The plant species *Hibiscus sabdariffa* (karkade) has been, for many years, used in different countries around the world as a culinary and therapeutic resource. It has been utilized for preparing candies, jelly, and hot or cold beverages. According to different ethnobotanical studies, some traditional medicines use the aqueous extract of this plant as diuretic, for treating gastrointestinal disorders, liver disorders and hypercholesterolemia, and as diaphoretic, and antihypertensive. And it is used as antiobesity drink.[Gruenwald, J.; Brendler ,Herra-Arllano,A;Romer, Kim,J;So, H;Youn,M;Kim,H, Lin,H.;Chen, J.;Kuo,]

Chemical studies have shown the presence, in dry calyx of this plant, of aluminum, chromium, copper, iron [Moussa, Tarek Nasser], and it contains a large amount of riboflavin and ascorbic acid as well as hibiscus acid ,tartaric acid, malic acid and citric acid, different anthocyanins as delphinidin-3-glucoside, delphinidin-3-xyloglucoside ,delphinidin-3-sambubioside ,cyaniding-3-xyloglucoside and flavonoids as hibiscitine ,gossypin , gossypin-3-glucoside and sabdaretine [- Gruenwald, J.; Brendler, T. and Jaenicke, C, - Khalaf Allah, Abdul Aziz Mohammed, Qi, Y.; Chin, K.; Malekian, F.; Berhane, M. and Gager, J] .Also there are water-soluble polysaccharides [9],and it contains the phenolic compound protocatechuic acid (PCA)[10],Characteristic red color elicited by the decoction of this plant is produced the anthocyanins [Wang, J. and Lenardo, M.].

The liver is a vital organ in the human body. It has a wide range of functions, including detoxification, protein synthesis, and production of biochemical necessary for digestion. The liver is necessary for survival; there is currently no way to compensate for the absence of liver function. This organ plays a major role in metabolism and has a number of functions in the body, including glycogen storage, decomposition of red blood cells, plasma protein synthesis, hormone production, and detoxification. [Maton, A.; Hopkins, J. McLaughlin, C.; Johnson, S.].

Materials and methods

1- Thyroxin solution :

It was prepared by dissolving one tablet of thyroxin containing 50 µg in 1 milliliter of distilled water [Tomanek, R.; Doty, M. and Sandra, A.].

2- Extraction of plant material :

In this study, the use of crude aqueous extract was in order to provide a scientific method that can be applied easily and without cost, without the need to a complex method of extraction. 50 grams of powdered dried karkade plant was added to 250 milliliters of distilled water, and put in boiling water bath for two hours and then it was filtered and left to cool. The size of the resulting extract was measured and it was saved in dark plastic container at temperature 4 ° c for use in subsequent testing [Dafallah, A. and Al- Mustafa, Z.].

3- Experimental animals:

40 Swiss male mice *Mus musculus* were involved in this study with one month age, they were divided into 4 subgroups (10 animals each). Each group was placed into a clean cage and provided with food and water *ad libitum*. Animals weight was measured before experiments, treatment was as the following:

G1: Control group: This was treated with oral administration of normal saline (0.5 ml) for 20 days between one day and another.

G2: Animals were treated with thyroxin (subcutaneous administration) with 0.2 mg/ kg for 20 days between one day and another.

G3: animals were treated with oral administration of the aqueous extract of Karkade (0.5ml) with concentration 50 g/ 250 ml for 20 days between one day and another.

G4: Animals were treated with thyroxin and with the aqueous extract of Karkade for 20 days between one day and another. At the end of experiments animals were weighted and scarified.

3- Histological tissue sections preparation: histological sections were prepared and stain with hematoxyline and eosin stain according to Bancroft and Stevens (1982)[Bancroft, J.; and Stevens, A.].

Results:

Weight changes: there was a significant changes in the mean of animal body weights comparing with the increment in the mean of body weights control group which increased from (11.1 ± 0.33) gm at the beginning of the experiment to (20± 0.27)gm at

the end of experiment, while the increase of the mean of body weight for the animals treated with thyroxin was significantly ($P < 0.05$) less than control group as it was (10.3 ± 0.62) gm at the beginning and then became (17 ± 0.27) gm at the end of experiment. For the animals treated with aqueous extract of Karkade there was no significant difference in the increment of the body weight mean comparing with control group as it was (10.1 ± 0.4) then became (21 ± 0.63) gm. While there was a significant decrease ($P < 0.05$) in the mean of animal weights treated with thyroxin and the aqueous extract of Karkade comparing with control group as it was (10.8 ± 0.37 gm) then became (13 ± 0.65) gm at the end of the experiment.

Histological changes:

Histological examination revealed a morphologically normal liver in the control group (fig. 1). In thyroxin treated group there was necrosis, hemorrhage, vacuolation and inflammation (fig. 2). While in Karkade treated group there was few histological changes included increased mitotic division, increase in Kupffer cells with normal looking tissue (fig.3).

While in the animal group treated with thyroxin and aqueous extract of Karkade together there was an inhibitory effect for aqueous extracts of karkade against the thyroxin effect, as the results showed a normal tissue like in the control group in most areas with less hemorrhage, vacuolation and inflammation (fig. 4).

Discussion:

The results of statistical analysis for this study showed a significant reduction ($P < 0.05$) in the average of weights for the animals treated with thyroxin at the end of the experiment in comparison with control group, and the reason for this decline is due to the increase in the thyroxin which lead to more rapid metabolism and increased destruction of protein and increase consumption of fats which leads to lower body weight [Gighton and Hall.]. This result supports the findings of Al- Shaibi (2004)[Shaibi, Abeer Osman.] and Al- Hiyali (2006)] that the injection of thyroxin leads to a reduction in weight of animals treated with it.

In the group of animals treated with the aqueous extract of Karkade there was no significant differences ($P > 0.05$) in the rate of weights of animals at the end of the experiment against a range of control, and this is contrary to what is known about the effectiveness of the Karkade in weight Loss and solving fat [Kim, J.; So, H.; Youn, M.; Kim], this might be due to insufficient concentration used or the fact that the treatment was one day to another , as it was indicated that the treatment of mice with the concentration 120 g / 250 ml of aqueous extract of Karkade for 60 consecutive days lead to a significant decrease in weight [Alarcon-Aguilar, F.; Zamipla,].

In the group of animals treated with thyroxin and aqueous extract of Karkade together when measuring average weights of animals for this group with the average weights of animals of the control group and the group treated with thyroxin only and group treatment with the aqueous extract of Karkade only, it has been found a significant reduction ($P < 0.05$) in the weight average, and we can say that this decline is due to the is a synergistic effect of thyroxin and aqueous extract of Karkade in reducing weight, as the thyroid hormones works on further analysis of fat in adipose tissue [Riis, A.; Hansen, T.; Møller], and that the aqueous extract of Karkade has very effective known role to reduce the weight [Alarcon-Aguilar, F.; Zamipla],

which is due to contain vitamin C, which refer to its role in weight loss [Johnston, C. S.], as well as the ability to solve fat [- Kim, J.; So, H.; Youn,].

The microscopic examination of the histological sections of the liver of the animal treated with thyroxin showed an observed vacuolation, hemorrhage, degeneration of the majority of epithelial cell. It was also noted an increase in the number of blood vessels and infiltration of inflammatory cells, which refers to an inflammatory response resulting from the release of lysosomal enzymes and the secretions of degenerative cells, which led to the attraction and migration of these cells into the tissue, which is considered a means of defense in vivo [Steller, H.].

The results of histological examination showed an increase in the number of Kupffer cells as a result to the treatment with the aqueous extract of Karkade and that might be due to decreasing oxidative stress and reducing cell death [Liu, C.; Wang, J.; Lee, C]. Also there was an increase in mitotic division of the hepatocytes and we can say - The ability of the extract to increase the cell division might be because it contains anthocyanins which refer to its role in supporting the immune response by stimulating the production dynamics cellular anti-inflammatory [Liu, C.; Wang, J.; Lee, C], also it contains flavonoids and polysaccharide where it was indicated that these compounds give extract ability of anti-inflammation and bacterial infections [Muller, B. and Franz, G.].

In the group of animals treated with thyroxin and aqueous extract of Karkade together, it was observed the ability of the extract on inhibition of the negative impact of the thyroxin, as it has been noted cellular repair less vacuolation and hemorrhage.

We can say - that the act of aqueous extract of Karkade in stimulating cellular repair due to it contains anthocyanins and flavonoids, which has effective antioxidant and protect the body from free radicals and stimulate the inflammatory response .

References

- Gruenwald, J.; Brendler, T.** and Jaenicke, C. (1998). PDR for Herbal Medicines. 1sted. Economics company, Inc. New Jersey, p: 897-898.
- Faraji, H. and Tarkhani, H.** (1999). The effect of sour tea (*Hibiscus sabdariffa*) on essential hypertension. J. Ethnopharmacol. , 65(3): 231- 236.
- Herrra-Arllano, A.;** Romer, S.; Charez-Soto, M. and Tortoriello, J. (2004). Effectiveness of standardized extract from *Hibiscus sabdariffa* in patients with mild hypertension. A controlled and randomized clinical trail. Phytomedicine, 11:375-282.
- Kim, J.; So, H.;** Youn, M.; Kim, H.; Park, C.; Kim, S.; Ha, Y.; Chai, K.; Kim, X. and Park, R. (2007). *Hibiscus sabdariffa* L. water extract inhibits the adipocyte differentiation through PI3-K and MAPK pathway. J. Ethnopharmacol. 114(2):260-267.
- Lin, H.; Chen, J.;** Kuo, W. and Wang, C. (2007). Chemopreventive properties of *Hibiscus sabdariffa* L. on human gastric carcinoma cells through apoptosis induction and JNK/P38 MAPK signaling activation. Chem. Biol. Interact. 165(1): 59- 75.

Moussa, Tarek Nasser. (1999). Comparative chemical study between Alkujarat tea (*Hibiscus sabdariffa*) and tea normal (*Camella siensis*). Ibn al-Haitham Journal for Pure and Applied Sciences. 12 (1) :1-8,.

Khalaf Allah, Abdul Aziz Mohammed. (1988). Medicinal and aromatic plants and toxic substances in the Arab world. Egypt House for printing. Khartoum. P. 124

Qi, Y.; Chin, K.; Malekian, F.; Berhane, M. and Gager, J. (2005). Biological characteristics, nutritional and medicinal value of Roselle, *Hibiscus sabdariffa*. Urban Forestry Natural Resources and Environment, Circular: 604.

Muller, B. and Franz, G. (1992). Chemical structure and biological activity of polysaccharides from *Hibiscus sabdariffa*. Planta. Med. 85:60-67.

Tseng T.; Hsu J.; Lo M.; Chu C.; Chou F.; Huang C.; Wang C. (1998). Inhibitory effect of *Hibiscus* protocatechuic acid on tumor promotion in mouse. 126(2): 199-207.

Wang, J. and Lenardo, M. (2000). Roles of caspases in apoptosis, development and cytokine maturation revealed by homozygous gene deficiency. J. Cell. Sci. 113: 753-757.

Maton, A.; Hopkins, J. McLaughlin, C.; Johnson, S. ; Warner, M.; LaHart, D. and Wright, D. (1993). *Human Biology and Health*. Englewood Cliffs, New Jersey, USA: Prentice Hall. 13-81

Tomanek, R.; Doty, M. and Saundra, A. (1998). Early coronary angiogenesis in response to thyroxin. Cir. Res. 82: 587-593

Dafallah, A. and Al- Mustafa, Z. (1996). Investigation of the Anti-inflammatory Activity of *Acacia nitotica* and *Hibiscus sabdariffa*. Am. J. Chin. Med. 24: 263- 269.

Bancroft, J.; and Stevens, A. (1982). The theory and practice of histological techniques. 2nd ed. Churchill Livingstone.p:49-113.

Gighton and Hall. The reference in the medical physiology. Translated by: Mr. Sadek Hilali. (1997). World Health Organization. Regional Office for the Middle East. P. 1236-1244

Shaibi, Abeer Osman. (2004). The impact of hyperthyroidism and hypothyroidism in liver function and fat metabolism in male rats. Master thesis. Collage of Science / Baghdad University. P. 56-66

Hayali, Dalia Abdel-Latif. (2006). Electron and light microscope study of the effect of thyroxin and a plant borage (*Borago officinalis*) in the function and histological structure of the thyroid gland and effectiveness of the phosphatase enzyme in neutrophil and some standards of blood in male albino mice Master thesis. Collage of Science / Baghdad University, P. 103.

Alarcon-Aguilar, F.; Zamipla, A.; Garcia, D.; Perez, A.; Nunez, E. Sepulveda Carrillo, L. and Ramos, R. (2007). Effect of *Hibiscus sabdariffa* on obesity in MSG mice. J. Ethnopharmacol. 114 (1): 66-71.

Riis, A.; Hansen, T.; Møller, N.; Weeke, J. and Jørgensen, J. (2002). Hyperthyroidism Is Associated with Suppressed Circulating Ghrelin Levels. *J. Clin. Endocrinol. Metabol.* 88(2): 853-857.

Johnston, C. S. (2006). Strategies for healthy weight loss: from vitamin C to the glycemic response. *J. Am. Coll. Nutr.* 25(5):436-437

Steller, H. (1998). Artificial death switch: Inductions of apoptosis by chemically induce caspase multimerization. *Pro. Nat. Acad. Sci.* 95(10) 5421-5422.

[Liu ,C.](#); [Wang, J.](#); [Lee, C.](#); [Su, C.](#); [Chen , L.](#); [Hsu, D.](#) and [Lee, J.](#)(2010). Aqueous extract of *Hibiscus sabdariffa* L. decelerates acetaminophen-induced acute liver damage by reducing cell death and oxidative stress in mouse experimental models. [J Sci Food Agric.](#) 90(2):329-37.

Lila, M.A. (2004). Anthocyanins and human health in vitro investigative approach *Biomed. Biotechnol.* 5:306-313. J.

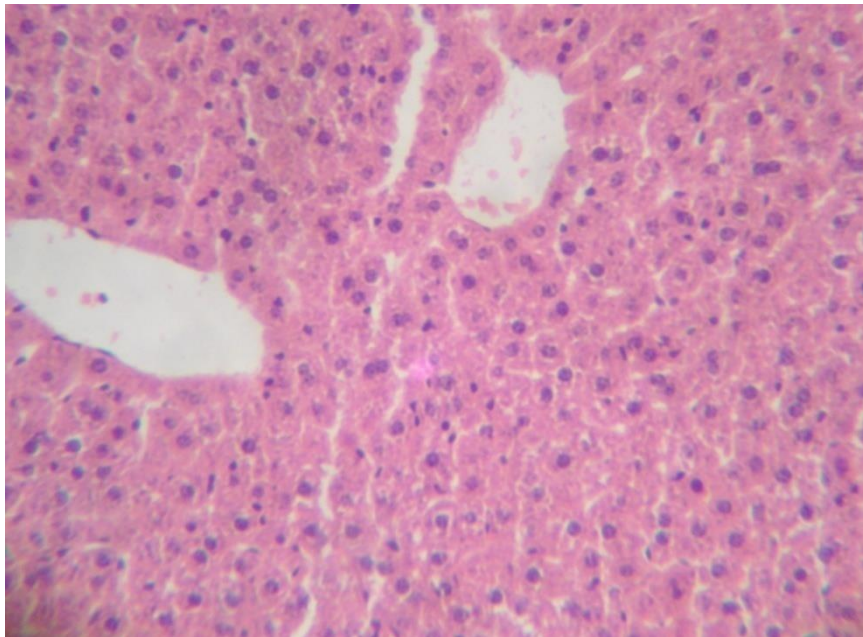
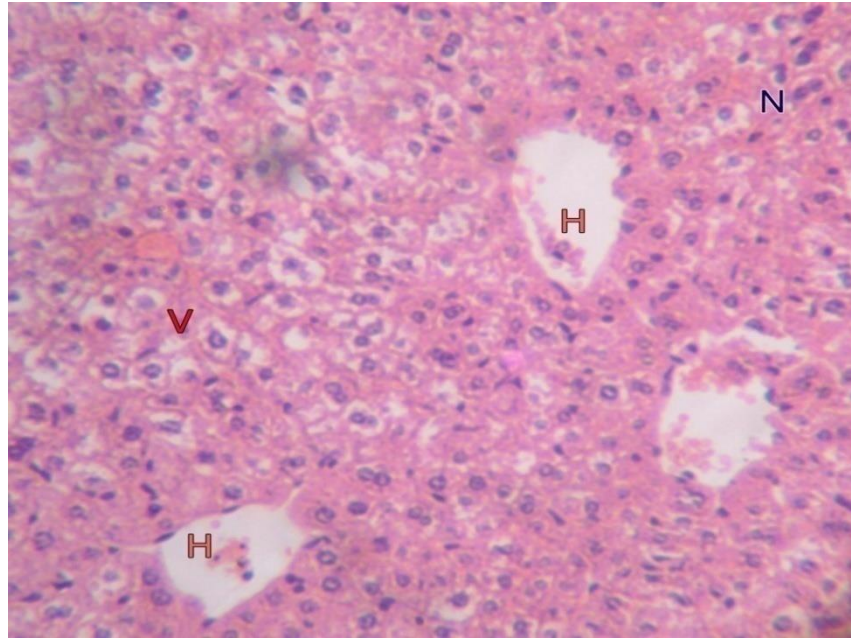
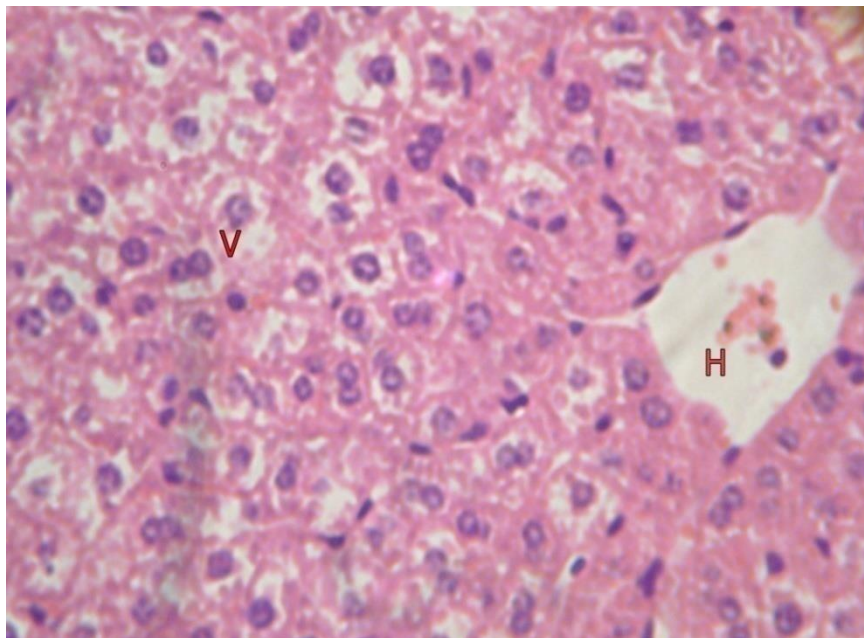


Fig. 1: Shows a section in the liver of control animal. (H&E, 450X)

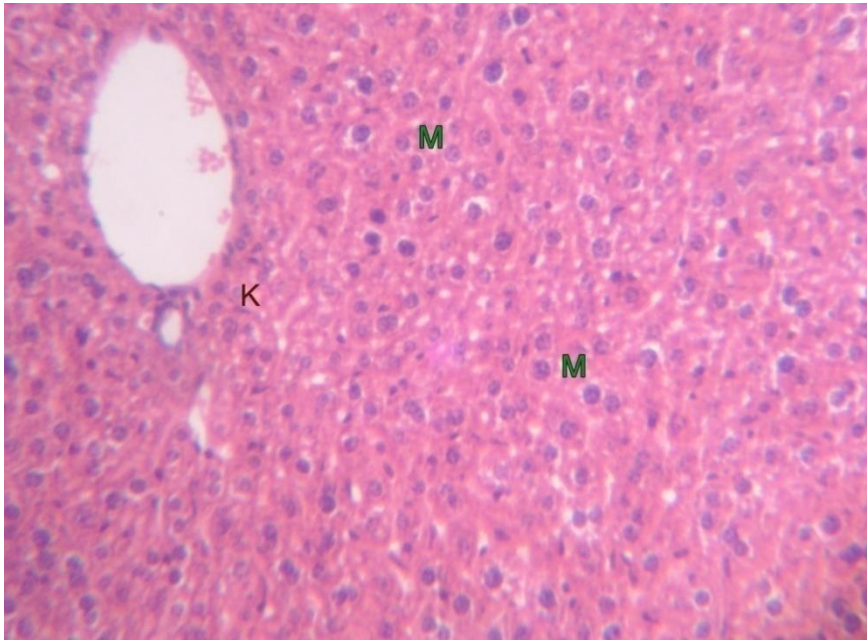


A

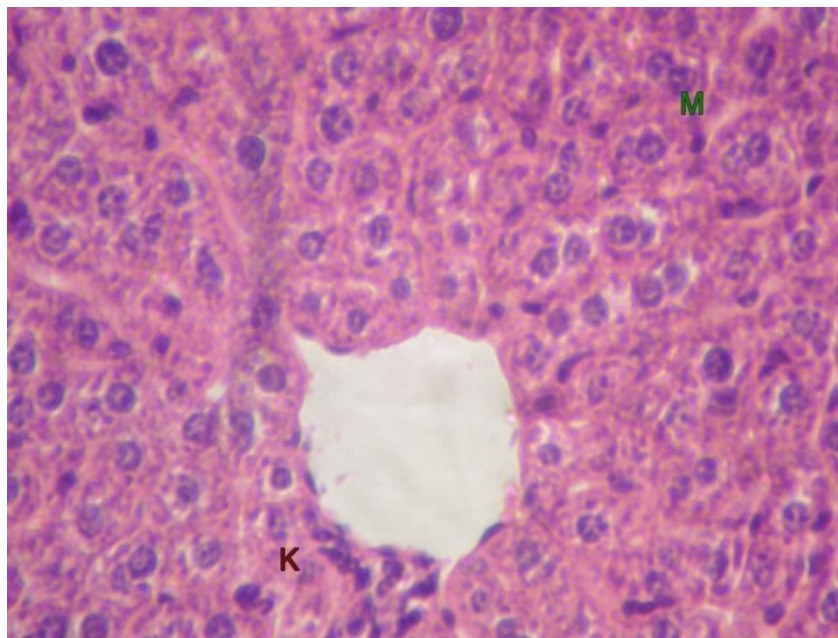


B

Fig. 2 :A section in the liver of thyroxin treated animal shows : vacuolation **V**, hemorrhage **H**, necrosis **N** (H&E,A 450X, B 900X)

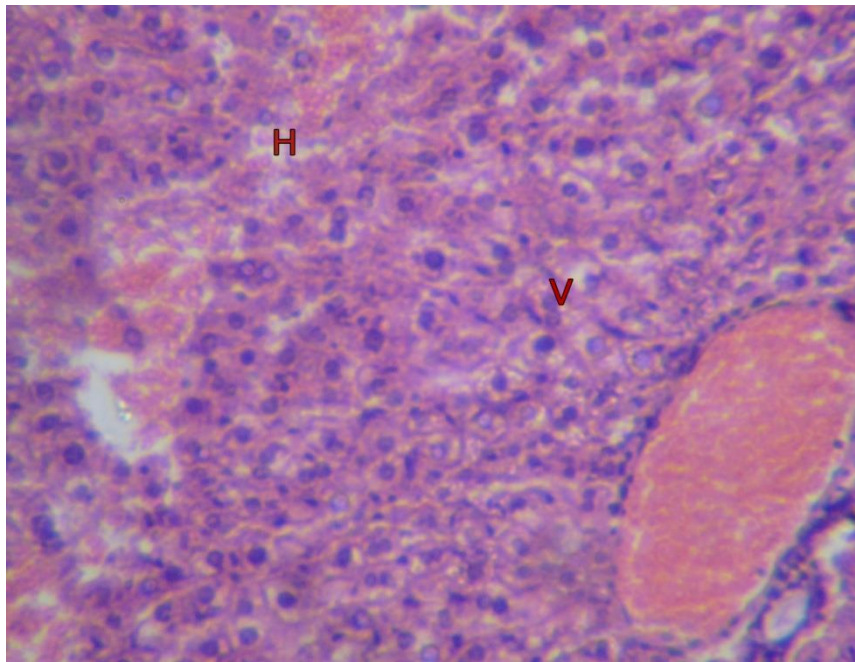


A

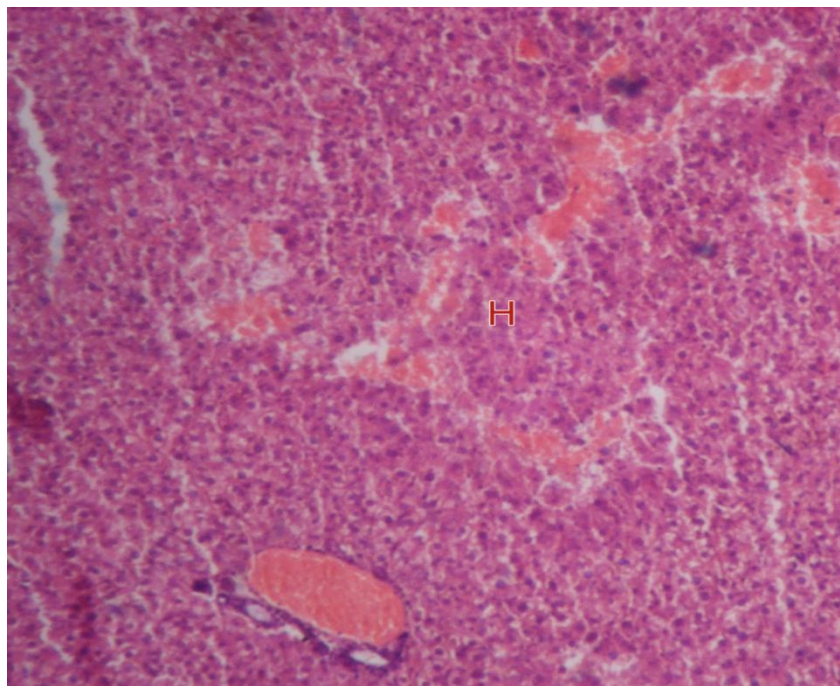


B

Fig. 3: Section in the liver of animals treated with hibiscus shows: Kupffur cells K, mitotic division M . (H&E, A 450, B 900 X)



A



B

Fig. 4: A section in the liver of animals treated with thyroxin+ hibiscus shows: hemorrhage **H** (H&E, A 450 , B 180 X).