

Effect of some strains of lactic acid bacteria and their mixture on the biochemical traits of liver and thyroid gland in male rats with hypothyroidism induced using carbimazole

Elham Kadhim Nasser*, Kithar Rasheed Majeed and Hayder Ibrahim Ali

Department of Food Science, College of Agriculture, University of Basrah, Republic of Iraq

Corresponding author: elhamnk1979@yahoo.com.

<https://doi.org/10.36077/kjas/2020/120106>

Abstract

The current study aims to use different strains of lactic acid bacteria in the treatment of thyroid diseases, Fortified milk containing the selected bacterial isolates *L. Plantarum*, *L. casei* and *L. acidophilus* and their mixture were used in a dose of 104 experimental animals of 117 male albino rats aged 9-12 weeks at an average weight of 23 g with induced hypothyroidism at a concentration of 0.6 g of carbimazole.1000g⁻¹ rat weight , while control treatment (13 mice) was drank liquid milk only. After the experiment was completed, blood samples were drawn to estimate the efficacy of liver enzymes Glutamate Oxaloacetate Transfer ease (GOT) and Glutamine Pyruvate Transferees (GPT), in addition to estimating thyroid hormones that included (Tryiodotheronin and Tetraiodothyronin) and Thyroid Stimulating Hormone (TSH). In addition, microscopic examination of tissue sections was token from the thyroid gland. The results of the study showed a significant increase in the level of liver enzymes in the group of mice affected with hypothyroidism induced by carbimazole compared to the control sample, and its return to significant increase when feeding with liquid milk containing bacteria under study and its mixture with a significant increase in the level of thyroid hormones triiodothyronine (T3) and Thyroxine (T4) and a significant decrease in the level of (TSH) when feeding with milk fortified with lactic acid bacteria. The results of the histological study of thyroid sections showed that treatment with carbimazole and hypothyroidism led to degenerative changes in thyroid follicle cells and loss of cellular coordination with infiltration of inflammatory cells, bleaching of colloid, and hyperplasia in thyroid follicles.

Keywords: lactic acid bacteria, hypothyroidism, carbimazole and thyroid hormonal

Received:15/8/2020 Accepted: 15/9/2020

Part of the Ph.D. Dissertation of the first author

Introduction

Thyroid disease is a major problem in modern society and is classified as a disease of civilization, and it is believed that lifestyle, pressure and exposure to chemicals increase the risk of thyroid disorders(12). Hypothyroidism is a lazy disease in the activity of the thyroid gland, and thus the gland does not produce enough amounts of its hormones for the body to perform its normal functions (1).To treat hypothyroidism, thyroid hormone levels must be elevated to their normal levels(8). The most important cause of hypothyroidism is immune inflammation that causes a failure in the production of thyroid hormone as in Hashimoto disease where the thyroid gland enlarges and is filled with lymphocytes for the immune response of cells and these cells attack and destroy the gland's tissue resulting in the inability of the gland to secrete its hormones in natural quantities (5). Recent studies indicate that dietary intervention offers a promising result in the treatment of thyroid diseases, as a diet to calm gastritis and treat autoimmune diseases is the best way to prevent AMU from treating thyroid diseases (12). The demand has increased in recent years for therapeutic fermented dairy products (6), as fermented food products are produced that contribute greatly to improving the immune system in the body and providing protection from disease. The

curd rich in lactic acid bacteria is one of the most popular products Milk is common in the world because of its beneficial health effects (13). The aim of the current study is to use different strains of lactic acid bacteria in the treatment of thyroid diseases

Materials and Methods

Design the experiment

The experiment was carried out in the laboratory of the Department of Food Science in the Faculty of Agriculture at the University of Basra for the period (3/31 to 1/5/2019), including a 14-day acclimatization period.

Experiment animals

In the current study, used 117 male albino rats for the age of 9-12 weeks, and weights ranged between 23-25 g. The laboratory animals were left for two weeks to acclimate, where they were distributed in plastic cages covered with tightly covered metal lids and the floor was cleaned with sawdust clean with great care of cleaning the cages and switching the sawdust every four days and placed in a laboratory temperature in it (22 -28 C°) and lighting system 12 hours light – 12 hour in a dark, In addition, the animals were provided with water and the feed provided in Table (1) manufactured according to the Subcommittee of Laboratory Animal Nutrition AIN93 .

Table (1): The materials included in the rat diet

Materials (kg)	Quantities (g/kg)
skim Milk	200
Corn Starch	670
Vitamins and minerals	30
Corn oil	50 ml
Cellulose	50

The experiment animals were divided into 9 groups, with 13 rats per group:

Negative control group (T1): A control group was given water and diet only. The second group (T2): positive control group: the diet and water containing carbimazole 0.6 g / 1000 g were given to induce thyroid atrophy. Third group (T3): were given feed and water containing carbimazole and milk product containing *L. acidophilus*. Fourth group (T4): were given feed and water containing carbimazole and milk product containing *L. plantarum* bacteria. Fifth group (T5): were given feed and water containing carbimazole and milk product containing *L. casei* bacteria. Sixth group (T6): were given feed and water containing carbimazole, *L. acidophilus* and *L. plantarum*. Seventh group (T7): were given feed and water containing carbimazole and GOT enzyme in serum

milk product containing *L. plantarum* and *L. casei*. Eighth group (T8): were given feed and water containing carbimazole and milk product containing *L. acidophilus* and *L. casei*. Ninth group (T9): were given feed and water containing carbimazole and lactic product containing *L. acidophilus*, *L. casei* and *L. plantarum*

Collection of blood samples

Blood was drawn from the heart using 5 ml medical syringes in plastic anticoagulant-free tubes to obtain a sufficient amount of serum for biochemical tests. The serum was separated with a centrifuge at 4000 rpm for 10 minutes and then the serum was collected by a micropipette. Divide the serum in several clean and sterile tubes and keep it frozen at -18c° until the biochemical tests are performed.

The chromatic method was used to estimate the effectiveness of AST in serum according to Brutis (3) as in the following equation:

$$\text{AST enzyme U/L} = \frac{\text{Read the sample}}{\text{Read the standard solution}} \times 67$$

GPT in serum

The chromatic method was used to estimate the effectiveness of ALT in serum according

to Brutis(3) as in the following equation:

$$\text{ALT enzyme U/L} = \frac{\text{Read the sample}}{\text{Read the standard solution}} \times 133$$

Measuring the level of the hormone T3 and T4 in the blood serum

The concentration of the T3 and T4 hormone in the serum of the treated groups as well as the control group was measured by following the instruction steps accompanying the T4 hormone assay kit.

Measuring the level of TSH in the blood serum

The thyroid-stimulating hormone (TSH) was measured in the blood serum by following the steps attached to the diagnostic kit for checking the imported TSH hormone, according to the manufacturer's instructions for the Elisa device.

Histological Study

Thyroid tissue sections were prepared using the method recommended by Krueger *et al.* (4) imaging microscopy and under different magnification power. Microphotography the textile sections were photographed using the melji light microscope equipped with a Canon high-definition digital camera. Microscopy of histological sections and microscopy

The histological sections of the samples were examined using microscopy and under different magnification power.

Results and discussion

Effect of lactic acid bacteria on liver enzymes

AST enzyme

The results of the Figure (1) show the effect of a lactic product fortified with lactic acid bacteria on AST in male mice with hypothyroidism induced by carbimazole, as the results of the study showed the presence of a significant rise $P < 0.05$ in the level of liver enzymes in the group of mice with hypothyroidism compared to control samples, as the average of the control sample reached 47 units / liter in the blood of the affected mice, compared to the control sample with an average of 20.26 U.L⁻¹. This may be due to the inflammatory infiltration that occurs in the liver tissue due to the effect of carbimazole, which is one of the factors that cause thyroid disorders through inhibition of hormone synthesis. Hypothyroidism leads to hypoxia in the body tissues, the liver, and consequently, damage to the liver tissue and high concentration of AST (3), as the liver is the primary organ producing these enzymes that increase their level in cases of hepatitis and heart disease (6). Also from the figure (1). we note that feeding the mice with carbimazole-induced hypothyroidism in the milk product containing *L. casei* and *L. planetarium* resulted in a significant decrease in the level of enzyme activity in the rat blood serum to 24 and 25 U/L,

respectively, while it did not lead feeding of mice in the milk product containing *L. acidophilus* to a significant decrease in the level of the enzyme as it averaged 39 U.L⁻¹ and reached the lowest average level of the enzyme when the mice feeding on the milk product containing a mixture of *L. casei* and *L. plantarium* reached 22 U.L⁻¹ compared to the positive control sample and significant

differences from the effect of the mixture of *L. acidophilus* and *L. plantarum* in the AST enzyme level, when the average dose was 31.13 U.L⁻¹ when feeding mice with therapeutic milk containing the mixture of the three isolates of the lactic acid bacteria, the average level of the enzyme reached 28.01 U.L⁻¹.

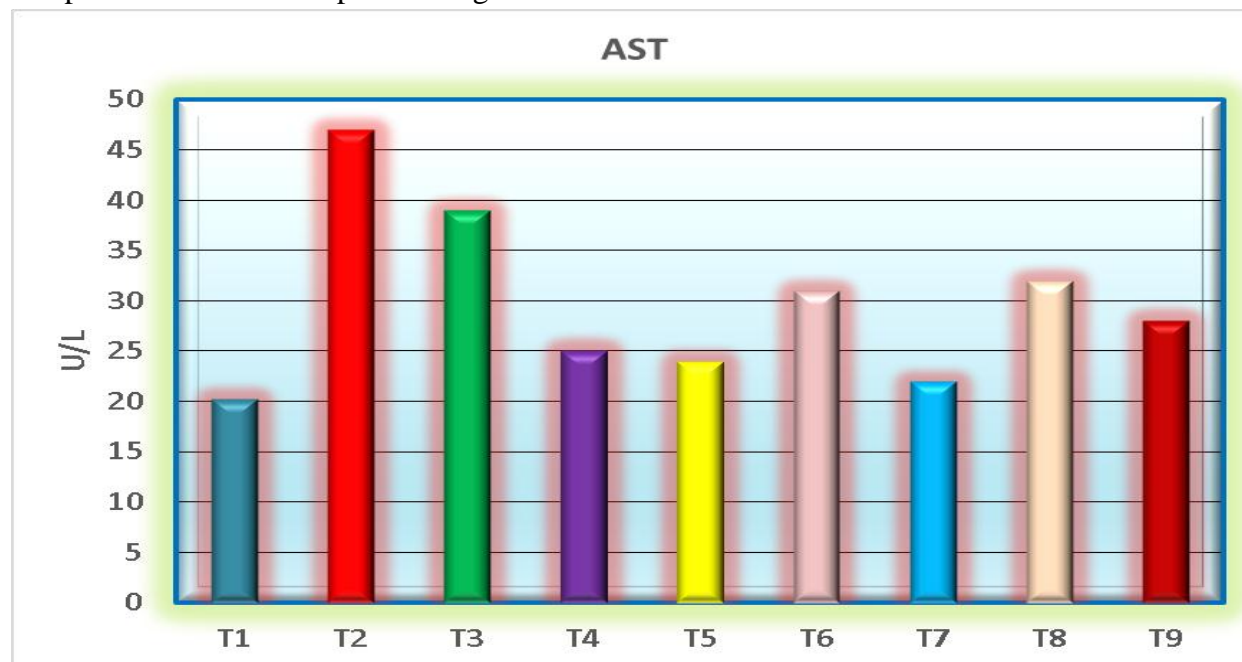


Figure (1): Effect of therapeutic milk fortified with lactic acid bacteria on AST U.L⁻¹ in male mice with carbimazole-induced hypothyroidism.

RLSD for bacterial effect = 6.18

ALT enzyme

Figure (2) shows that the level of ALT enzyme in the control group mice which reached 50.96 units / liter, as $P < 0.05$ in the group of mice with induced hypothyroidism increased significantly to 82.2 U.L⁻¹ and then returned to the gradual decrease to 52, 51 and 52 U.L⁻¹ when mice are feed with the lactic product containing *L. casei* and *L. plantarium* and a mixture of *L. casei* and *L.*

planetarium respectively, and *L. acidophilus* and a mixture of *L. acidophilus* and *L. casei* added to the milk product to reduce the ALT enzyme, which averaged 72 and 70 U.L⁻¹ respectively. The average enzyme when feeding the mice with the milk product containing the mixture of the three types of bacteria *L. acidophilus*, *L. casei* and *L. acidophilus*, was 59 U.L⁻¹. This may be due to the inflammatory infiltration of the liver tissue due to the effect of carbimazole,

which is one of the factors that cause thyroid disorders by inhibiting the synthesis of thyroid hormones, leading to the occurrence of hypoxia in the tissues of the body, including the liver, and thus the occurrence

of damage to the liver tissue and high concentration of AST (8), as the liver is the primary organ producing these enzymes that are increasing in levels of hepatitis and heart disease(7).

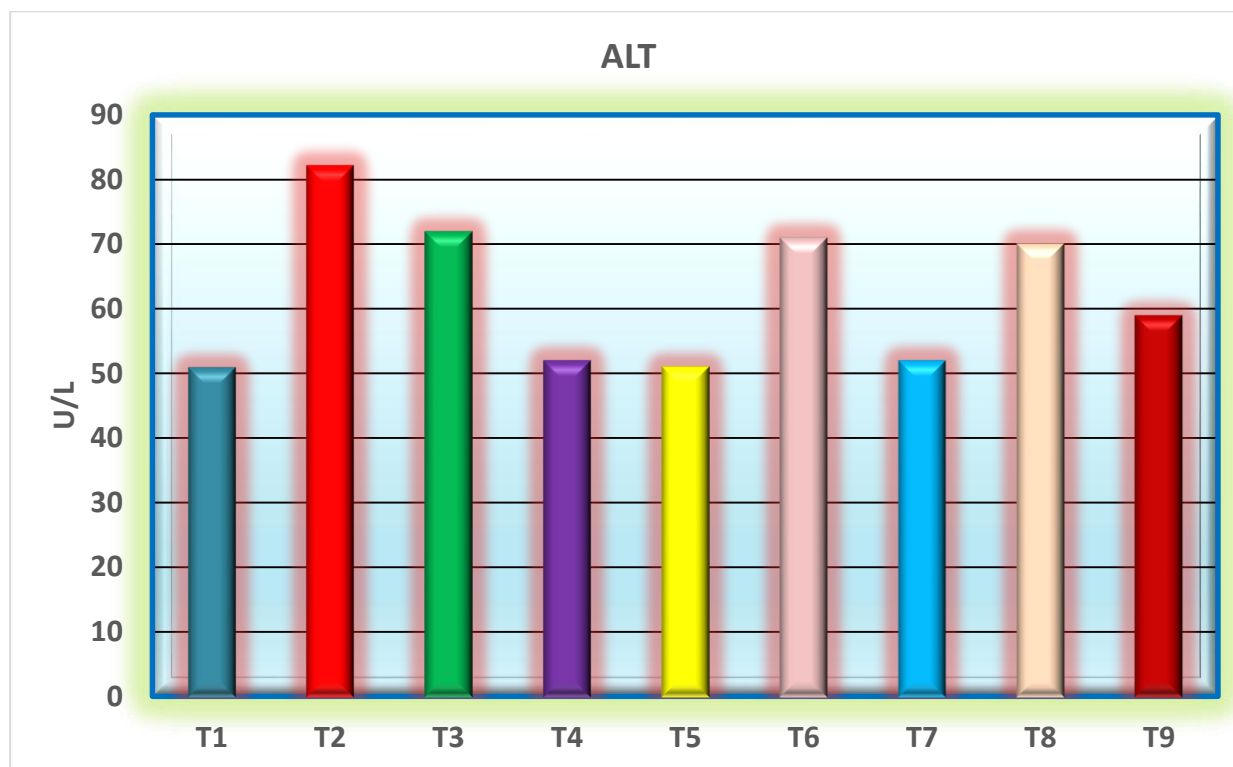


Figure (2): Effect of therapeutic milk fortified with lactic acid bacteria on ALT U.L⁻¹ in male rats with carbimazole-induced hypothyroidism

RLSD for bacterial effect = 8.99

The effect of lactic acid bacteria on thyroid hormones

T3 hormone

The results of Figure (3) showed a significant decrease in the level of the hormone T3 in the serum of the rats treated with the carbimazole group compared to the control group, as the average was 1.9 nm.L⁻¹ in the control group and 0.99 nm.L⁻¹ in the members of the group with induced hypothyroidism, the reason is due to the fact

that Carbimazole inhibits the transformation of T3 and T4 hormones in tissues or closes T3 formation pathways (14). Or, it may reduce the rate of T3 binding to specific proteins transporting to it, TBG and TBPA, and then lower serum T3 concentration (9). Among the results of the figure also, it is noted that the mice with milk containing lactic acid bacteria led to raising the level of the hormone T3 in the blood serum of the treated mice, as the averages reached 1.22, 1.82 and 1.81 nm. / L⁻¹, on the level of d. L.

planetarium and *L. casei*, respectively, and 1.55 nm.L^{-1} when administered with a mixture of *L. acidophilus* and *L. plantarum* and 1.8 nm.L^{-1} when feeding with a mixture of *L. casei* and *L. plantarum* and 1.58 nm.L^{-1} when feeding with a bacterial mixture *L. acidophilus* and *L. casei* As for the feed with the mixture of the three lactic acid bacteria isolates, the enzyme average was 1.9 nm.L^{-1}

without significant differences from the control mice group. This rise is an indication of the ability of lactic acid bacteria to repair cellularly and raise the level of thyroid cells to secrete hormones. This means that the bacteria contributed to the regulation and balance of the gland's work to secrete its hormones and remove the effects of carbimazole

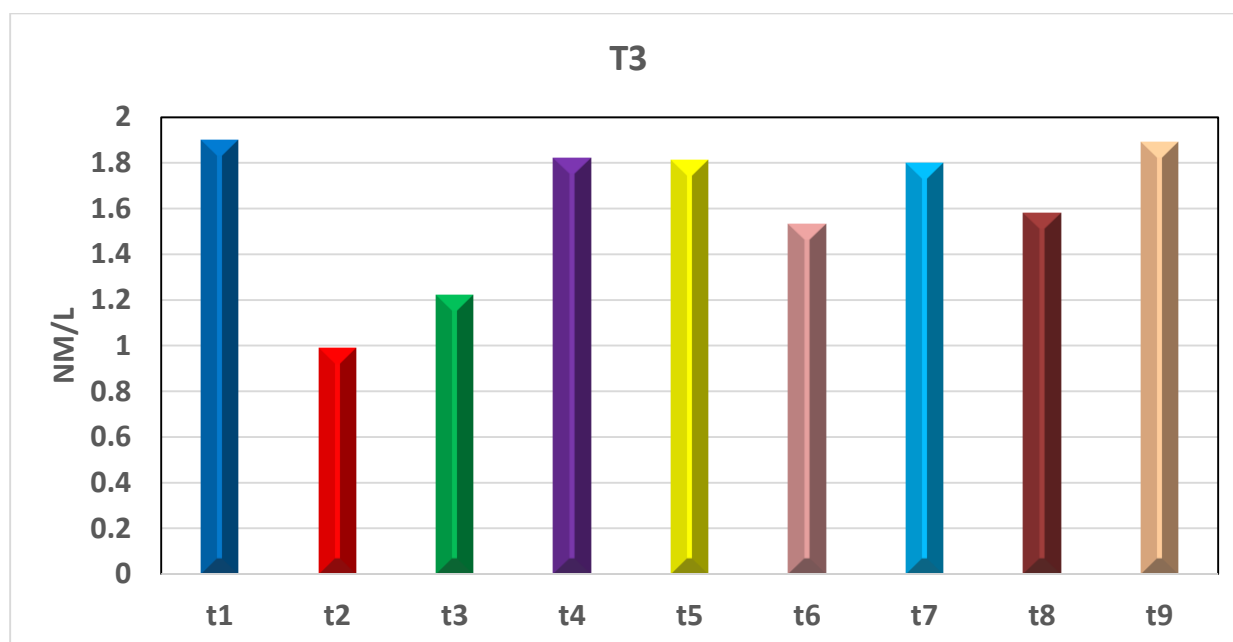


Figure (3): Effect of therapeutic milk fortified with lactic acid bacteria on T3 hormone nm.L^{-1} in male mice with carbimazole-induced hypothyroidism

RLSD for bacterial effect = 0.1

T4 hormone

The results of the Figure (4) showed a significant decrease in the level of the hormone T4 in the serum of mice in the group treated with carbimazole compared to the control group, where the average was 51.6 nm.L^{-1} in the control group and 4.00 nmol / L in the members of the group with induced hypothyroidism, and the reason for the decrease in hormone T4 due to

dysfunction of hypothalamus cells and then hypothyroidism in patients with diabetes and low levels of insulin in the blood serum lead to a decrease in the level of T3 and T4, the hormone returned to rise in its level when the lactic product containing *L. acidophilus* was given to 46.64 nm.L^{-1} the mean increased to the highest when mice were fed with the milk product containing *L. planetarium* and *L. casei* mixture, where the average was 50.0 nmol / L while the

averages reached 47 and 48.12 nm.L.⁻¹ when mice were fed with a mixture of *L. acidophilus*, *L. plantarum* and *L. acidophilus* and *L. casei*, respectively and without significant differences $P < 0.05$ on

the level of the hormone in the blood of the mice by mixing the isolates of the three lactic acid bacteria, which averaged 50 nm.L.⁻¹

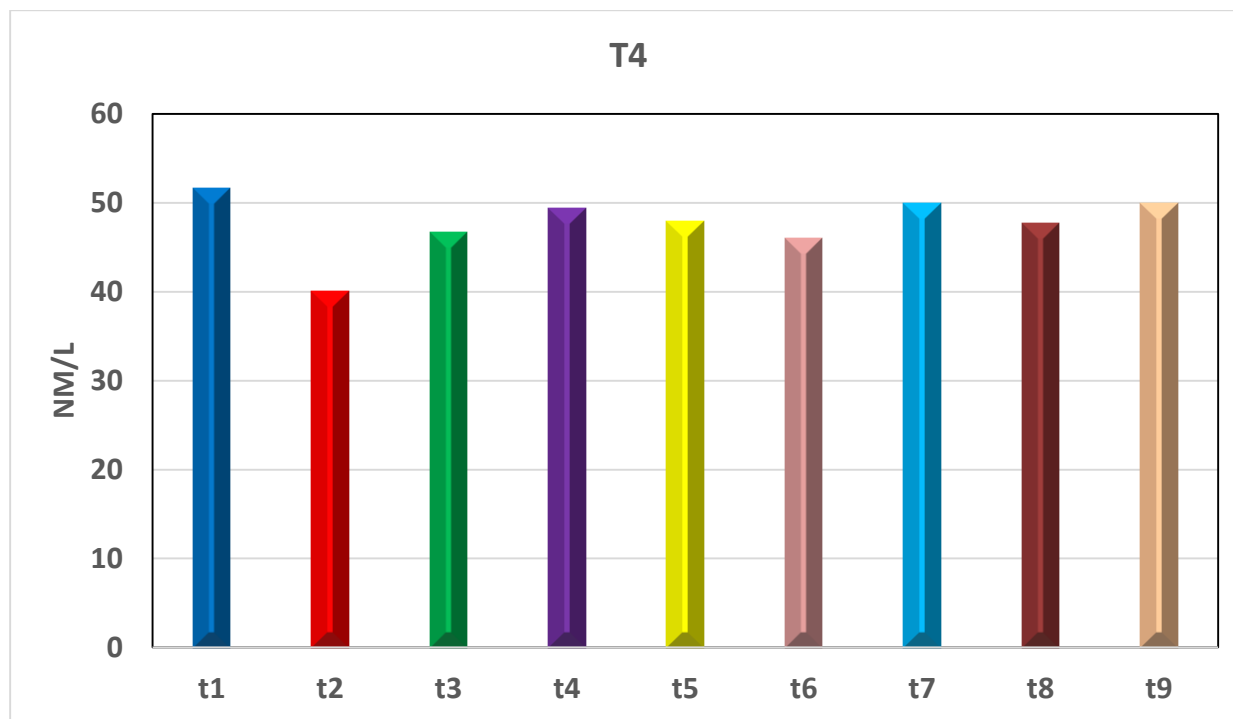


Figure (4): Effect of therapeutic milk fortified with lactic acid bacteria on T4 nm.L.⁻¹ in male mice with carbimazole-induced hypothyroidism

RLSD for bacterial effect = 3.33

TSH Hormone

The results of Figure (5) showed the elevated level of TSH in rats with carbimazole-induced hypothyroidism compared to a control sample of 1.75 nm.L.⁻¹. When feeding with milk containing lactic acid bacteria, it led to return the TSH to its normal levels. The mean was 4.19 in the third treatment, 2.82 in the fourth treatment, 2.75, 2.01, and 1.81 nm. L.⁻¹ in the fifth,

sixth, and seventh treatments respectively. While feeding with a mixture of three lactic acid bacteria isolates, the mean TSH reached 1.95 nm.L.⁻¹. The reason may be attributed to the fact that carbimazole leads to increased secretion of the TSH hormone, since carbimazole is one of many compounds that have the ability to inhibit the formation of the thyroid hormone, regardless of the way it affects thyroid stimulator (11).

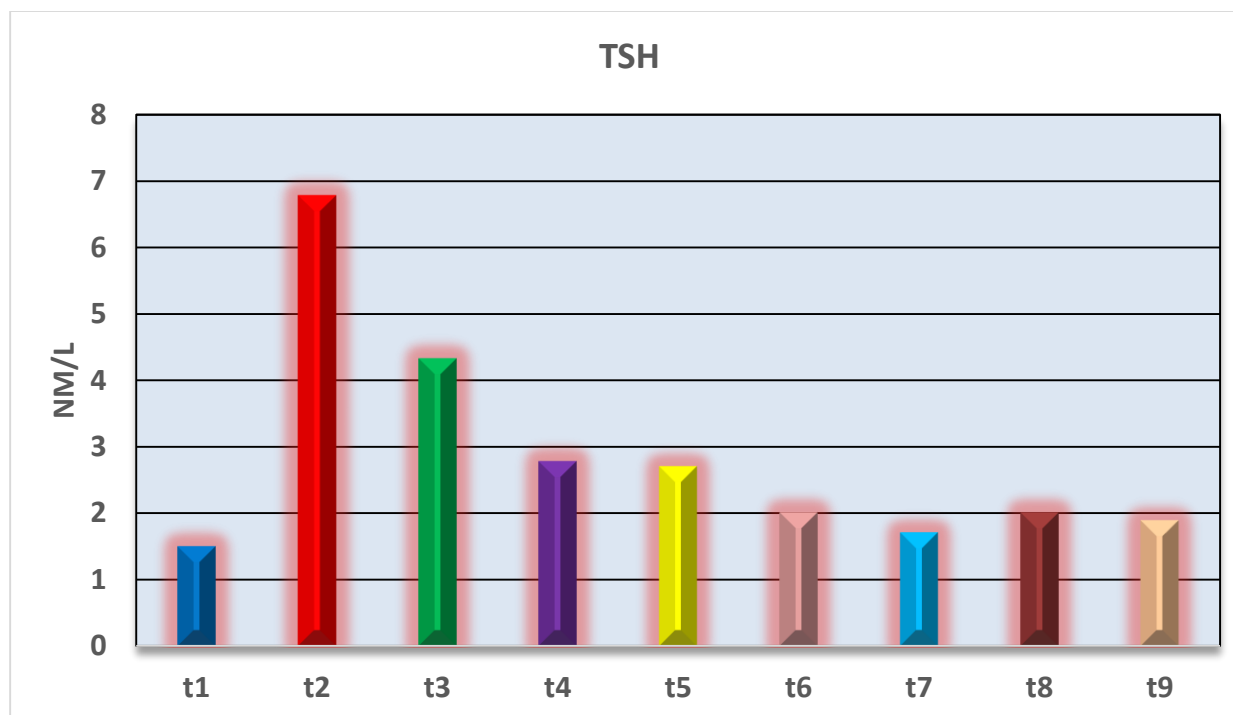


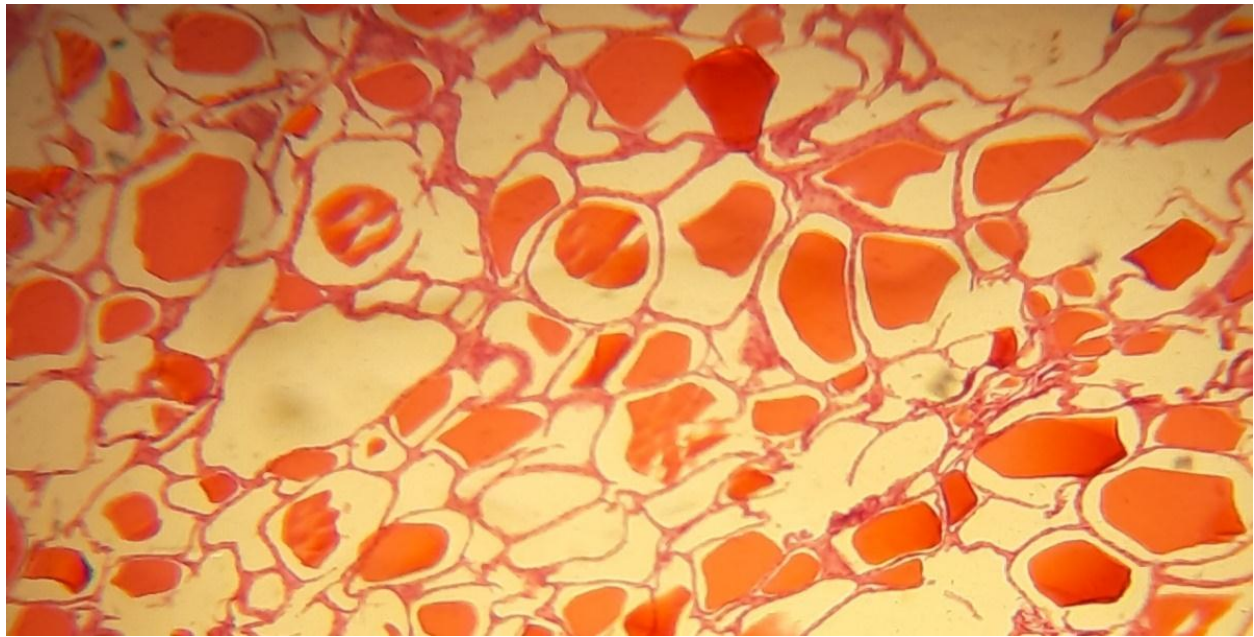
Figure (5): Effect of therapeutic milk fortified with lactic acid bacteria on T4 nm.L.⁻¹ in male mice with carbimazole-induced hypothyroidism.

Histological study

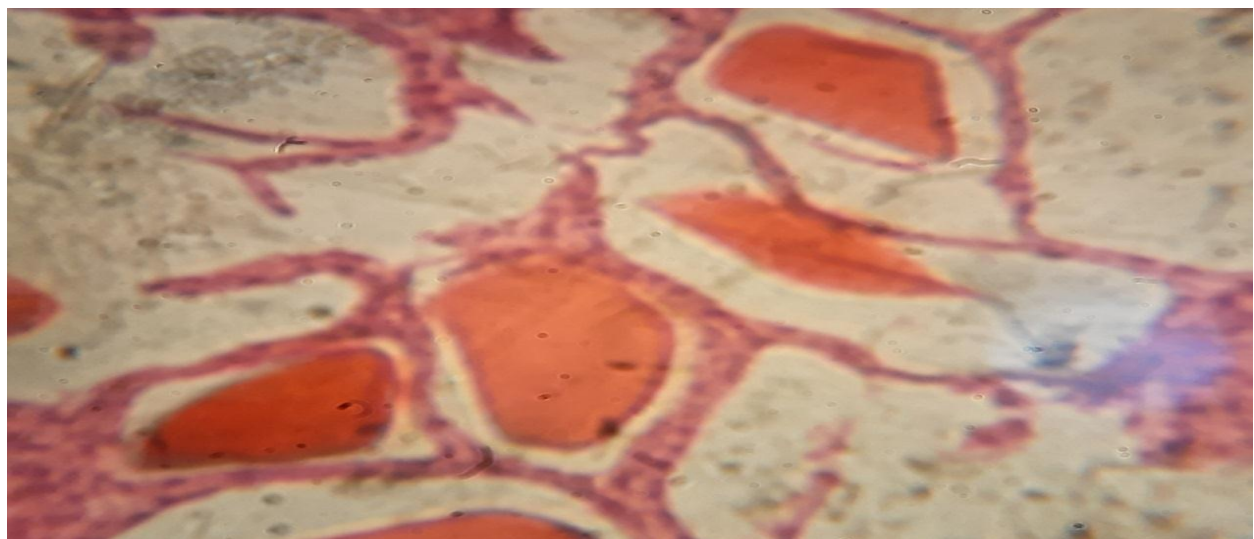
Control group

Optical microscopy of sections of the thyroid gland of the control group showed the distinction of the glandular paranchynia of the visceral tissue of the glandular follicles in varying sizes and the central cavity of each vesicle lined with epithelial cells appears. Epithelial cells lining the vesicles, either cubic or vertical, depending on the effectiveness of the

vesicles, there is also another type of cell called parathyroid cells or C cells, and these are located between the vesicular cells and the basal membrane and some of them are embedded in the areas between the vesicles within the interfollicular region, which is larger than the cells. The vesicle, separated by the follicles, straps of the connective tissue are an extension of the fibrous sheath that surrounds the thyroid gland as a whole (Picture 1 and 2)



Picture (1): a cross section of thyroid tissue for male mice in the control group, showing follicles of different sizes, epithelial cells and colloid with a vacuum between the substance and the lining cells. Magnification (40x).

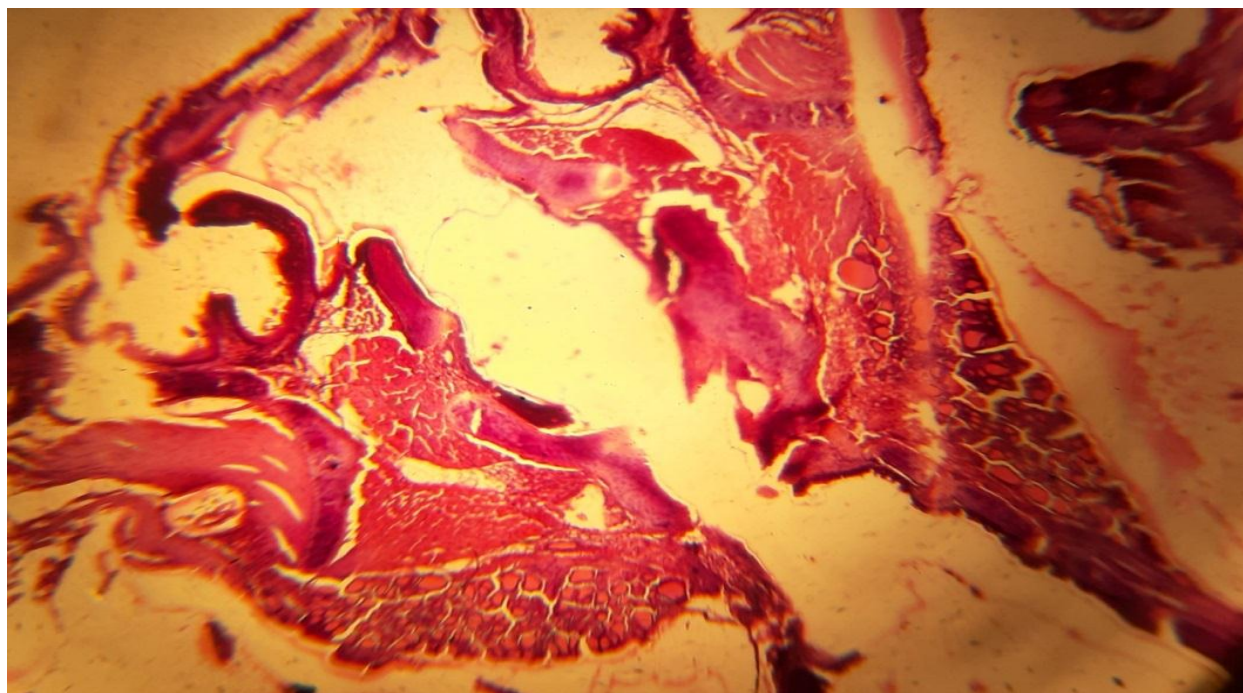


Picture (2): A cross section of thyroid tissue for male mice in the control group, showing the size of follicles and colloidal material that occupy the cavities and there is a space between the cells lining these follicles and the center of the follicle. These follicles are lined with cubic epithelial cells (H & E 40X).

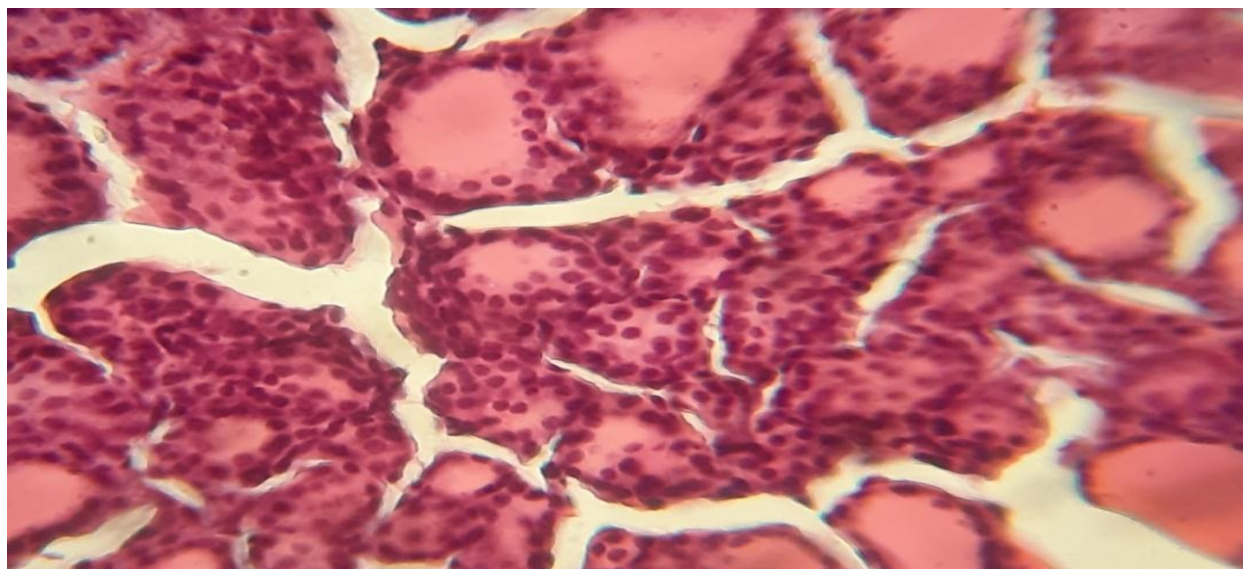
The group treated with carbimazole

The results of microscopic examination of tissue sections in the group of rats treated with carbimazole for a period of 30 days indicated a group of pathological tissue changes that included clear changes in the size of the vesicles lined to flat vesicle cells and others appear as vesicles with an evacuation void and there is a lack of C cells of the vesicle, there is also an increase in the

density of the material between the vesicles with a decrease in colloidal matter within the cavities of the vesicles, while another group of vesicles appeared completely free of colloidal secretory material. Moreover, the results showed an increase in the density of the tissue between the vesicles and a heavy infiltration of the inflammatory cells, and collagen fibers. It is deposited densely and irregularly between the follicles (Fig. 3 and 4).



Picture (3): a cross section of the thyroid gland tissue for male mice within the carbimazole treatment group shows severe atrophy in most follicles and an increase in the density of the tissue between the lobes with irregular and precipitation of colloidal fibers. (H & E 40X).



Picture (4): A cross section of the thyroid gland tissue of male mice in the carbimazole treatment group shows the dissolution of the epithelial layer and the low number of cells (c) with thick infiltration of inflammatory cells. (H & E 40X).

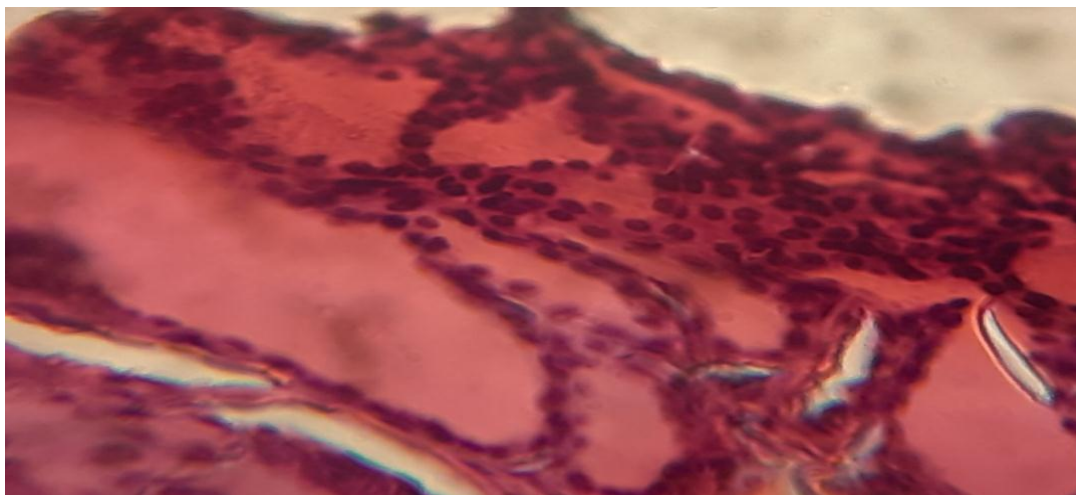
The results of the histological examination of the thyroid gland showed that there are different changes in the tissue of the thyroid gland. In some regions, large numbers of thyroid follicles of small size appeared, which are full of colloid, which is characterized by red color and the presence of a section of follicles that are devoid of colloid. The variations in the changes in the tissue of the thyroid gland treated with carbimazole indicate the characteristics that appear to hinder the work of the thyroid gland in the manufacture of its hormones, and this is what Ahmed. (2). The presence of this large number of follicles of the gland indicates an enlarged thyroid gland as a result of an increased concentration of TSH hormone, where TSH regulates the work of the thyroid gland through negative feedback to the gland under the hypothalamus, in the case of a lack of thyroid hormones in the blood circulation, stimulates the pituitary

gland for the secretion of TSH, which has an effect on stimulating the thyroid gland and this leads to gland enlargement and the occurrence of hyperplasia, and despite the occurrence of hyperplasia due to increased stimulation of the hormone TSH for gland follicle cells, the cells are effective in producing their hormones to do carbimazole, which leads to a decrease in the ability of follicle cells for response to stimulation and hormonal synthesis (8). The appearance of gaps in colloids may be attributed to depleting the hormone stores inside the follicle and this is evidence of the inhibitory action of carbimazole to manufacture hormones in the body and these results are consistent with what was confirmed by Krueger. (4).

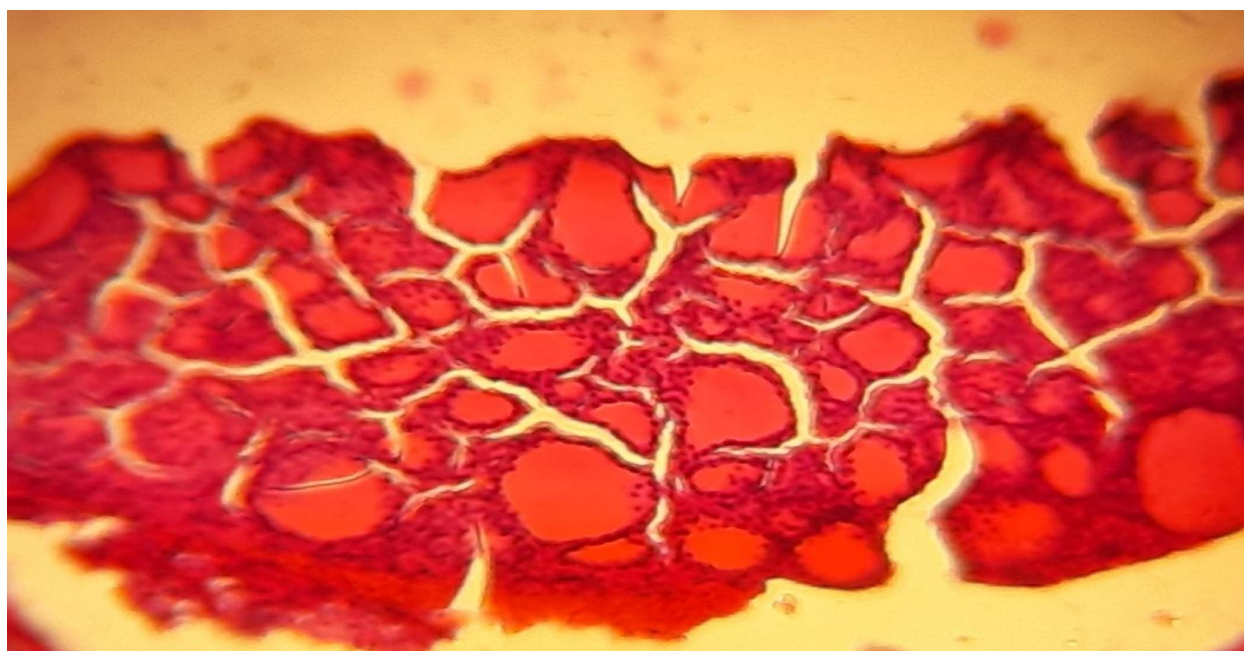
The group treated with bacteria The results of the histological study confirmed the sections of the thyroid gland of the rat group after the feed with lactic acid bacteria

to tissue changes that included the presence of some macro follicles and others that appear to be a normal size. There is a regularity in the arrangement of vesicles in the form of lobes with the presence of the

connecting tissue that separates them, which includes blood vessels and collagen fibers. All vesicles are lined with regular vesicular cells. Lining of the sacs and some of them in thick infiltration (5,6)



Picture (5): A cross section of the thyroid gland tissue of male mice within the group treated with bacteria shows the presence of regular large-sized follicles containing colloidal material () lined with cubic epithelial cells () with some inflammatory cells. (H & E 40X).



Picture (6): A cross section of the thyroid tissue of male mice within the group treated with bacteria shows most follicles with normal sizes close to the normal

shape of the tissue. The cavity of each follicle is occupied by a colloidal substance of an acidic nature and multiplied in the epithelial cells lining. (H & E 40X).

Conclusion

Feeding with liquid milk containing lactic acid bacteria raised the level of functioning of the affected thyroid gland.

References

- 1-Abdelatif, A. M. and I. H. Saeed.2009.Effect of Altered Thyroid Status in the Domestic Rabbit (*Lepus cuniculus*) on Thermoregulation, Heart Rate and Immune Responses. Sudan. Global Veterinaria,3(6):447-456.
- 2-Ahmed, T. S.2010.Histological characteristics of the thyroid gland induced with carbimazole in albino mice and their fetuses. Master thesis. College of Science. University of Tikrit. Republic of Iraq.
- 3- Burtis, C. A. and W. B. Ashwood.1999.Tietz Textbook of Clinical Chemistry. Saunders. USA. pp.819-861and 1245-1250.
- 4-Krueger, W. K.; H. Gutierrez-Bañuelos; G. E. Garsten; B.R. Min; W. E. Pinchak; R. R. Gomez; R. C. Anderson; N. A. Krueger and Forbes, T. D. A.2010.Effect of dietary tannin source on performance feed efficiency, ruminal fermentation, and carcass and non-carcass traits in steers fed a high-grain diet. Animal Feed Science and Technology,159(1–2):1-9
- 5-Krysicki, M.; M. Jaworska; B. Popowicz; J. Jankiewicz-Wika; M. Klencki and Słowińska-Klencka, D.2014.The incidence of hypothyroidism symptoms and risk factors for cardiovascular events in subclinical hypothyroidism]. Pol. Merkur Lekarski. Jul.,37(217):10-16.
- 6-Longoria-García, S.; R. E. Belmares-Cerda; M. I. Flores-Verastegui; J. C. Contreras-Esquível; J. C. Montanez-Saenz and Cruz-Hernández, M. A.2016.Prebiotics, probiotics, symbiotic and functional foods in control and Treatment of Type II Diabetes Mellitus and Colorectal Cancer. (In Probiotics and Prebiotics in Human Nutrition and Health. In. Tech.190.).
- 7-Lucio, G. C.; H. Ernest; A. L. Dawid; J. R. Donald and William, F.G.2005.Current Protocolisn Toxicology. Part 14.(Edited by: Lucio, G. Costa. University of Washington. Johan Willy and Sons. USA.).
- 8-Maja, C. M.; K. Alexandra and Vukosava, D.2004.Methimazole induced hypothyroidism in rats: Effect on body weight and histological characteristics of thyroid gland. Jugoslov. Med. Biohem., 23:143-147.
- 9-Miao, F.; W. Yu; Y. Wang; M. Wang; X. Liu and Li, F.2010. Effect of corn peptides on exercise tolerance, free radical metabolism in liver and serum glutamic-pyruvic transaminase activity of mice. African Journal of Pharmacy and Pharmacology,4(4):178-183.
- 10- Pruett, H. E.; D. L. Thompson; J. A. Cartmill; C. C. Williams and Centry, L.

R.2003.Thyrotropin releasing hormone interaction with growth hormone secretion in horse's. J. Anim. Sci.,81:2343–2351.

11-Sarne, D.1999.Effect of the environmental, chemicals and drugs on thyroid functions. The thyroid and its diseases; Ch:5A. Medical Director. Endocrinology and Metabolism Clinics. University of Chicago. USA. pp.1-14.

12-Soon, T. K. and P. W. Ting,2018. Thyroid diseases and diet control. Journal of

Nutritional Disorders and Therapy,8(1):224-230.

13-Vasiljevic, T.; T. Kealyand and Mishra, V. K.2007. Effect of β -glucan addition to a probiotic-containing yogurt. Journal of Food Science, 7(72):405-411

14-Woeber, K.A.2000.Update on the management of hyperthyroidism and hypothyroidism. Arch. Fam. Med., 9:743-747.