

Neurological manifestations of intussusceptions in a group of patients aged below 5 years

*Dr.Jasim Mohammed hashim

الخلاصة:

الخلفية: يحدث تداخل الأمعاء عندما يحتبس جزء من الأمعاء داخل جزء آخر مجاور له ويعد السبب الأكثر شيوعاً لانسداد الأمعاء بين ثلاثة أشهر وخمس سنوات من العمر. أغلب الحالات في الأطفال ليس لها سبب واضح.

الهدف من الدراسة: لدراسة أهمية العلامات والإعراض السريرييه ومنها الغير مألوفة وخاصة الأعراض العصبية.

الطريقة: أجريت دراسة مقطعية لحالات تداخل الأمعاء للأطفال دون الخامسة من العمر للفترة منذ الأول من شباط ٢٠٠٩ إلى الثلاثون من حزيران ٢٠١٠ في مستشفى الزهراء التعليمي للنسائية والأطفال في النجف. تم اخذ المعلومات الآتية و تتضمن: الاسم، الجنس، العمر، مدة المرض، الأعراض السريرية، ثم اجري فحص المرضى بإجراء الأشعة السينية البسيطة للبطن والأشعة فوق السمعية (السونار). ثم جمعت المعلومات للتركيز على الأعراض السريرييه (الأم البطن،التقيء،الإسهال الدموي) وكذلك الأعراض العصبية (الخمول، الصرع،تغير في حاله الوعي).

النتائج: تم دراسة ٦٨ مريض خلال فترة الدراسة بمتوسط عمر(٩)أشهر. الذكور كانوا أكثر من الإناث. أغلب المرضى يعانون من الم في البطن(٨٩,٧%)، تقيؤ(٨٢,٣%)، ودم في البراز(٦٣,٣%)، بينما كانت الأعراض العصبية الخمول(٦٦%)الاختلاج (١٠%) وتغير في حاله الوعي (٢٤%)،أثناء الفحص وجد غائط هلامي احمر اللون في(٨٩,٧%) منهم عند إجراء فحص المخرج بينما وجدت كتلة بطنيه في (٥٢,٩%) من الحالات. **الاستنتاج:** إن تداخل الأمعاء أكثر شيوعاً في الذكور من الإناث، ورغم أن ثلاثية الأعراض السريرية هي الألم البطني و التقيؤ والغائط الدموي إلا أن تداخل الأمعاء يجب أن يضع في التشخيص عند الأطفال الذين يعانون من الخمول، الاختلاج، تغير في حاله الوعي حتى في غياب الأعراض السريرية الشائعة.

Abstract

Background: Intussusception occurs when a portion of the alimentary tract is telescoped into an adjacent segment. It is a one cause of intestinal obstruction between 3months and 6years of age. The majority of cases in children are idiopathic.

Aim of study: To study the nature of neurological signs and symptoms and to describe the characteristics of the patients presenting in this a typical way.

Patients and Methods: Patients aged 3mo-5yr with signs and symptoms consistent with intussusception admitted to Al-Zahra's teaching hospital from the 1st Feb.2009 to the 31st of July 2010. History was taken including; name, sex, age, duration of illness, clinical manifestation, examination, erect plain abdominal X-ray and abdominal

ultrasound. Data were collected to evaluate clinical manifestation (Abdominal pain, vomiting, bloody stool), neurological symptoms (lethargy, convulsion, fluctuating consciousness). abdominal X-ray and ultrasound as guidance for diagnosis of intussusceptions in children.. Barium enema was not done because of lack facilities.

Results: (68) patients were studied, their mean age was (9) months. Males were more than females with a male: female ratio of 1.4:1. Most of patients presented with abdominal pain, vomiting, blood in stool.

While lethargy (66%), convulsion (10%), and fluctuating consciousness (24%). During examination a red current jelly stool (89.7%) and abdominal mass was found in (52.9%) of cases.

We found that most common sign detected by abdominal ultrasound was the presence of abdominal mass (63%), further more ultrasound can be used to detect peritonitis. X-ray was done in all patients (100%), but it was inconclusive in most cases 71%.

Conclusions: Intussusception is more common in boys than in girls. Trait of Abdominal pain, vomiting, blood in stool are commonest presentation. Intussusception should be considered in the differential diagnosis in young children presenting with lethargy, convulsion and/or sudden alteration of consciousness (main complain) even in the absence of one or more classical symptom of intussusception. ultrasound of abdomen are useful methods in the diagnosis

Key words; Intussusception, neurological manifestation

INTRODUCTION

Intussusception is defined as: when one portion of the gut (intussusceptum) becomes invaginated within an immediately adjacent segment (intussusceptient), invariably it is the proximal into the distal bowel. The lead point or the apex of the intussusceptions is typically a Peyer's patches in the terminal ileum, the ileocecal valve itself, or a part of the cecal wall, but very rarely in pediatrics an intussusception has a pathological lead point^[1,2]. It is a common cause of intestinal obstruction between 3 mo and 6 yr of age, the majority of cases in children are idiopathic^[3,4].

Clinical manifestation

Most patients with intussusception were well nourished healthy baby except the child with cystic fibrosis who may fail to thrive^[5,6]. From the symptoms point of view (85%) of patient presented with sudden onset of abdominal pain that is characterized by being episodic screaming, with spasm, and commonly draws his

legs up to the abdomen, becomes pale, may sweat and holds his breath, which makes the mother feels that this is an unordinary cry and something serious is going on. The pain recur at intervals from 5 minutes to 30 minutes, between which the infant may act completely normal and may even sleep, but as the symptoms recurs, the baby appear so exhausted, dehydrated, lie still and moan. [5, 6, 7, 8]

The vomiting at some stage is almost universal consisting of undigested food initially and later becomes bilious secondary to intestinal obstruction vomiting is presenting sign in only (29%) of cases [6, 7], as result, initial symptoms can be confused with gastro enteritis. As symptoms progress increasing lethargy develop [4, 9]. Few or normal bowel movement may result initially from the straining as evacuates distal to the obstruction but later the stool may be described as red current jelly which is caused by excess mucus production from the intussuscepted intestine that is mixed with blood from the congested veins in the intussuscepted intestine. The blood in stool may initially be found only on rectal examination (53%) [6, 7]. these symptoms vary in their intensity, but pain, as indicated by the attack of intense crying with vomiting, should never be considered as a simple colic even though the baby does not appear ill, as the trial of pain, vomiting and bleeding per rectum is only present in one third of patient and one child in ten will have diarrhea before the signs and symptoms of intussusception become obvious, this is the cause of delay in diagnosis potentially serious consequences [6].

Occasionally, the initial presenting sign is lethargy or altered consciousness alone, without pain, rectal bleeding, or other symptoms that suggest an intra abdominal process. This clinical presentation primarily occur in infants and is confused with sepsis, thus, intussusception should be consider in the evaluation of otherwise un explained lethargy or altered consciousness, especially in infants [9] physically the vital sign are usually normal early in the course of the disease, but as abdominal distension and vomiting continue, there is fluid loss which cause tachycardia and fever, and eventually either hypovolemic or septic shock or both [3, 7]. The classical finding is emptiness in the right lower quadrant due to progression of cecum and iliocecal portion of the intussusception into the right or transverse colon, also there is a curved or sausage. Shaped mass may be found any where in the abdomen, which is curved because it is tethered by the blood vessels in the mesentery on one side, the mass may pass to the descending colon or to the rectum where it may be felt on mass, An area of tenderness deep to the rectal muscle may be noted on, the presence of bloody

mucus on the finger as it is with drowns after rectal examination support the diagnosis of intussusception^[3].

On rectal examination, blood stained mucus or blood may be encountered, palpation of intussusception mass on bimanual examination is possible,^[6, 7] prolapsed of the intussusceptum through the anus is a grave sign specially when intussusceptum is blue or black in color and the greater danger come from miss diagnosis reduce it as a small rectal prolapsed, paid a particular attention to the infant's facial expression, during the spasm the baby generally had anxious look (babies with intussusception do not smile)^[5,7].

Diagnosis:

A high index of suspicion coupled with early diagnosis of intussusception may obviate the need for surgical intervention. For patient in whom the diagnosis is unclear at presentation, initial work up may include abdominal plain Film or abdominal ultra sound, provided that these studies do not significantly delay the definitive diagnosis and treatment of intussusception^[9].

A-Abdominal plain Film

The finding on abdominal plain Film are of limited usefulness, but are often performed as part of the evaluation of patient with abdominal symptoms, abdominal plain x-ray may reveal

I- dilated loops of bowel.

II- air fluid level in the presence of bowel obstruction.

III- pneumoperitonium if perforation has occurred.

IV- sparse large bowel gas.

V- abnormal distribution of gas and fecal contents.

VI- a target sign, consisting of two concentric radiolucent circle superimposed on the right kidney, represents peritoneal fat surrounding and within intussusception.

VII- A soft tissue density projecting into gas of large bowel (representing the intussusception) is called the "Crescent Sign".

VIII- Absence of gas in the right iliac fosse and upper quadrant The presence of air in the cecum or terminal ileum can help to exclude intussusception in patient with low clinical suspicion of the disease^[10,11].

b- Ultra sonography

The sonographic pattern of intussusception was first reported 1977. Ultra sonography is the method of choice to detect intussusception in many institutions the

sensitivity and specificity of this technique (97%-100%) in the hand of experienced ultra sonographers.^[12]

The ultra sonographers may reveal;

1-Mass measuring 2.5-5 cm in diameter and most are found in the right side of the abdomen ^[13].

2-The target sign or doughnut sign is seen on transverse section and consist of two rings of low echo density separated by a hyper echoic ring.

3-The pseudo kidney sign or sandwich sign is seen on longitudinal section and appear as a superimposed hypo echoic and hyper echoic layer, this pattern represent the edematous wall, of intussusception.

4-In addition the presence of free fluid trapped between the colon and the intussusception and / or enlarged lymphoid tissue or lymphoid may be seen within mass, has been associated with lower success rate of reduction.

5-Peritonic which is the one major contraindication to attempted reduction can be diagnosed by ultra sound.

6-Ultra sound can detect pathological lead point Doppler examination should be used to evaluate the vascularity of the intussusception, as poor vascularity may be associated with infraction of the bowel ^[14, 15, 16].

C-Diagnostic enema.

Barium enema was the gold standard for diagnosis of intussusception until mid 1980 when it was established that ultra sound could accurately diagnosis the condition. Around the same time it was also recognized that air could be used both to diagnosis and treat intussusception. Clinical sign's of dehydration or hyperemic shock, peritonitis and perforation are absolute contraindication to air or contrast enema, both diagnostic and therapeutic. The classical signs of intussusception on contrast enema a

1-The meniscus sign where the apex of the intussusception project into the contrast material.

2-The coiled spring which is produce when small amount of contrast material accumulate between the intussusceptum and intussusceptions, barium enema may be used to diagnosis the presence of ileocolic forms, but would be negative for the ileoileal variant in the presence of competent ileocecal valve^[17]

D-Computed Tomography and magnetic resonance imaging

These modalities are reserved for evaluation of selected patient in whom an a typical sono graphic appearance suggests a pathological lead point such as lymphoma ^[18].

Intussusception has been described on CT image as an intraluminal mass with characteristic layered appearance or fat or both within the mass or in continuity with adjacent mesenteric fat ^[1, 7].

PATIENTS AND METHODS

Patients aged 3mo-5yr with signs and symptoms consistent with intussusception admitted to Al-Zahra's teaching hospital in An-najaf city from the 1st Jan.2009 to the 31st of Dec.2010. History was taken from their family including name, sex, age, duration of symptoms, date of admission clinical manifestation (Abdominal pain, vomiting, bloody stool), neurological symptoms (lethargy, convulsion, fluctuating consciousness), past surgical history. System examination was done focusing on the presence abdominal mass, also digital rectal examination (PR) was done looking for the presence of bloody mucus (current jelly stool).

Erect plain abdominal x-ray was done in all patients, by {SHMADZN X-RAY} made in Japan, dose of radiation was 10Rad/60Kv, model R-20J N0.G100M1, U/S was done in all patients by use {LOGIQ ALPHA 200}, pediatrics probe 7.5Mhz, No.2205674 to detect abdominal mass, peritonitis, and underlying pathology. Barium enema and Abdominal CT-scan was not performed for any of these patients.

Any patient suspected of having intussusception is considered as an emergency, clinical evaluation and assessment is performed, all patients were given intravenous fluid to correct their fluid loss with cross-matched blood prepared and when his clinical condition improved, sent for theater.

Data was processed using Chi-square test at 0.05 level of significance $value < 0.05$ was considered statistically significant.

RESULTS

1. Age distribution

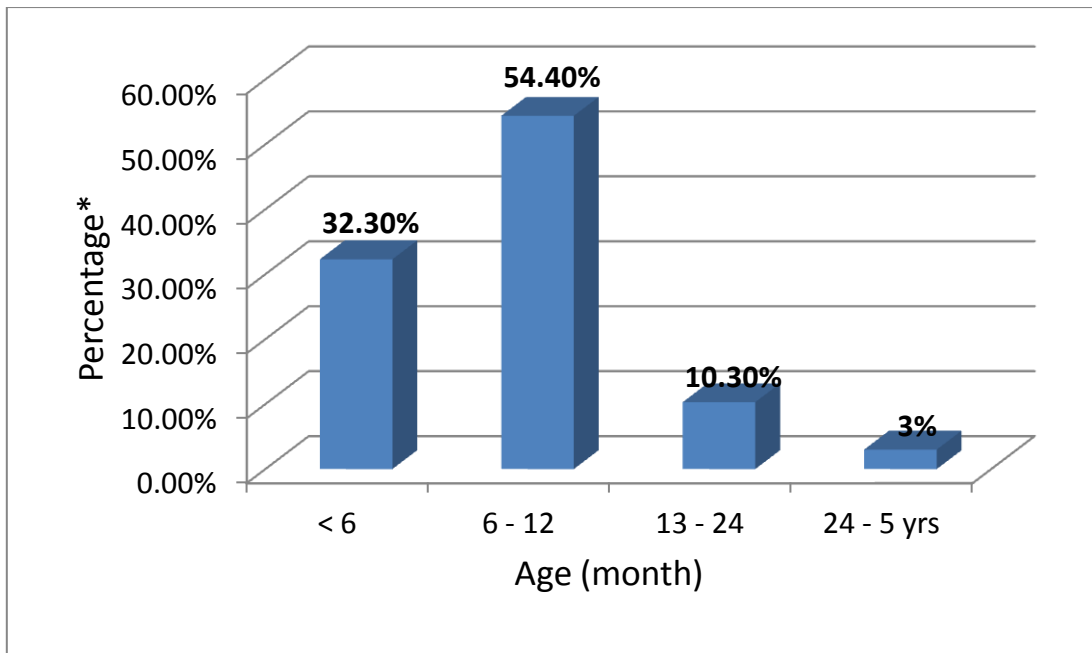


Figure 1: the age distribution of 68 children with intussusception.

2. Gender distribution

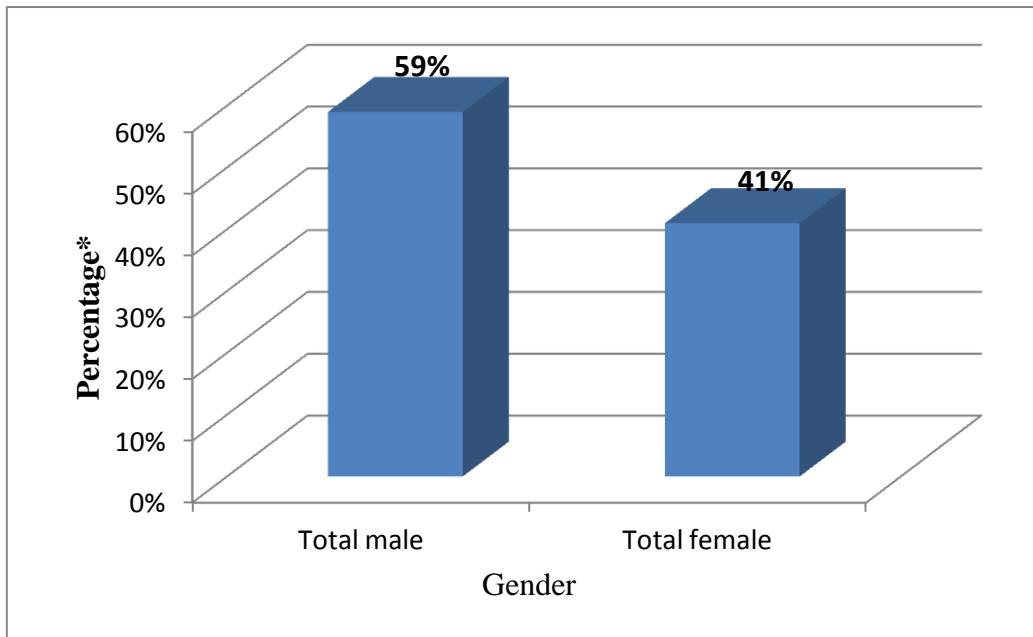


Figure 2: the age distribution of 68 children with intussusception

4. Duration of symptoms

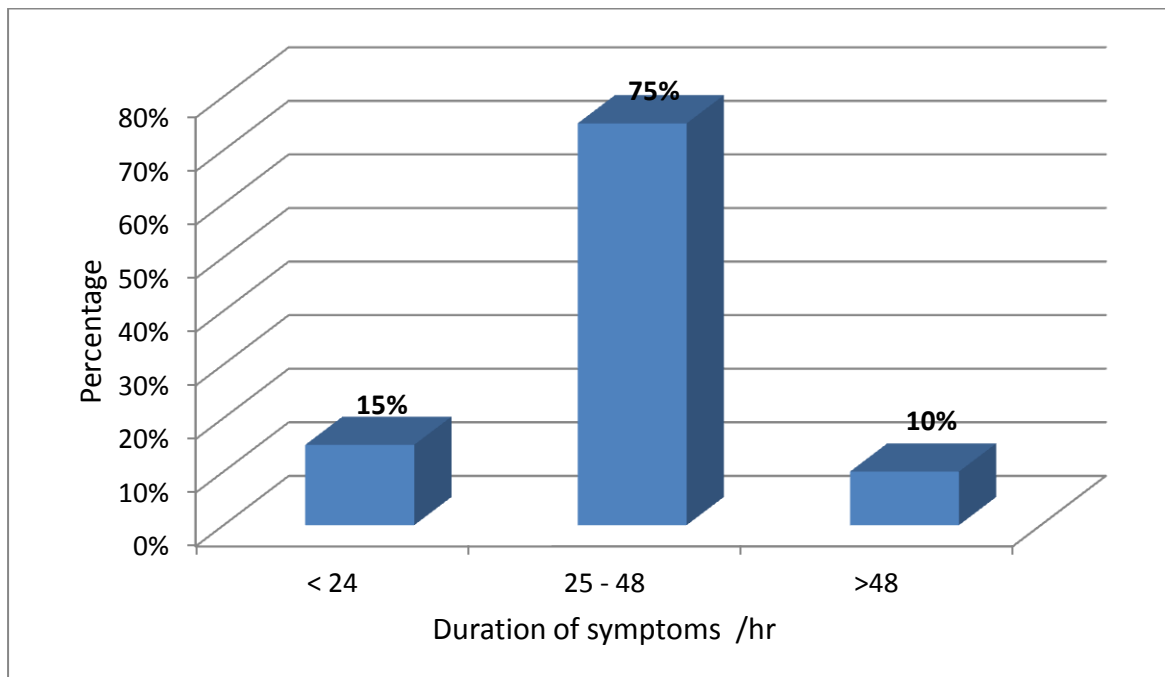


Figure 3: duration of symptoms in 68 patients with intussusception.

Clinical Features

i. Gastrointestinal symptoms:

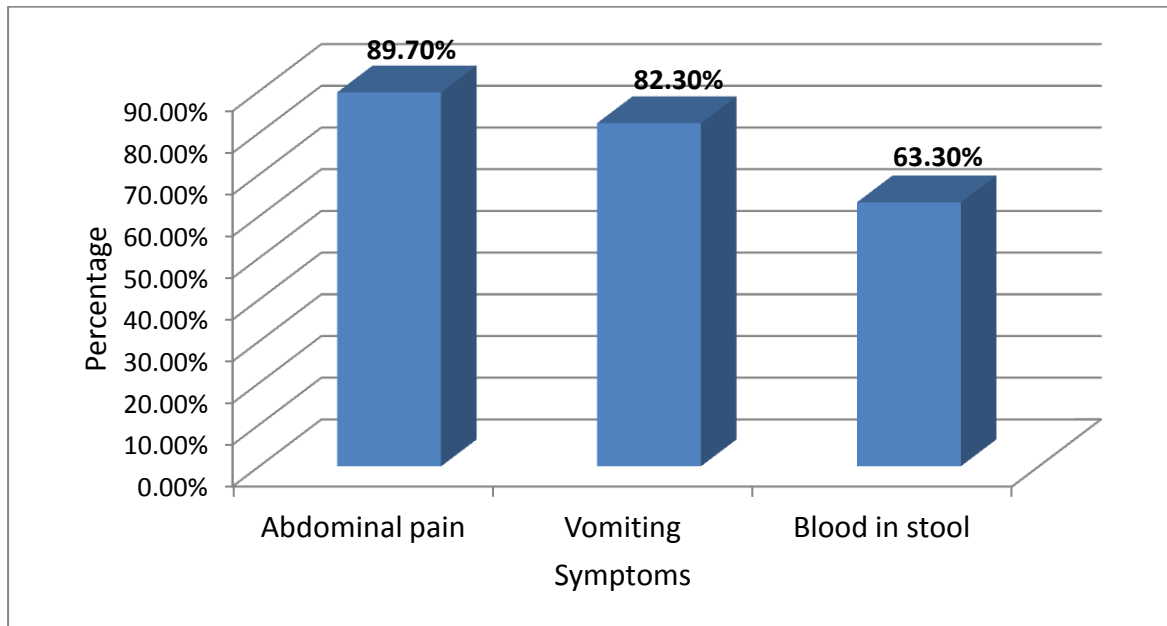


Figure4: Gastrointestinal Symptoms in 68 patients with intussusception.

ii. Neurological symptoms

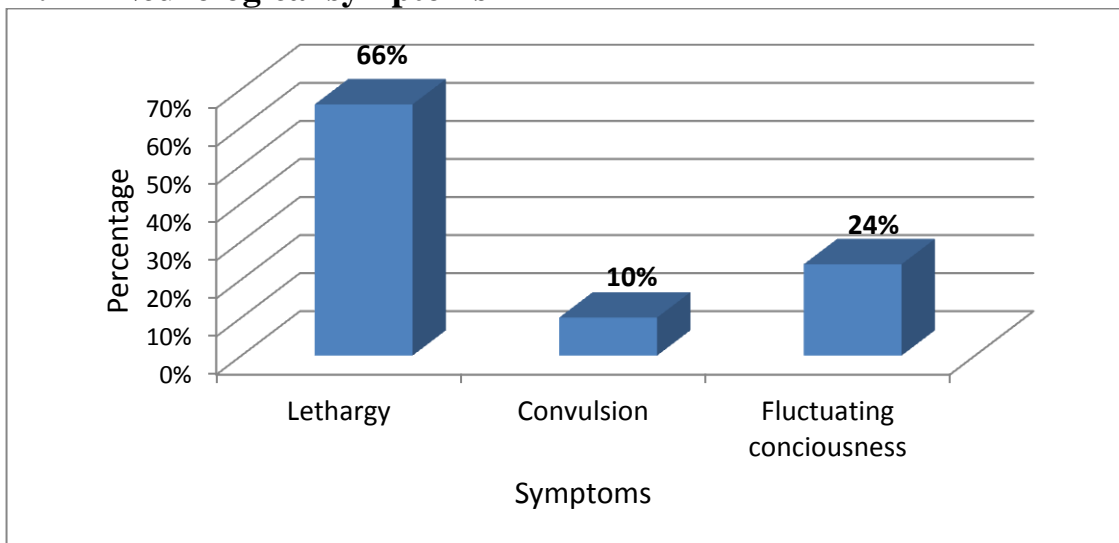


Figure5: Neurological symptoms in 68 patients with intussusception.

Table(1): clinical manifestation of children with intussusception in relation to their age.

Symptoms		Age (Months)				P. Value
		<12		>12		
		No.	%	No.	%	
Abdominal pain	present	53	87	8	13	> 0.05
	Not present	6	86	1	14	
Vomiting	present	49	87.5	7	12.5	> 0.05
	Not present	10	83	2	17	
Blood in stool	present	38	88	5	12	> 0.05
	Not present	21	84	4	16	
Lethargy	present	12	86	2	14	> 0.05
	Not present	47	87	7	13	
Convulsion	present	2	100	---	---	> 0.05
	Not present	57	86	9	14	
Fluctuating consciousness	present	4	80	1	20	> 0.05
	Not present	55	88	8	12	

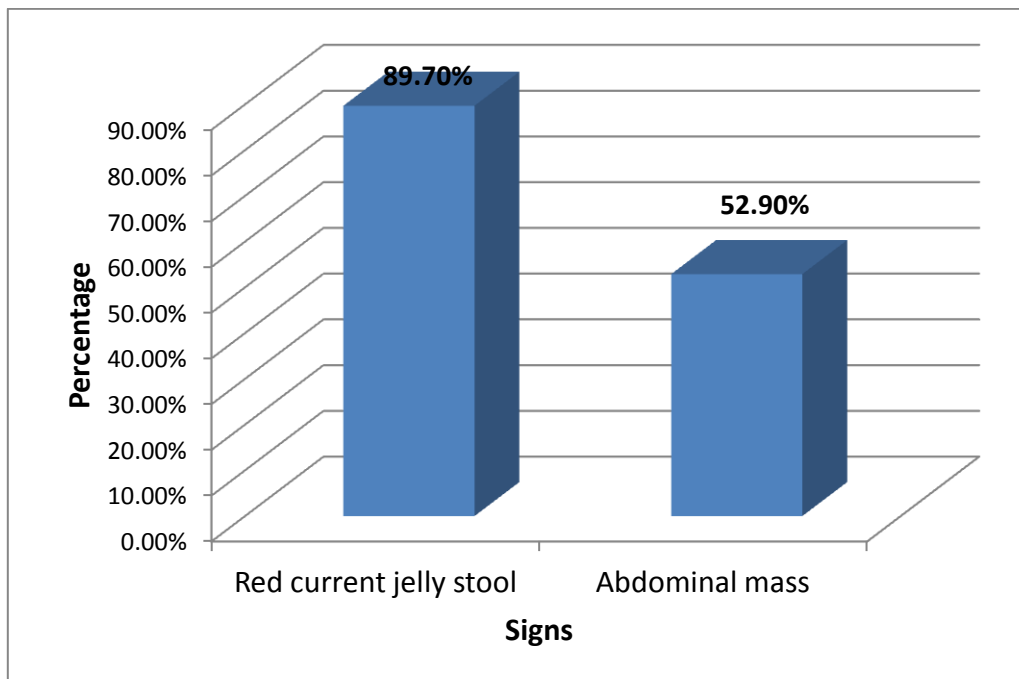


Figure 6: signs at presentation in 68 patients with intussusceptions.

3. Time distribution

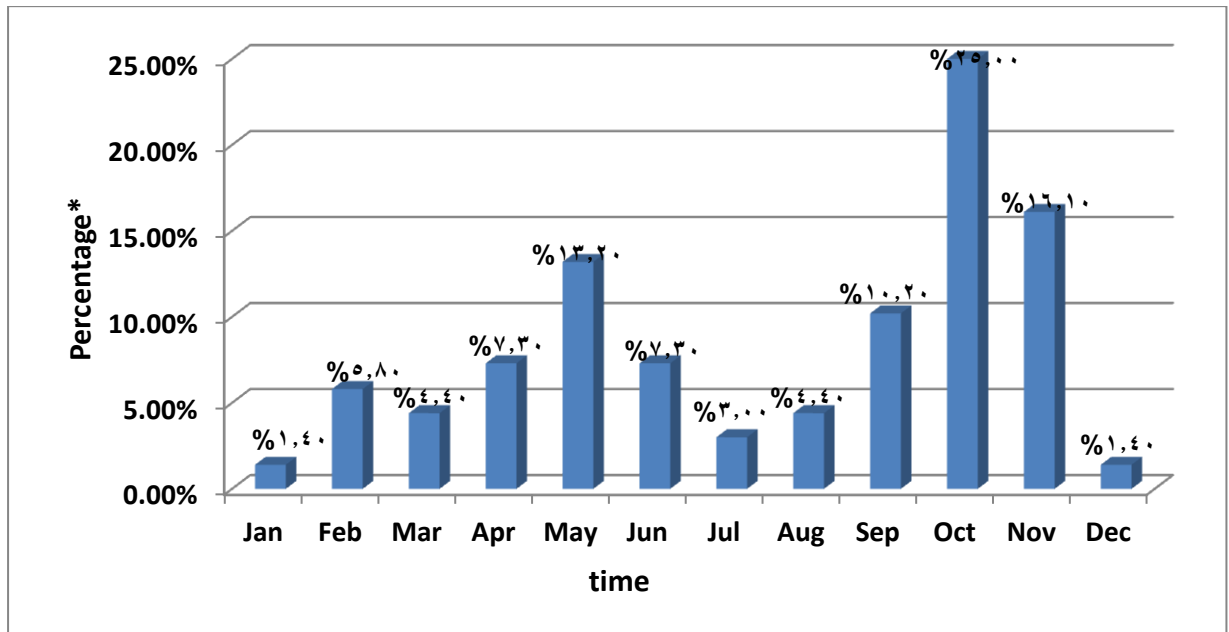


Figure 7: time distribution in 68 patients with intussusception.

DISCUSSIONS

This cross sectional study shows that the age at presentation varied from one month to five years, was higher among children between 6-12 months of age, this is similar to the result gained from previous study done by M.K. Al-Sultan^[19], and I.R. Al-Hadithi^[20]. This may be explained by the assumption of that introduction of new food proteins results in swollen payer patches in terminal ileum⁽²¹⁾.

There was a male predominance with male to female ratio 1.4:1, this is less than the finding of D.A.R. Mohammad (2.3:1)^[19], but similar to that of I.R. Al-Hadithi (1.4:1)^[20].

In this study, the peak time incidence was at October month 17(25%) followed by November month 11(16.1%), this is similar to result gained by D.A.R Mohammad⁽¹⁹⁾. This may be explained by correlation with prior or concurrent respiratory adeno virus (type c) infection has been noted⁽³⁾

Most of patients (64.8%) presented with symptoms within 25-48 hours which is similar to William H. Snyder^[22], who reported a presentation within the first 28 hour, but differ from other studies in which the majority of their patients presented within the first 24 hours^[19,20,21], with significant relation between age and time of presentation as shown in figure 3. This delay in presentation may be due to the variability of signs and symptoms, lack of awareness of the attending practitioners or delay in transporting the patients to our center.

Clinical manifestation:

In the study (89.7%) of patients presented with Abdominal pain (screaming attacks, with drawing up the knees), the vomiting presented in (82.3%) of patients, these are similar to that found by D.A.R Mohammed^[19]. but slightly lesser than M.K. Al-Sultan who reported (94.8% and 85.9%) respectively^[20], lethargy was recorded in 14 (66%), convulsion 2 (10%) and fluctuating consciousness 5(24%), these **neurological symptoms** is somewhat lower than the reported percentage in different studies^[24.].

Several hypotheses on the cause of neurological symptoms have been proposed, the absorption of toxic metabolic product from a strangulated bowel, the releases of neuropeptide, dehydration and electrolyte imbalance as a result of vomiting and bowel obstruction and a reflexogenic nature have all been suggested^[25], children with neurological symptoms statistical younger (less than 12mo. Of age).Table(1).

Red current Jelly stool on rectal examination was present in (89.7%),this is higher than was found by D.A.R. Mohammad^[19] (81.3%) but it is approximate to M.K. Al-Sultan (91%)^[20].the high incidence of red current Jelly may be due to a delayed presentation of our patients. Red current Jelly stool detected in 55(90%)of patient were under 12 month, while was 6(10%) more than 12 month age, this value indicate that with younger patient (12 month) it more likely to find red current Jell stool, significant relation with age.

Regarding Abdominal examination, abdominal mass was palpable in 36(64.7%) of patients, which similar to D.A.R Mohammad study (64.4%)^[19], but less than M.K Al-Sultan study (84.6%)^[20].Abdominal mass was found in 31 (86%) of cases were under 12 months, this value indicate that with younger patients (<12 month)it is more like to found mass, but no significant relation with age.

Diagnosis:

Radiographic study with plain abdominal film was done in all(100%) of the patients, but it was inconclusive in most cases, and contrast study was not done in any of our patients, this differ from the study done by D.A.R Mohammad who found it to be diagnostic in (23.6%)of his cases^[19].

U/S was done in all (100%)of patients and it was positive in 63(93%), this slightly lower to M.K. Al-Sultan result as appositve U/S in (96%) of cases^[20], which may be due to technical or personal cause, as both depend mainly on the person

interpretation them in addition to the technique and the type and model of device used..

CONCLUSIONS

- 1- Intussusception should be considered in the differential diagnosis in young children presenting with lethargy, convulsion and/or sudden alteration of consciousness even in the absence of one or more classical symptom of
- 2- Intussusception is more common in boys than girls.
- 3- Triad of Abdominal pain, vomiting, blood in stool are commonest presentation.
- 4- Ultra sound is useful method in diagnosis of intussusception.
- 5- Surgical reduction is the only treatment used in our hospitals.

RECOMMENDATIONS

- 1- Every pediatrician should keep intussusception in his mind, as early diagnosis and prompt treatment improves outcome and decrease mortality.
2. Intussusception should be consider in the differential diagnosis in young children presenting with lethargy, convulsion and/or sudden alteration of consciousness even in the absence of the classical symptom of intussusceptions.

REFERENCES

- 1- Charles V. Mann, R.C.G, Russel and Norman S. William: Bailey and loves short practice of surgery, 24th edition, 2005;2: 1194-96.
- 2- Lewis Spitz and Arnold G. Coran, Rob and Smith's operative surgery, pediatric surgery, 5th edition, 1995: 396-98.
- 3- Wyllie R I Ileus, Adhesions, Intussusception, and closed loop obstruction. In: Klieg man MR, Behram ER, Jenson BH, ET, al. Nelson text book of pediatrics 18th edition. Philadelphia, Elsevier Inc; 2007; 330: 1569-70.
- 4- Wyllie R.I Ileus, Adesion, Intussusception, and closed loop obstruction. In: kliegman MR, Behram ER, Jenson BH, et al. Nelson text book of pediatrics 18th edition. Philadelphia, Elsevier Inc; 2004; 2004 314: 1241-43.
- 5- John G. RaffinPerger, MD, Swenson's pediatric surgery, 5th edition. 1990 221-
- 6- James A.O. Neill Jr: intussusception, pediatric surgery, 1998, 4th edition 2: 1182-85.
- 7- Mary E. Fallat, MD, Keith W. Ashcroft, intussusception ch.38, pediatric surgery, 4th edition 2005: 533-38.
- 8- Crystal P, Hertzanu Y, Farber B, et al: Sonographically, guided hydrostatic reduction of intussusception in children. J Clin ultrasound 2002; 30; 320-21.

- 9- Kitagawa MD, Midady M d. intussusception in children in: Alison G,
- 10- Eur,pediatricsurgry 2008,122:512
- 11- Buettcher M, Baer G, Bonhoeffer J, et al. three –year surveillance of intussusception in Switzerland. Pediatrics 2007; 120:473.
- 12- West KW, Caros Feld JL.Intussusception. In: Wyllie R, Hyams JS. Pediatric Gastro intestinal disease: Patho physiology, Diagnosis, Management, Philadelphia 1999.p.427.
- 13- 12-Guarner J, de leon-Bojorge B, Lopez-corella E, et al. intestinal intussusception associated with adenovirus infection in Mexican children.Am J Clinpathol 2003 120:845.
- 14- Bines JE, Liem NT, Justice FA, et al. Risk factor for intussusception in infant in Vietnam and Australia.
- 15- Judith M. Sondheimer, MD, current pediatric Diagnosis and treatment Gastro intestinal tract, 14th edition, Appleton and Lange, 2008: 539.
- 16- Navarro O. Deneman, A. intussusception. Part 3.Diagnosis and management of those with an identifiable or predisposing cause and those that reduce spontaneously. Pediatric Radiol 2004; 34:305.
- 17- ST-Vil D, Brandt ML, Panics S, et al. Meckl'sdiverticulum's in children: a 20 year review. J Pediatric Surgery 1991; 26:1289.
- 18- Majid k. Al-Sultan, the use of air insufflations in the management of intussusception, a study of 78 cases, Iraq, 2004:33-38 (thesis).
- 19- Mohammad D.A.R., intussusceptions in childhood a study of 76 cases, Iraq, 2007:39-45 (thesis).
- 20- Majid k. Al-Sultan, the use of air insufflations in the management of intussusception, a study of 78 cases, Iraq, 2004:33-38 (thesis).
- 21- Al-Hadithi I.R.,intussusceptions, a study of 160 cases, Iraq, 2005:15-19 (thesis).
- 22- William H. Snyder, Jr,Alfred R. Kraus and Lawrence chaffin, intussusceptions in infant and children, A report of 143 consecutive cases, Annals of surgery, 1999 August:200-210.
- 23- Al-Malki: TA. Pediatric intussusceptions in a Saudia Arabian Tertiary hospital, West Afr J Med 2005, 24:309-10.
- 24- Pumberger W, Dinhobli,DremsekP.Alterd consciousness and lethargy from compromised intestinal blood flow in children. Am J Emerg med 2004; 23: 307.

25- Kaiser AD, Applegate KE, Ladd AP, current success in the treatment of intussusceptions in children. *Surgery* 2007;142:469-77.