

Morphometric Comparative Anatomical Study Of Lower Respiratory Tract Between Sheep(*Ovis aris*) And Goat(*Caprus hircus*) in Baghdad provence

Noor Hussein Yousif¹ Dr. Mohammed Sulaiman Dawood²

University of Baghdad /College of Veterinary Medicine

Email: husseiny620@gmail.com

Received date:10Nov2019 Accepted:(457) 25Nov2019 page (26-36) Pubished:31Dec2019

DOI: <https://doi.org/10.36326/kjvs/2019/v10i23311>

Abstract

Authors describe the lower respiratory tract between sheep (*Ovis aris*) and goat(*carpus hircus*) by involved five adult male sheep and goats to investigate the anatomical features of lower respiratory tract in indigenous sheep and goat. The samples of the lower respiratory tract were collected from Baghdad slaughter house the external feature trachea and lung deals with the shape, weight, relationship, ligamentation and position of the lower respiratory tract. The trachea in both species was long flexible hollow tube with uncompleted cartilagenous rings were situated in the median line of cervical region ventrally, trachea was showed started from the first tracheal ring cartilaginous with the cricoids cartilage of the larynx. trachea was composed of two regions airway; cervical and thoracic, the tracheal ring shape were C shape in goat and U shape in sheep, the numbers of tracheal rings in sheep and goat were 49.2 ± 0.37 , 51.2 ± 0.47 , respectively. The total mean length of the right and left main bronchi in both sheep and goat were 2.26 ± 0.092 cm, 2.10 ± 0.077 cm, 2.12 ± 0.037 cm, 1.96 ± 0.005 cm, respectively. The total mean tracheal length in both sheep and goat were 30.4 ± 0.50 cm, 24.7 ± 0.34 cm, respectively. The lungs of both animals look like spongy soft organ, surrounded the heart which was located in the mediastinum and enveloped by visceral and parietal pleura. The lung of both animals have anterior apex and posterior base, lung composed right and left lobe the right apical lobe subdivided into cranial and caudal part while undivided in goat, both animals left lung composed of apical and caudal lobe, the apical was subdivided into cranial and caudal part .

Keywords: lower respiratory tract, trachea , lung , apical lobe

دراسة تشريحية مقارنة في الجزء السفلي للجهاز التنفسي بين الاغنام والماعز

نور حسين يوسف

محمد سليمان داود

فرع التشريح والانسجة في كلية الطب البيطري / جامعة بغداد

الخلاصة

تضمنت هذه الدراسة لإظهار الخصائص التشريحية والشكلية في الجهاز التنفسي السفلي في الأغنام والماعز ، وقد استعملت خمس من ذكور الأغنام والماعز البالغه والسليمة . تم الحصول على الحيوانات من مجازر بغداد. اظهرت النتائج في القصبة الهوائية في كلا النوعين تكون على شكل أنبوب مجوف طويل مرن مع حلقات الغضروفية غير المكتملة تقع في خط الوسط لمنطقة العنق البطنية ، وقد تبين أنها تبدأ باتصال حلقة القصبة الهوائية الغضروفية الاولى مع الغضاريف الحلزونية في الحنجرة. تنقسم القصبة الهوائية إلى منطقتين : العنقية والصدرية ، وكان شكل حلقة القصبة الهوائية على شكل حرف C في الماعز و U في الأغنام ، وعدد حلقات القصبة الهوائية في الأغنام كانت (49.2 ± 0.37 ، 51.2 ± 0.47) على التوالي .

كان متوسط الطول الكلي للقصبات الهوائية الرئيسية اليمنى واليسرى في كل من الأغنام والماعز (0.077 ± 2.12 سم ، 0.037 ± 1.96 سم) على التوالي ، إجمالي متوسط طول القصبية الهوائية في كل من الأغنام والماعز كانت (30.4 ± 0.50 سم) ، (24.7 ± 0.34 سم) على التوالي. بينما اتضح ان الرنتان في كلا الحيوانات كانت على شكل عضواً ناعماً إسفنجياً ، يحوط القلب الموجود في منتصف الرئ ويغلفها غشاء الجنب الحشوي والجداري ، ولها لون أحمر قرنفلي وتملأ التجويف الصدري ، ورئة كل من الحيوانات لها ثلاثة أسطح . السطح الساحلي ، وسطي ضيق السطح وسطح الحجاب الحاجز كبير (السطح القاعدي).

واحتوت الرئة في كلا الحيوانات على قمة خارجية وقاعدة خلفية ، وله ثلاثة حدود ظهرية ، بطنية وقاعدية ، بها عدد من الفصوص المنسقة مفصولة بشقوق عميقة بوضوح وكانت الرئة اليمنى مكونة من فصوص قمي ، وسطية ، اضافي وفص ذيلية ، ينقسم الفص القمي في الاغنام إلى جزء من امامي وخلفي اما في الماعز الفص القمي غير مقسم ، اما الرئة اليسرى في كلا الحيوانات مكونة من فص قمي ذيلي (خلفي) ، وقد تم تقسيم الفص القمي إلى جزء امامي و خلفي . واستنتج من هذه الدراسة ان الجزء السفلي للجهاز التنفسي في الاغنام اكبر حجم واكثر كفاءة من الماعز .

الكلمات المفتاحية : الجهاز التنفسي ، القصبية الهوائية ، الرنتين ، الفصوص الرئوية

Introduction :

The respiratory system is a vital organ play an important role in respiration called ventilation system. This system limited of gases exchanging via the respiratory construction and outside atmosphere ⁽¹⁾. The olfaction, vocalization and body temperature regulation regarded another respiratory activation beside the ventilation which consisted of gases exchange and conduction ⁽²⁾.

Aims of this study to be a source of anatomical data for lower respiratory system of indigenous sheep and goat, to be a source comparison with other animals by investigating the Anatomical features of the trachea and lower respiratory track with boundaries and all anatomical structures that surround them in sheep and goat.

The mammalian respiratory system consisted of numerous anatomical structures which classified as conducting and respiratory part, the first one nasal cavity, nasopharynx, larynx, trachea and bronchi, however the second bronchioles, alveolar ducts and alveoli which were responsible for gas exchanging. The distribution of the air and blood in a wide space via large exact network of air way and blood vessels will assist the gas exchanging ⁽³⁾. observed that the wall of trachea was consisted of four layers in most domestic animals, which

were pseudostratified columnar epithelial mucosal layer, submucosa, muscularis and adventitia. Incomplete hyaline cartilaginous ring supports these layers⁽⁴⁾. The conducting and respiratory parts posse's different anatomical features among species and same individuals, this will be useful for veterinarian ⁽⁵⁾. The mammalian air ways dimensions and shape will be affected by many tracheal disorders that causes modification in compliance and shape of trachea that will be affected on the tracheal responsibility for air flow changes, for example tracheal collapse ⁽⁶⁾. The morphometrical studies of the lung and trachea are very useful due to the vital role of trachea during breathing and intubation processes during general anesthesia ⁽⁷⁾.

Material and method :

The study conducted was prepared to demonstrate the anatomical features, lower respiratory tract in the sheep and goat, five healthy adult (one year) male sheep and goat which about 15 ± 0.50 Kg were used. The animals were obtained from (slaughterhouse in Baghdad). Five animals slaughtered . The external feature trachea and lung deals with the shape, weight, relationship, ligamentation and position of the lower respiratory tract, The topography and the shape of the organs were recorded by digital vernia, ruler, electron balance and camera .Five of lower respiratory tract were

used in project, all of the lower respiratory tract with part of larynx and diaphragm were collected immediately from five animals, checked from disease or illness that may appear. Macroscopic measurements of the lower respiratory tract such as weight, volume, lobulation of lung, the tracheal length, rings numbering and depth diameter were measured .

Results

The General Anatomical Structure Trachea: These results of the present study showed that the trachea in both species (sheep and goat) were a long flexible hollow tube with uncompleted cartilagenous rings from dorsal side ,it was linked to each other by annular ligaments and trachealis muscle (Fig.1).

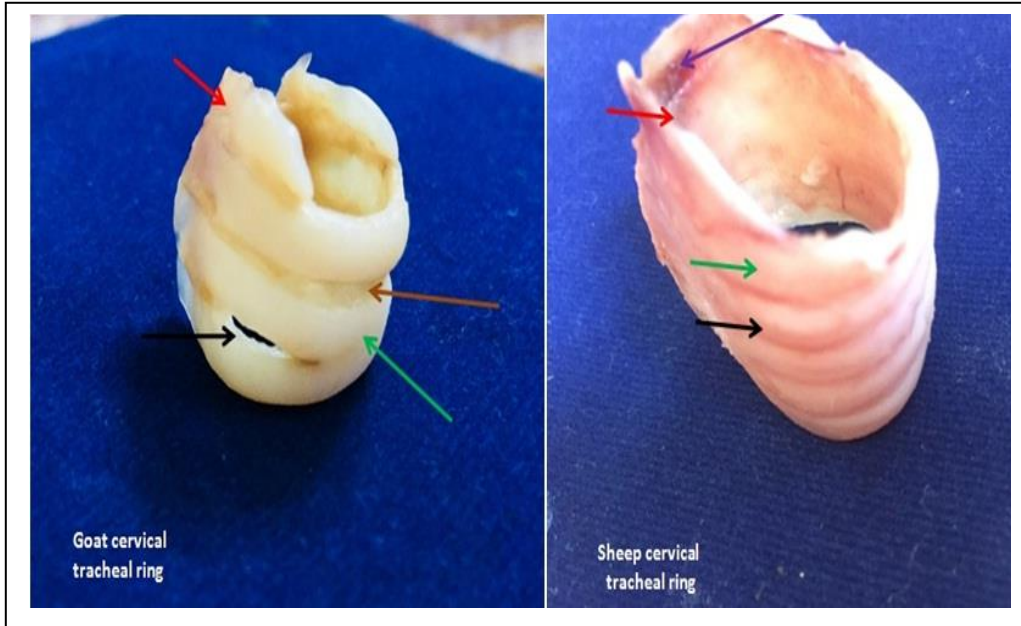


Figure 1: Anatomical view the trachea in sheep and goat :left show red arrow (cervical ring when attach with larynx) ,the brown arrow (annular ligament) ,the green arrow (fusion tracheal ring)and black arrow (the tracheal ring in cervical region) . right picture red arrow (cervical ring when attach with larynx) ,the black arrow (the annular ligament) ,the green arrow (tracheal ring) and purple arrow (the trachealis muscle) .

The trachea in both species were situated in the median line of cervical region ventrally ,it was showed started connected by first tracheal ring cartilagenous with the cricoids cartilage of the larynx , persistent in direction toward thoracic cavity that started from 2nd cervical vertebra and ended in 5th thoracic vertebra at the bifurcation where the trachea divided into two principle bronchi (right and left lobar bronchi) at transversal plane . The tracheal rings numbers in both

sheep and goat was 48 -49, 52-53, respectively (Fig.2).

Morphologically ,the trachea was composed to two regions pathway; cervical and thoracic region , cervical region extended from 1st tracheal ring which is continuous with cricoids cartilage and closed at the thoracic inlet inversion at the 1st rib, the cervical and thoracic number in both animals sheep and goat was between 28 - 29,20 , 32-33,20,respectively. (Fig 2).

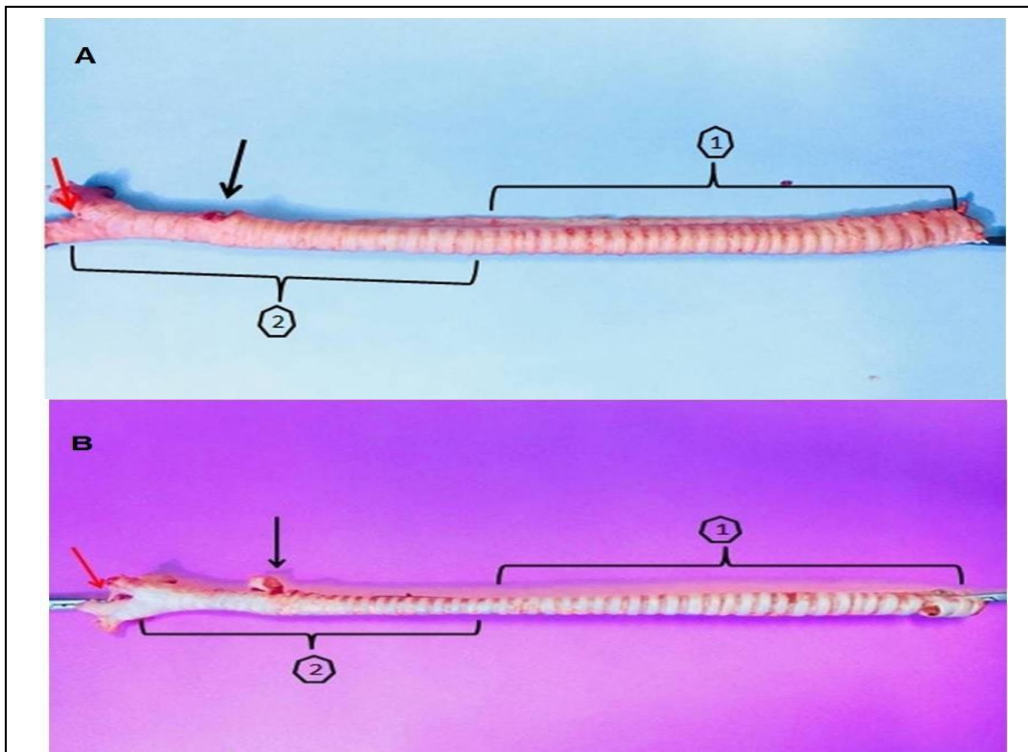


Figure 2 : Anatomical view the length of trachea in sheep and goat : showed the trachea of adult Sheep(A) & Goat(B) , No.1&2 the region of cervical and thoracic ,the red & yellow arrow (the bifurcation) and that black arrow (the tracheal bronchus) .

In the end of the tracheal path in transverse plane at 5th thoracic vertebra and in the base of the heart exactly on the left atrium the principle bronchi created (right and left bronchus). In sheep the cross section was showed that the lumen of the tracheal rings has U shape which was started from cervical ring and become semicircular C shape extended toward the

bifurcation while in goat the luminal cross section of the tracheal ring has semicircular C shape started from first cervical ring access to bifurcation (Fig. 3). The trachea of sheep have several fusions started from the tracheal bronchus to the bifurcation, while in goat fusions appeared dorsomedially at the first three cervical ring (Fig.3).

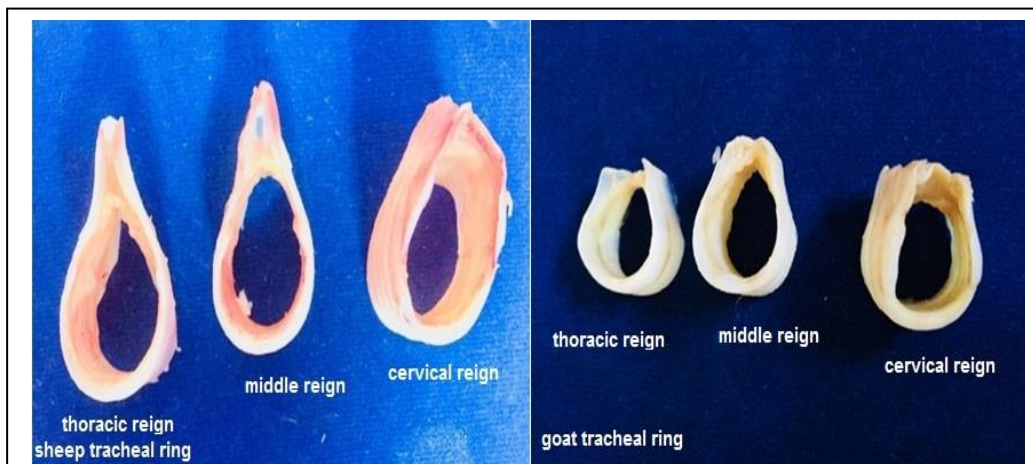

Figure3 : Anatomical view the different trachea in sheep and goat : left picture show the sheep tracheal region started U – shape from the cervical and became narrowing to C – sheep of the thoracic region access to bifurcation. ,right picture show the goat tracheal region start C – shape from the cervical to the thoracic region access to bifurcation.

Morphometric measurements results of trachea: the measurements of the total mean tracheal length in both sheep and goat were 30.4± 0.50cm, 24.7±0.34cm, respectively. This length divided between cervical and thoracic regions were 24.3±.153cm, 20.3±.185cm, 5.8 8 ± 0.124cm, 4.26±0.116cm, respectively (Table 1). The total mean length of the principle tracheal bronchus (additional) ramus before its bifurcation in both sheep and goat were 0.55 ±0.103cm, 0.9 ±0.051cm, respectively. While the total mean length from principle tracheal bronchus(additional) to the main

bifurcation in both sheep and goat were 3.28 ±0.102cm, 3.34± 0.040cm, respectively (Table 1). The total mean length of the right and left main bronchi in both sheep and goat were 2.26±0.092cm, 2.10±0.077cm, 2.12±0.037cm, 1.96±0.005cm, respectively. Also the total mean number of the tracheal rings which were divided between the cervical and thoracic tracheal rings in both sheep and goat were 49.2 ± 0.37, 51.2 ±0 .47, 28.0±0 .31, 32.0±0 .31, 21.6± 0 .40, 20.8 ± 0 .37, respectively (Table 1).

Table (1): Manifests the length of sheep and goat trachea, tracheal bronchus and principal bronchi n=(5)

Parameters	Sheep Mean ±Se	Goat Mean ± Se
Length of trachea (cm.)	30.4± 0.50 *	24.7±0.34
Cervical course length (cm.)	24.3±0.153 *	20.3±0.185
Thoracic course length (cm.)	5.8 8 ± 0.124 *	4.26±0.116
Length from cervical inlet to tracheal bronchus (cm.)	20.3±.086 *	16.2±0.120
Length from tracheal bronchus to bifurcation (cm.)	3.28 ±0.102	3.34± 0.040
Tracheal bronchus length (cm.)	0.55 ±0.103	0.9 ±0.051
Right bronchus length(cm.)	2.26±0.092	2.10±0.077
Left bronchus length(cm.)	2.12±0.037	1.96±0.005
Trachea ring number	49.2 ± 0.37	51.2 ±0 .47
Cervical rings number	28.0±0 .31	32.0±0 .31 *
Thoracic rings number	21.6± 0 .40	20.8 ± 0 .37

(*) Represents significant difference at (P>0.05).

The General Anatomical Structure Lung :The anatomical results illustrated that the lungs of both animals look like spongy soft organ, surrounded the heart which was located in the mediastinum and enveloped by visceral and parietal pleura, it have a pinkish red color and they were filled the thoracic cavity, consequently in situ ,lungs were showed bounded with thoracic wall cavity laterally while mediastinum and heart medially ,the apex of lung opposite the boundaries of the first and second rib cranially and the base of lungs extended to the 10th -12th ribs caudally while restricted between the sternum ventrally and thoracic vertebra dorsally . The lungs consisted of many lobes which are apical (cranial and caudal) ,middle caudal and accessory at the right side and the left consisted of apical

(cranial and caudal), caudal, in goat the right was similar of the sheep but the apical was undivided only two lobes ,cranial and caudal, these all lobes look like a semi cone shaped to correspond with the thoracic cavity (Fig.4&5), topographically the lung of both animals have a three surfaces; costal surface, medial narrow surface and large concave diaphragmatic surface (basal surface). Grossly, the lungs of both sheep and goat have a numbers of coordinated lobes separated by clearly deep fissures. In sheep the right lung was consisted of apical, middle, accessory and caudal lobes(Fig.4&5),the apical lobe subdivided into cranial and caudal part, the cranial part of apical lobe was extended through thoracic cavity (Fig.4&5).

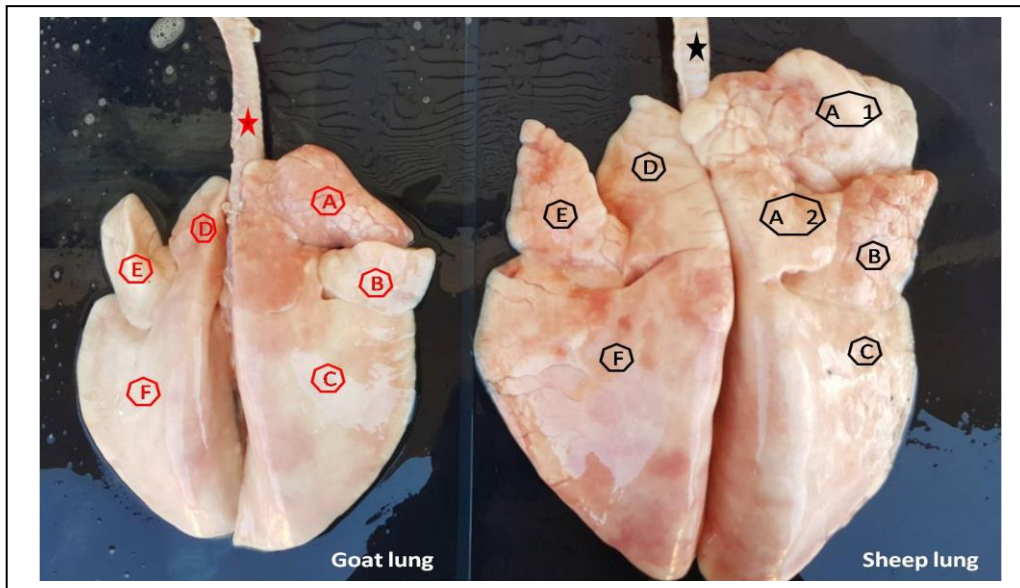


Figure 4: Anatomical dorsal view to sheep and goat lungs:

left picture show dorsal view to goat lung :

1-red astrik (the trachea)

2- A, right apical(undivided)lobe.

3-B , right middle lobe

4-C , the right caudal lobe of lung 5-D ,left apical (cranial part) lobe & E, left apical (caudalpart) lobe of lungs.

6-F, left caudal lobe of lungs.

right picture show dorsal view to sheep and goat lung :

1-black astrik (the trachea).

2- A1, right apical(cranial part) lobe and A2, right apical(caudal part)lobe of lung.

3- C, right middle lobe . 4-C , right caudal lobe of lungs . 5-D ,left apical (cranial part) lobe & E, left apical (caudal part) lobe of lungs.

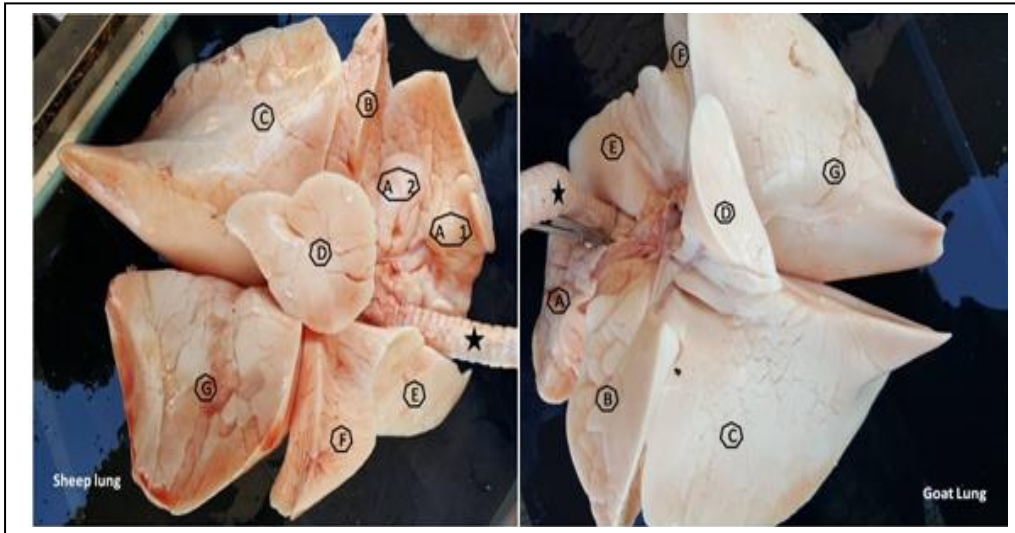


Figure 5 : Anatomical view the ventral view to sheep and goat lungs:

left picture show ventral view to sheep lungs :

- 1-black astrik (the trachea)
- 2- A1, right apical(cranial)lobe and A2 ,right apical(caudal)lobe of lung.
- 3- B, right middlelobe .
- 4- D,the accessory lobe of lung
- 5-C , right caudal lobe of lungs .
- 6-E, left apical (cranial) lobe & F, left apical (caudal) lobe of lungs.
- 7-G ,left caudal lobe of lungs.

right picture show ventral view to Goat lungs

- 1-black astrik (the trachea) .
- 2- A, right apical(undivided)lobe .

In goat, the right apical lobe was undivided but extended through thoracic cavity to hug the heart. The middle lobe was like the lance head shaped, the accessory lobe was a smallest lobe and look like a cone shape of convex base on the right side which occupied the medial surface between the caudal and middle lobe, the Caudal lobes in both lungs have trapezoidal shape, The left lung composed of apical and caudal lobe, the apical was subdivided into cranial and caudal part (Fig.4&5).

discussion:

The trachea regarded as the connection between the upper respiratory tract and lungs which is acts as a pass way for in and out air passage during the inspiration and expiration, The trachea has a

different ring shape, long and location among the most species. The result of the present study showed that the trachea in both species (sheep and goat) has a specific ring shape, number and position, the related adjacent near organ as well as the division of the trachea into cervical and thoracic and its total length, and a number of the two parts the numbers of tracheal rings in sheep and goat were 49.2 ± 0.37 , 51.2 ± 0.47 , respectively. The total mean length of the right and left main bronchi in both sheep and goat were 2.26 ± 0.092 cm, 2.10 ± 0.077 cm, 2.12 ± 0.037 cm, 1.96 ± 0.005 cm, respectively. The total mean tracheal length in both sheep and goat were 30.4 ± 0.50 cm, 24.7 ± 0.34 cm, respectively . Data were obtained is confirmed with ⁽⁸⁾⁽⁹⁾⁽¹⁰⁾. in pig recorded a deferent data that associated with tracheal

course and position ⁽¹¹⁾, but ⁽¹⁰⁾ in adult gazelle declare many differences about the morphometric measurements, showed that the trachea had mean total length about 29.79 ± 0.26 cm divided by 16.79 ± 2.39 cm of cervical and 13 ± 0.18 cm of thoracic, the distance from thoracic inlet to the bifurcation was 7.29 ± 0.11 cm and from tracheal bronchus to the bifurcation was 5.29 ± 0.11 cm. The length of tracheal bronchus, left and right bronchus were 0.87 ± 0.03 cm, 1.58 ± 0.03 cm, 1.46 ± 0.02 cm, respectively. The trachea was of many fusions especially in the last of cervical. In a cross-section, the luminal pubic shape appeared and the tracheal rings illustrated as semicircular to the oval at the cranial part while c-shape at the middle and caudal thirds. The tracheal bronchus was subdivided into two main separated branches (dorsal and ventral). Meanwhile in Arabian oryx (*oryx leucoryx*) stated another information that associated with tracheal length, diameter and ring number which were 54.1 cm, 22mm, 50-51, respectively (7). As well as demonstrated that the length and number of the trachea in sheep and goat were 26.5-31 cm, 24.5-29cm, 51-55, 49-53, respectively ⁽¹²⁾. These results were unlike with the present study. in Angora goat revealed similar data of the goat that associated with number and length with goat but not confirmed with data of sheep ⁽¹³⁾, mean while in European goat showed that the tracheal rings like U shape in cross-section with same level ending but in sheep he showed that the outline of the tracheal ring were cylindrical while in the present study the U shape was started from cervical ring and become semicircular C shape extended toward the bifurcation while in goat the luminal cross-section of the tracheal ring has semicircular C shape with the same level, ⁽¹⁴⁾. in Sokoto goat described U shape tracheal rings, the declared 50-55 ring number this result where confirmed

with ring number of goat in the present study, but differ from the sheep ⁽¹⁵⁾. described a rounded shape trachea with overlapping architecture by two ends ⁽¹⁶⁾. Also in goat revealed that the tracheal length was about 25.7 cm and bronchus length in both side right and left were 1.04, 1.97cm, respectively ⁽⁹⁾. investigations in local sheep were confidence with the ring number but not agree with the length of the trachea in sheep whereas in goat were not trust with the two values (length and number) ⁽¹⁷⁾. On the other hand, in the cat have the same result of C shape tracheal ring in both animals except the change of the ring near the bifurcation in sheep only ⁽¹⁸⁾. While in camel recorded different categories associated with shape, the number and length of trachea similar has been formed in the present study ⁽¹⁹⁾. in human recorded a horseshoe or circular shaped tracheal ring with length and diameter of 10 -12, 10 cm, 25mm, 21mm in male and female, respectively ⁽²⁰⁾. These data was deferent with our result. In the past decade, in giraffe described a circular tracheal ring these rings were fused in a deferent situation, with length of 125cm and the number was 100 rings, these all information was not alignment with the present study in both animals this dissimilarities were due to the nature of the body and nature of animal environment ⁽²¹⁾. While in young Squirrel monkeys recorded a rounded tracheal rings in the upper part of trachea which weren't like the C and U shape tracheal ring in both animals also said the remaining rings were being oval at the middle and caudal part while in adult were flattened to oval, they revealed 30 ring of number that were unlike of our results ⁽²²⁾

The present study cope with the characteristic features of the organ like position, color, volumetric measurement, lobes number, surface, border and weight, many authors have a deferent opinions about

the organ like ⁽²³⁾, these authors described attachment of the organ with diaphragm by the pulmonary ligament, as well as with mediastinum, also showed that the right one is larger than the left because of extra lobulation. These investigations are parallel with the present study in both animals. ⁽²⁴⁾ have same results with the present study when described the lung hilus as central depression at the cardiac impression dorsally but not enclosed the pleura. The general description of the lung color of ⁽²⁵⁾ is pink which was depending on the blood perfuse, while in small ruminant observed a pink gray and gray blue, the information of these investigators were disagree with the present study ⁽²⁶⁾. The most general information of ⁽¹⁰⁾ in gazelle that associated with the color, position, attachment, lobulation and general features were resemble to the present study except some measurement that associated with the weight and volume which were differ from our data in both animals. in addition to ⁽²⁷⁾. in bovine stated un equal investigation about the left lung which described as undivided apical lobe opposite to the divided apical lobe in both sheep and goat while its description of the right lung was disagree of the goat ^{(28),(29)} in Holstein cattle left lung description agree with the prior author and stated accessory lobe was missing, on the other hand ⁽³⁰⁾. Stated that there are many fissures separated the lung lobe and the lobulation as being seen in the present study.⁽³¹⁾ in Formosan reeve's muntjac (*Muntiacus Reevesi Micrurus*) stated that lungs were deep fissured of the main lobe but the left were shallow fissured and missing accessory lobe, the right apical lobe was un divided, the data of these authors were in trust with the present study. In Red Sokoto goat described a pink color lungs that disagree with a color of the present study but divisions of lobes were similar to our result except missing of accessory lobe as we mention ⁽¹⁵⁾ .in adult

Baladi goats illustrated missing accessory lobe ⁽²⁶⁾ in carnivorous demonstrated a deep interlobar fissured lobes with equal lobulation number the result of ⁽³²⁾ was agree with the present study but ⁽²⁶⁾ was disagree with the present study rather than deep fissure separated lobes.⁽²²⁾ description of the human lung was deferent entirely of the present study when they illustrated oblique lobes and arrangement of lobes. While ⁽³⁴⁾ description of monkeys lung was similar to that of prior authors in the human-like arrangement of lobes except for the number of the left lung that was three lobes similar to the present study. in sheep have a same data about the lobe number of both lungs ⁽³⁵⁾, also ⁽²⁶⁾ in sheep and goat has similar information that related with the border, lobes shape and number. In the past decade in camels, showed that the lobes of lungs were separated by connective tissue, consisted of apical, diaphragmatic and accessory on the right side and apical and diaphragmatic on the left side, we are in agreement with these results ⁽¹⁹⁾. While the horse lungs were demonstrated by ⁽³⁶⁾ unlike with the present study, he said cranial and caudal lobes of both lungs were separated by cardiac notch and both lungs are approximately equal in size.

Conclusions

The efficiency of the male adult (one year) sheep lung better than the male adult (one year)goat lung due to excessive ramification in sheep than a goat. The apical right lobe of sheep was divided while in goat was not. The right lung of both animals was heavier due to the accessory lobe on the right side.

Reference :

1. Maton, A.; Hopkins, J. S.; Johnson, C. W.; McLaughlin, M. Q.; Warner, D. and Lahart Wright, J. (2010) Human Biology and Health. Englewood Cliffs: Prentice Hall. Pp: 108-118.
2. Baba, M. A. and Choudhary, A. R.

- (2008).Histo morphology of Pulmonary Alveoli of Goat (*Capra Hircus*). Division of Veterinary Anatomy and Histology. Faculty of Veterinary Sciences and Animal Husbandry. Veterinary world.Skuastk,Shuhama Campus.Alusteng,Srinngar.1 (10):312-313.
3. Glenny, R. H. and Robertson, T. H (2011) Determinants of Pulmonary Blood Flow Distribution. American Physiological Society, Compr Physiol. 1:245-262.
 4. Hamid, Q. Shannon, J. Martin, A.(2005). Physiologic Basis of Respiratory Disease. Chapter I (Histology and gross anatomy of the respiratory tract). BC. Decker Inc. Hamilton.Ontario.Pp:1-14.
 5. Chunder, R. Nandi, S. Guha, R. Satyanarayana, N.A (2010) Morphometric study of human trachea and principal bronchi in different age groups in both sexes and its clinical implications. Nepal Med. Coll. J., 12(4):207-214..
 6. Dellman, H. D. and Brown, E. M. (1993) Text Book of Veterinary Histology. Lea & Febiger. Pp: 194-202.
 7. AL-Zhgoul, M. B, Dalab, A. H. S, Abdulhakeem, E, Ismail, Z. B. and Thanain, A. (2013) Arabian oryx (*Oryx leucoryx*) trachea: a descriptive and morphometric analysis. Int. J. Morphol., 31(3):813-818.
 8. Dyce, K.M.; Sack, W.O and Wensing, C.J (2010) Textbook of Veterinary anatomy. 4th ed. Philadelphian: W. B. Saunders Comp. pp: 405-407, 519-523, 658-659, 662-663, 774-775.
 9. Byanet, O.; Boshia, J. A and Onoja, B. O (2014) Quantitative Study on the Trachea of the Red Sokoto (Maradi) Goat (*Capra hircus*). Vet. Med. Inter. Hindawi Publishing Corporation.Pp:1-5.
 10. Jumaah,Y.R (2017) Histomorphological Study of Trachea and Lung in adult indigenous Gazelle (*Gazella subgutturosa*). A Thesis Submitted to the council of Veterinary Medicine College, university of Baghdad for the Degree of Master of Science in veterinary Medicine Anatomy and Histology.
 11. Swindle, M. M. and Smith, A. C. (1998) Comparative anatomy and physiology of pig. Scand. J. of Lab. Ani. Sci. Suppl. USA. 25: 13-14.
 12. Abdul-Raheem, M. H. and Al-Haaki, A. G. (2006) A Comparative anatomical and histological study of the Trachea of Native awasi Sheep and black Goats. Iraqi J. Vet. Science 20 (1): 9-19.
 13. Habib, R.S. and Mahammed F.S. (2010) Histomorphological and radiological study of trachea and lungs of Angora goat (*capra ibex*).M.Sc. thesis, Veterinary Medicine College, University of Duhok.
 14. Hare, W. C (1975) Respiratory System In: The Anatomy of the Domestic Animals. 5th ed. Vol. 1, 2. ed . By R. Getty, W.B .Saunders Company, Pp: 511-514, 518-523, 926-933, 1290-1294, 1567-1572.
 15. Nzalak, J. O.Ibe, C. S. Salami, S. O.Umosen, A. D. Ali, M. N.Byanet, O.Maidawa, S. M and Imam,J.(2013). Macroscopic Studies of the Lower Respiratory System of the Red Sokoto Goat (*Capra aegagrushircus*). J. Vet. Anat. 6 (1):47-52.
 16. Essa, J. S. (2003). Study compared the tracheal morphologic in domestic sheep and goat. Iraqi Journal of veterinary science 17(1):105-109.
 17. Al-Umeri, S. K. W. (2015). Grossly and microscopic study of the trachea and bronchial tree in the local sheep (*OVIS ARIS*). Bas.J.Vet.Res.14 (1):145-153.
 18. Aspinall, V.; Capello, M. and Jappery, A (2009) Text book of introduction to veterinary anatomy and physiology, 2nd edition. Butter Worth Heinman. Elsevier, London. Pp. 90-96.
 19. Al-Abasi, R.J and Mirhish, M. (2001). Anatomical and Histological Study on the Trachea and Lung of One-Humped Camel in Middle of Iraq. M.Sc.thesis, Veterinary Medicine College, University of Baghdad.
 20. Zareena, Sh. Venkata, R. M. Hanimann K. S(2016) A study on anatomical dimensions of bronchial tree, Inter. J. of Res in Med

- Scie., 4(7):2761-2765.
21. Cano, I. and Perez, W. (2009) Quantitative Anatomy of the Trachea of the Giraffe (*Giraffa camelopardalis rothschildi*). Int. J. Morphol., 27(3):905-908.
 22. Pinheiro, L.L. Lima, A.R. Munis, J.A. Imbeloni, A.I. Fioreto, E.T. Fontes, F.S. Cabral, R. Branco, E. (2012). Anatomy and morphometric aspects of the trachea of *Saimirisciureus Linnaeus*, 1758: knowledge for emergency procedures Anais da Academia Brasileira de Ciências 84(4):973-977.
 23. Reece, W. O. (2009) Functional Anatomy and Physiology of Domestic Animals. 4th ed. Wiley-Blackwell. Pp: 273-275.
 24. Drake, R. L. Vogl, W. Mitchell, A. W.M. (2014) *Gray's anatomy for students (3rd ed.)*. Edinburgh: Churchill-Livingstone. Elsevier, Pp. 167-174.
 25. Hudson, L.Cand Hamilton, W.P. (1993) Atlas of feline anatomy for veterinarians. Philadelphia, Pa: WB Saunders .Pp.135-148.
 26. Al-Sadi, S. E.J. (2005). Topographical and histological study of the lung in the sheep and goats. AL-Qadisiyah. J. Vet .Med Scie. 4(2). 34-41.
 27. Louis, T. and Waugh, A. (2002) Veterinary Physiology and Applied Anatomy, A text book for Veterinary Nurses and Technicians. 1sted. Oxford Auckland Boston Johannesburg, Italy. Pp: 129-132.
 28. Tyler, W.S. (1983). Comparative sub gross anatomy lungs, pleuras, interlobular septa and distal airways. Am. Rev. Respir. Dis. 128:32-36.
 29. Nakakuki, S (1994). Bronchial tree, lobular division and blood vessels of pig lung. J. vet. Med. Sci. 56: 685-689.
 30. Pasquini, C. Spurgoen, T. and Pasquini. (1997). Anatomy of the Domestic Animals, Systemic and Regional Appropch. 5th ed. SUDZ Publishing. Pp: 322-324.
 31. Liao, A.T.; Chanf, M.H.; Chi, C. and Kuo, T. (2009) The bronchial tree and lobular division of the Formosan reeve's muntjac lung (*muntiacus reevesi micrurus*), Taiwan. Vet. J.35 (1): 29-25
 32. Oliveira, F.S.;Borges, E.M.;Machado, M.R.;Canola, J.C. and Riberio,A (2001) Anatomicosurgical arterial segmentation of the cat lungs (*Felis catus domesticus*). Braz. J. Vet. Res. Anim., Sci., 38(6): 253-257
 33. Ferrando , C ; Aguilar, G. Belda, F. J (2012) Extravascular Lung Water Does Not Increase in Hypovolemic Patients after a Fluid-Loading Protocol Guided by the Stroke Volume Variation. Critical Care Research and Practice Volume Article ID 437659, Pp7
 34. Hislop, A.;Howard, S. and Fairweather, D.V. (1984) Morphometric studies on the structural development of the lung in *Macaca fascicularis* during fetal and postnatal life. J. Anat. 138, 95-112.
 35. Kirschvink, N and Reinhold, P (2008) Use of alternative animals as asthma models. Curr. Drug. Targets, 9:470-484.
 36. Nakakuki, S (1993,) The bronchial tree and lobular division of the horse lung. J. Vet. Med. Sci. 55(3): 435-438.