

A comparison between Platelet-rich plasma and low-level laser therapy for the treatment of second degree burn in sheep

Ahmed Kadhim Munahi¹ Abbas Ali Hussein² Dhurgham Hameed AL Haidri³
Raed Gahat Mehjal⁴

^{1,2,4} Department of Veterinary Surgery, College of Veterinary Medicine, University of Al-Qadisiyah, Diwaniyah, Iraq.

³ Department of Clinical Sciences, Faculty of Veterinary Medicine, University of Kufa
Running Head: Protein & Low-Level Laser Therapy

*Corresponding Author: [E-mail: dhurghamh.alhaideri@uokufa.edu.iq](mailto:dhurghamh.alhaideri@uokufa.edu.iq)

Received date:23Dec2019 Accepted:(462) 15Nov2019 page (53-64) Pubished:31Dec209

DOI: <https://doi.org/10.36326/kjvs/2019/v10i23314>

Abstract

Background and aims: This experiment was conducted in order to compare the effect of Platelet-rich plasma (PRP) and low-level laser (LLL) therapy on healing of second-degree burn wound in sheep. Materials and Methods: Fourteen adult rams were divided into four groups of equal numbers. A second-degree burn was generated on the back of all animals. The burned area in the first and second group was exposed and autologous PRP and LLL (6 J/cm²), respectively were applied on burned area continuously for five days. Fourteen days later, samples were collected from all animals for histopathological examinations. Results: Histopathological evaluations on the second week showed the burn healing to be better in the PRP than LLL and both of them were better with respect to the control group. Conclusion: The application of PRP for five days is effective than LLL application in healing burn-related skin wounds in sheep model.

Key words: PRP, LLLT, second degree burn, sheep

مقارنة بين البلازما غنية الصفائح الدموية والليزر واطى الطاقة في علاج حروق الدرجة الثانية في

الأغنام

احمد كاظم مناحي¹ عباس علي حسين اللبان² ضرغام حميد الحيدري³ رائد كحط مهجال⁴
¹ و² و⁴ كلية الطب البيطري / جامعة القادسية / فرع الجراحة البيطرية
³ كلية الطب البيطري / جامعة الكوفة / فرع السريريات

الخلاصة

الهدف من الدراسة: أجريت هذه الدراسة من أجل مقارنة تأثير البلازما الغنية بالصفائح الدموية و العلاج بالليزر منخفض المستوى على شفاء الجرح من حروق الدرجة الثانية في الأغنام .
المواد وطرق العمل: تم استخدام اثنا عشر كبش مقسمة إلى ثلاث مجموعات متساوية.
عمل حرق من الدرجة الثانية على ظهر جميع الحيوانات. تعرضت المنطقة المحروقة في المجموعة الأولى والثانية بتطبيق البلازما الغنية بالصفائح الدموية و العلاج بالليزر منخفض المستوى (6 J/cm²) ،على التوالي في المنطقة المحروقة ولمدة خمسة أيام.
بعد أربعة عشر يوماً ، تم جمع العينات من جميع الحيوانات لغرض الفحص النسيجي المرضي.

النتائج: أظهر تقييم التشريح المرضي في الأسبوع الثاني أن التئام الحروق كان أفضل في بتطبيق البلازما الغنية بالصفائح الدموية من الليزر منخفض المستوى وكان كلاهما أفضل فيما يتعلق بمجموعة السيطرة .
 الاستنتاج: إن استخدام البلازما الغنية بالصفائح الدموية لمدة خمسة أيام فعال من العلاج بالليزر منخفض المستوى في شفاء الجروح الجلدية المرتبطة بالحروق في نموذج الأغنام.
الكلمات المفتاحية: البلازما الغنية بالصفائح الدموية ، العلاج بالليزر منخفض المستوى ، حرق من الدرجة الثانية ، الاغنام

Introduction

In veterinary medicine; burns can result from various household items including electrical, chemical as well as thermal equipment (1). Burn is still considered as one of the emergency cases which affects both sexes and all ages leading to serious physical disabilities with a trend to morbidity & mortality (2). In addition, most pains are treated and managed with high health care cost (3). Furthermore, burns are among the most devastating injuries (4).

Deep second-degree burn involves the whole epidermis and most dermis and is distinguished by the existence of non-elastic red or white layer on the upper part of the burn which did not blanch under pressure(5).

Discovering more effective agent with fewer complications for treatment of burn has been a source of concern for scholars. Different techniques have been used to treat burn injury, one of them is low-level laser therapy which had been employed clinically since 1971 during the first successful cases reported by Professor Ander Mester and colleague (6). The frequency of the laser light and the type of irradiating tissue delimit the depth which is penetrated by the light and 99% of the low-level laser are absorbed in the superficial layer of the skin(7).

Few studies have demonstrated inconsistent results regarding the effect of diode laser on burn healing(8). Irradiation of the burn with 990 nm laser was effective for enhancing the healing of 3rd-degree burn in diabetic rats⁹ (Matic *et al.*, 2009). Several studies have evaluated the effects of pulsed diode laser on skin wound healing(10).

Platelet-rich plasma has a high concentration of thrombocytes and the alpha granules of platelets include platelet released growth factors that contain molecules such as platelet-derived growth factors, vascular endothelial growth factor, these stimulate proliferation of cells and differentiation leading to tissue formation (11). This preparation is an autologous product that concentrated a huge number of platelets in a little volume of plasma. Platelet-rich plasma serves as a fibrin tissue adhesive with hemostatic and tissue sealing activities, and has a unique ability to enhance wound healing and promote osteogenesis (12).

To the best of our knowledge, no study has compared the effects and distinguished the positive effect of low-level laser and PRP on histological healing rates of second-degree skin burn in sheep.

Materials And Methods

1. Animals

Permission was obtained from deanery of Veterinary Medicine College in the University of AL-Qadisiyah as well as from the administration of the animal teaching station to carry out this experiment.

In a randomized clinical trial, Fourteen rams weighing (30 ± 5) kg and aging (8 ± 2) months were kept an identified stalls. All animals were preserved under similar conditions and received the same drugs and vaccines against endemic diseases, water was provided *ad libitum* and food was presented on regular basis, the experiment was conducted from January to February 2017.

2. Chemicals, Laser and PRP

Low level laser therapy was done with the following criteria: 660 nm, 50 mW, 10 s, 6 J/cm², at 146 pulse rate per second (**Figure 1**). Twenty milliliters of autologous platelet-rich plasmas of whole blood were aspirated from jugular vein of certain animals, centrifuged twice at 4000 rpm for 10 min. The layer with yellow color containing

plasma, platelets and growth factors was collected gently, then 10% CaCl₂ was added. Thereafter, the solution was preserved in an incubator at 37°C for a whole day to activate platelets, in order to release high concentration of growth factors and was kept under a temperature of -8°C(12).

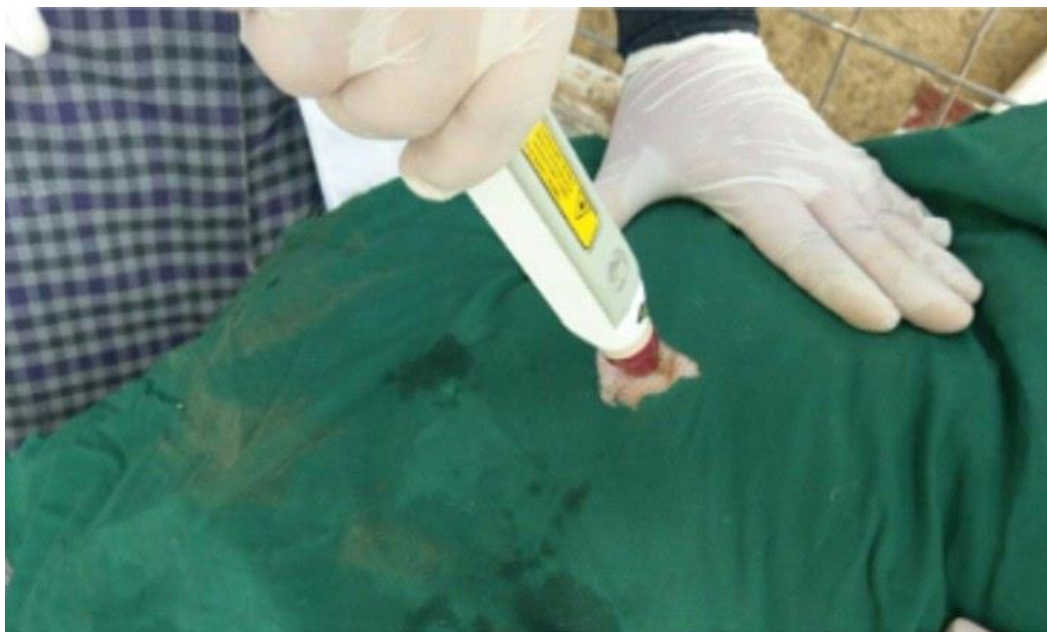

Figure 1. Application of low level laser over the burned area.

3. Burn formation

Local analgesia was achieved by using a single dose of injection with field block of lidocaine HCl 5cc (Ibn Hayyan Pharma Syria) in the back region of the animals after shaving and antiseptic was applied using 10% povidone-iodine solution.

A controllable and adjustable temperature machine with the probe(13) was used at 155°C by applying the probe over the skin of the local anesthetized animal for 10 s with no pressure (**Figures 2 and 3**); using this procedure, a second-degree partial

thickness burn was formed. After formation of burns, all animals were divided equally and randomly into three groups of four animals each. Group one (P); the affected area was covered with PRP once a day continuously for five days. Group two (L); LLL was applied on the burned area with a single dose per day for five days. Group three (C); the control in which the animals were left without any treatment. Group four, negative control(NC); The negative group took samples from them without any treatment or burning.



Figure 2. The controllable and adjustable temperature machine.

4. Histopathological examination

Samples were taken from the burned skin tissue at the second week from all groups for histopathological examination assessments.

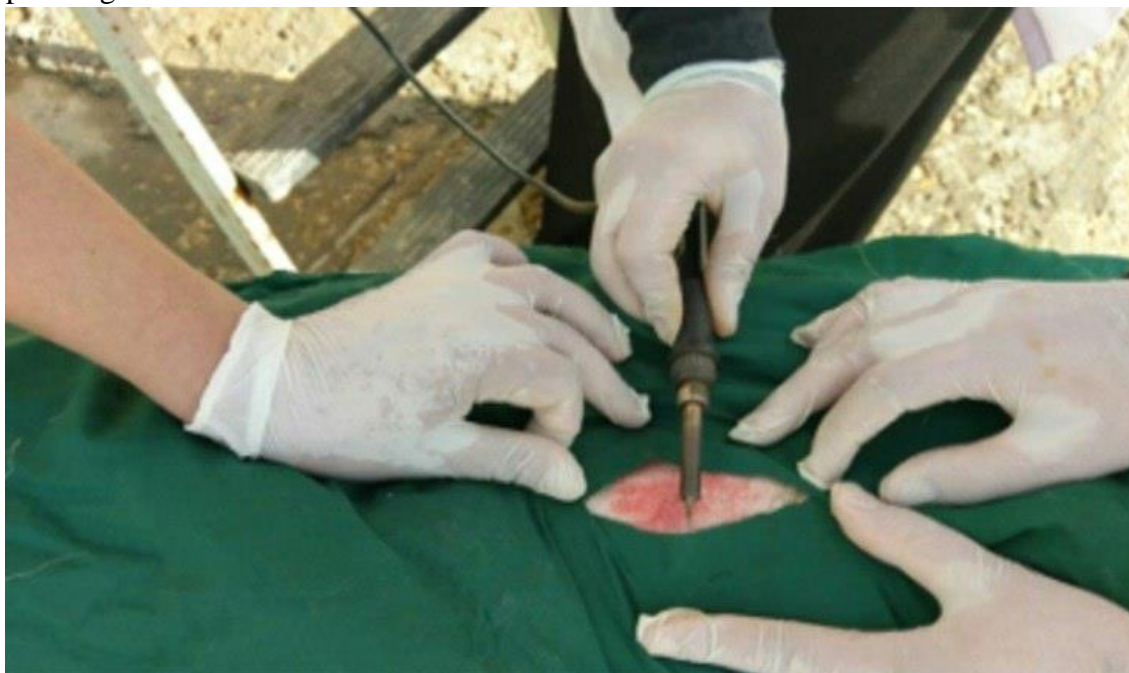

Figure 3. Applying the probe over the skin of the local anesthetized animal for ten seconds with no pressure.

Results

Burn wound model at 155°C for 10 s produced uniform second degree burn on the skin of sheep, on day 14 post burn, they were initiated to promote healthy tissue in both group one and two with a degree more than that of the control group. Wound contraction was higher in group one than in group two and control, clinically inflammatory reaction and exudation were less in group one than in group two and control group. Also, there were no adverse

outcomes (such as infection) in any of the groups.

Group one shows that there is a thickening of keratinized layer and marked downward hyperplasia of epidermis as well as profuse collagen with infiltration of inflammatory cells in the dermis and formation of new blood vessels with fibrosis (Figures 4 and 5). All these developing changes showed that group one is healthier when compared with the other two groups.

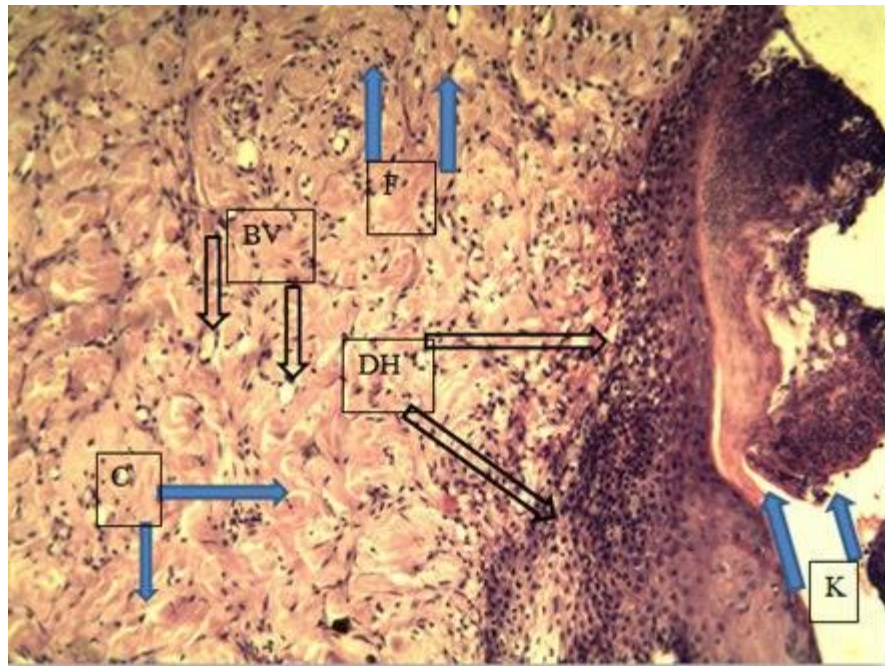


Figure 4. Thickening of the keratinized layer (K), marked downward hyperplasia of epidermis (DH), profuse collagen (C) with infiltration of inflammatory cells in the dermis, formation of new blood vessels (BV) with fibrosis (F). H&E, X100.

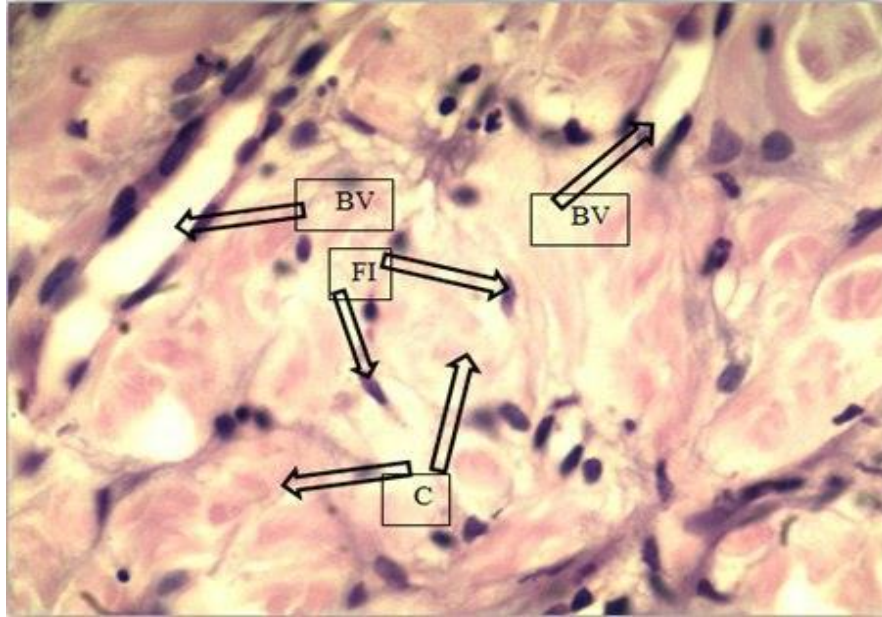


Figure 5. Formation of new blood vessels (BV), profuse collagen (C) and proliferation of fibroblast (FI). H&E, X400.

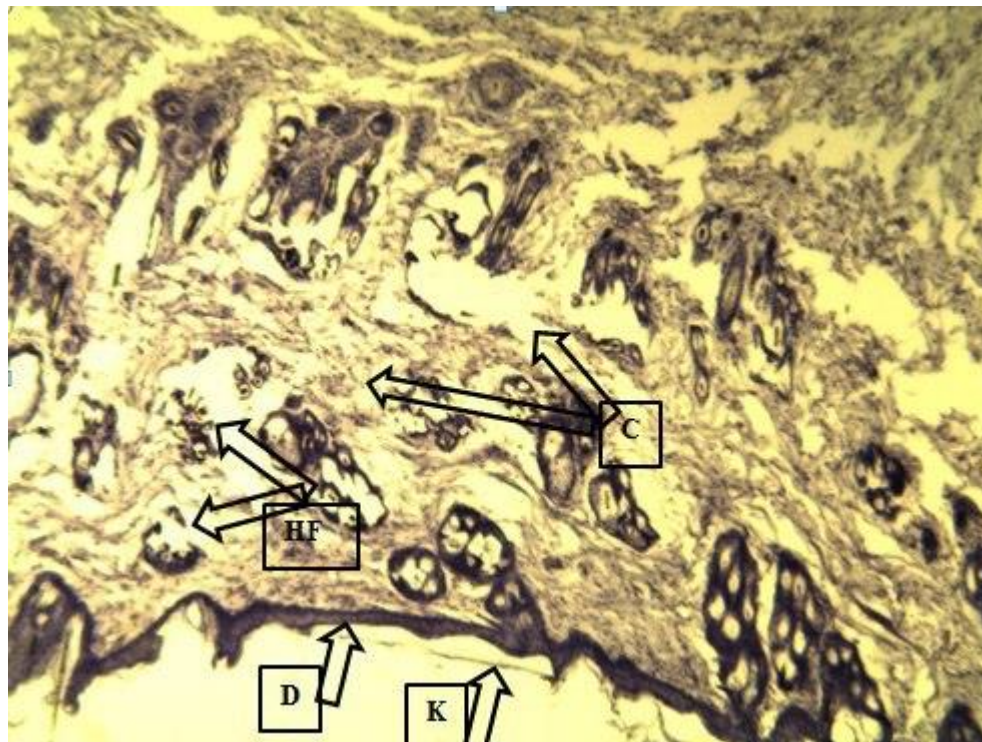


Figure 6. Complete sloughing of the keratinized layer (S), destruction of hair follicle (HF) with few collagen in the dermis (C). H&E, X100.

Accordingly, in the second group, it was noted that the healing rate is better than the control group but with less improvements than the first group. Group two recorded complete sloughing of keratinized layer and destruction of hair follicle and there was a few collagen in the dermis (Figures 6 and 7). Healing processes in group three were just at their initial stage in comparison with group one and two. Control group showed that there was a destruction of the keratinized layer; moreover, there was sloughing and destruction of epidermis as well as absence of hair follicle with few collagen in dermis (Figures 8 and 9). [figure 10 show Cross-section to the negative group without any treatment or burning.](#)

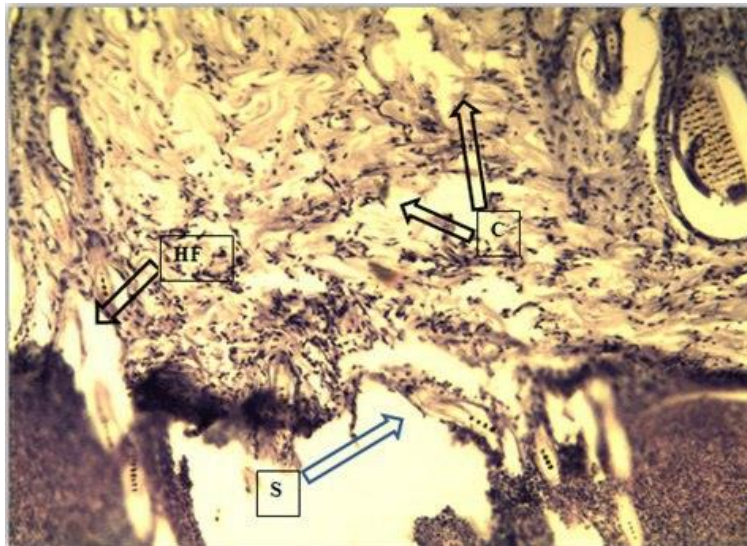


Figure 7. Thin keratinized layer (K) with destruction and thinning of epidermis (D), destruction of hair follicle (HF) with collagen in the dermis (C). H&E, X400.

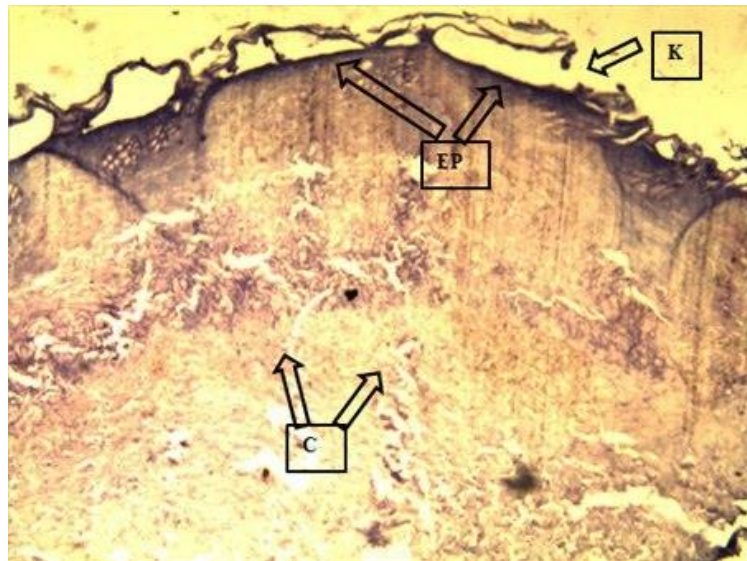


Figure 8. Destruction of the keratinized layer (K), sloughing and destruction of the epidermis (EP), absence of hair follicles with few collagen (C) in dermis. H&E, X400

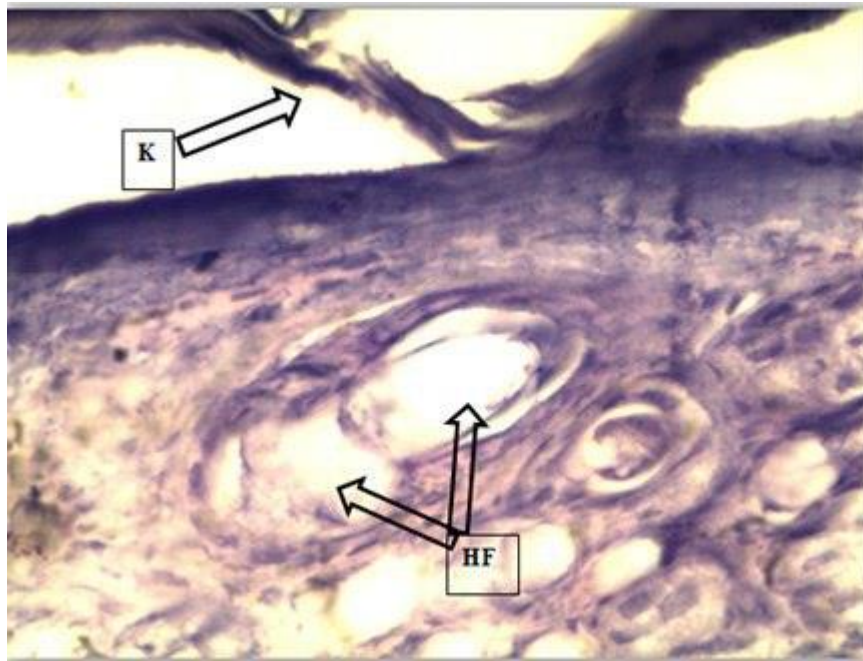


Figure 9. Destruction of the keratinized layer (K), with destruction of the hair follicles (HF) in the dermis. H&E, X400.

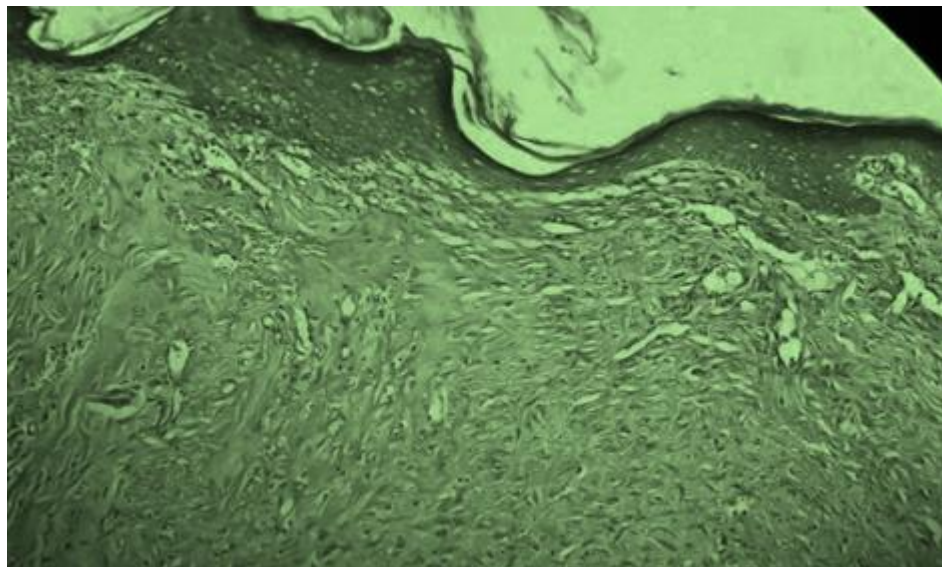


Figure 10. The negative control without any treatment or burning.

Discussion

Burns are one of most widespread health problems, when the treatment becomes topical; it is considered as a very important problematic due to multiple materials and drugs have been used for this purpose, many

of them have been applied for a long time, some have only been approved lately by researchers (14). An ideal topical treatment must heal the burn in a short time with best results as well as decrease

mortality and morbidity rates by preventing sepsis and they should be available and not expensive and restore the damaged tissue as normal as possible. Research studies are ongoing to discover the ideal agent. Burns can be classified by depth into four degrees, the second degree (the subject of the current study) involves the whole epidermis and may be superficial or deep (14).

The final aim at all contemporary burn treatments is to accelerate the healing of skin and avert infection of burn site (15,16). The succession of the occurrences that remodel the injury are classified into three sequential phases; inflammation, proliferation and tissue remodeling, the normal healing process could be hindered at any step along its course by different factors (16).

In the light of such research studies, it has been proposed that other agent have more beneficial effect with less side effects.

Although some researchers have clarified the advantageous effects of low level laser on burn healing on healthy animals(17), the current study showed that low level laser therapy can noticeably fasten the wound healing rate of second degree burn in healthy sheep.

The biostimulatory effects of low level laser which was applied in the present study showed marked increase on the healing rate of the burned area with better changes in group two and better healing process than group three (increases quality & tensile strength of tissue repair and improved blood circulation).

It seems that group two animals displayed beneficial effects due to the presence of laser light. When laser light is used appropriately, it can stimulate the healing rate of burned tissue and this is in line with the study of (18) who proved that the dermis can be regenerated with better results when irradiated with low level laser and explicate that in treatment with low

level laser both *in vitro* and *in vivo*; the mast cells and macrophages can be activated to produce growth factors which give the desired effects of healing.

The suggested mechanism by which the burn healing process can be increased by low level laser therapy is by absorption of light energy by the mitochondria and this can lead to sustaining the cell energy and stimulate the production of chemical mediators (13).

The result of our study contradicts the results obtained by (17,19) who clarified that low-level laser therapy has no significant improvement in the burned area when compared with control group. However, this may be attributed to the fact that the laser irradiation dose was 2.3 J/cm^2 and this insufficient low energy may not be able give the beneficial effects by stimulating the microphages and release of growth factors.

The current results show that the low-level laser irradiation with a dose of 6 J/cm^2 produces a significant increase in the burn healing rate in comparison with control group and this confirms the results of (6, 9) who verified that low level laser significantly increased the burn closure rate.

It can be concluded that low level laser therapy at 6 J/cm^2 continuously for five days in second degree burn in sheep increase the healing process rate when compared with control group and these results are similar to the findings obtained in group two.

Platelet-rich plasma is an autologous agent obtained from whole blood through the process of gradient density centrifugation, these concentrates have huge numbers of platelets in a little volume of plasma (11). Platelet-rich plasma has been demonstrated to enhance wound healing and tissue sealing when applied exogenously to soft tissues (20). There are few research studies about the use and effect of platelet-rich plasma on burned tissue, but the

available ones are related to humans. However, the platelet-rich plasma is considered as a safe treatment given its autologous source and long persistence application without any life threatening complications.

The application of autologous platelet-rich plasma continuously for five days shows a clear improvement in the healing rate of burned area when compared with group three and two, these results are in line with (21). The variable mechanisms of action of platelet-rich plasma are extensive due to the yield of numerous bioactive materials. The advantage of applying platelet-rich plasma for the enhancement of injured tissue may be due to the presence of concentrated platelets in the site; whenever there is stimulation, it results in huge amount of growth factors (22).

The results of the current study in group one show an important healing process rate which was better compared to the results in group three and this is in accordance with (20) who found that there was no complication when platelet-rich plasma was applied in intractable skin ulcer and the wounds achieved complete epithelialization.

Platelets participate in hemostasis at sites of vascular damage and they include numerous growth factors and cytokines that play an important role in inflammation and tissue repair (23). These peculiarities of platelet have made platelets to be applied as a therapeutic device for bolstering wound healing, especially in animals with impaired or delayed tissue repair.

Platelet-rich plasma stimulates angiogenesis and proliferation of fibroblast and application of these agents improve wound healing of soft and hard tissue alike; these findings are confirmed by (24) and these are in accordance with the results of the current study. A deep dermal burn can be treated by platelet-rich plasma because of its hemostatic and antimicrobial abilities,

and also the affirmatory impact can be seen in wound healing which is in line with the results of (25), and also with the results obtained in group one. Platelet-rich plasma seems to partially ameliorate burn healing and apparently this type of treatment can be used beneficially (26).

Conclusion

PRP and LLL can improve second degree burn healing in sheep; furthermore, both of them are better than the control group.

Conflict Of Interest Statement

The authors declare that there is no conflict of interests regarding the publication of this article. This manuscript has not been previously published and is not under consideration in the same or substantially similar form in any other peer-reviewed media.

Informed Consent Statement

Informed consent was obtained from all individuals included in this study.

Animal Rights Statement

The experiments on animals were conducted in accordance with the local Ethical Committee laws and regulations as regards care and use of experimental animals.

All procedures performed in studies involving animals were in accordance with the ethical standards of the institution or practice at which the studies were conducted. We have explained the ethical state of involving animal in our study in details in the materials and methods section which also include the references that we depended on.

Acknowledgments

This work was supported by the Al-Qadisiyah University Research Council. We are very grateful to the College of Veterinary Medicine, University of Al-Qadisiyah. Special thanks to the head of the Department of Veterinary Surgery. Furthermore, we would like to thank the head of Laboratories in the College of

Veterinary Medicine, University of Al-Qadisiyah for providing the necessary support for us to meet the requirements of this research.

References

1. Quist, E.M., M. Tanabe, J.E. Mansell & J.L. Edwards 2012. A case series of thermal scald injuries in dogs exposed to hot water from garden hoses (garden hose scalding syndrome). *Veterinary Dermatology*, 23(2),162-e33.
2. Peck, M.D., Jeschke M. 2011. Epidemiology of burn injuries globally. *Burns*.37(7):1087–1274.
3. Khorasani, G., S.J. Hosseinimehr, M. Azadbakht, A. Zamani & M.R. Mahdavi 2009. Aloe versus silver sulfadiazine creams for second-degree burns: a randomized controlled study. *Surgery Today*, 39(7), 587-91.
4. Barss, P., S.B.M. Barss, G.S. Smith, D. Mohan & S.P. Baker, 1998. *Injury prevention: an international perspective epidemiology, surveillance, and policy*: Oxford University Press, USA.
5. Warriner, R. & Burrell, R. 2005. Infection and the chronic wound: a focus on silver. *Advances in Skin & Wound Care*, 18(8), 2-12.
6. Ezzati, A., M. Bayat, A. Khoshvaghti, 2010. Low-level laser therapy with a pulsed infrared laser accelerates second-degree burn healing in rat: a clinical and microbiologic study. *Photomedicine and Laser Surgery*, 28(5), 603-11.
7. Vasheghani, M.M., M. Bayat, M. Dadpay, M. Habibie & F. Rezaei 2009. Low-level laser therapy using 80-Hz pulsed infrared diode laser accelerates third-degree burn healing in rat. *Photomedicine and Laser Surgery*, 27(6), 959-64.
8. Meireles, G.C., J.N. Santos, P.O. Chagas, A.P. Moura & A.L. Pinheiro 2008. Effectiveness of laser photobiomodulation at 660 or 780 nanometers on the repair of third-degree burns in diabetic rats. *Photomedicine and Laser Surgery*, 26(1), 47-54.
9. Matic, M., B. Lazetic, M. Poljacki, V. Djuran, A. Matic & Z. Gajinov 2009. Influence of different types of electromagnetic fields on skin reparatory processes in experimental animals. *Lasers in Medical Science*, 24(3), 321-7.
10. Kakudo, N., T. Minakata , T. Mitsui, S. Kushida, F.Z. Notodihardjo & K. Kusumoto, 2008. Proliferation-promoting effect of platelet-rich plasma on human adipose-derived stem cells and human dermal fibroblasts. *Plastic and Reconstructive Surgery*, 122(5), 1352-60.
11. Everts, P.A., J.T. Knape, G. Weibrich, J.P. Schönberger, J. Hoffmann, E.P. Overdeest, H.A. Box & A. van Zundert, 2006. Platelet-rich plasma and platelet gel: a review. *The Journal of Extracorporeal Technology*, 38(2), 174.
12. Tamimi, F.M., S. Montalvo, I. Tresguerres & L.B. Jerez, 2007. A comparative study of 2 methods for obtaining platelet-rich plasma. *Journal of Oral and Maxillofacial Surgery*, 65(6), 1084-93.
13. Yu, H-S., K-L. Chang, C-L. Yu, J-W. Chen & G-S. Chen. 1996. Low-energy helium-neon laser irradiation stimulates interleukin-1 α and interleukin-8 release from cultured human keratinocytes. *Journal of*

- Investigative Dermatology, 107(4), 593-6.
14. Orgill, D.P., 2009. Excision and skin grafting of thermal burns. *New England Journal of Medicine*, 360(9), 893-901.
 15. Chrubasik, J.E., B.D. Roufogalis, H. Wagner, S. Chrubasik 2007. A comprehensive review on the stinging nettle effect and efficacy profiles. Part II: urticae radix. *Phytomedicine*, 14(7-8), 568-79.
 16. Daryabeigi, R., M. Heidari, S.A. Hosseini, M. Omranifar, 2010. Comparison of healing time of the 2nd degree burn wounds with two dressing methods of fundermol herbal ointment and 1% silver sulfadiazine cream. *Iranian Journal of Nursing and Midwifery Research*, 15(3), 97.
 17. Al-Watban, F.A. & G.D. Delgado, 2005. Burn healing with a diode laser: 670 nm at different doses as compared to a placebo group. *Photomedicine and Laser Therapy*, 23(3), 245-50.
 18. Matic, M., B. Lazetic, M. Poljacki, V. Duran & M. Ivkov-Simić, 2003. Low level laser irradiation and its effect on repair processes in the skin. *Medicinski preglod*, 56(3-4), 137-41.
 19. Schlager, A., P. Kronberger, F. Petschke & H. Ulmer 2000. Low-power laser light in the healing of burns: A comparison between two different wavelengths (635 nm and 690 nm) and a placebo group. *Lasers in Surgery and Medicine: The Official Journal of the American Society for Laser Medicine and Surgery*, 27(1), 39-42.
 20. Kakudo, N, S. Kushida, T. Ogura, T. Hara, K. Suzuki & K. Kusumoto, 2012. The use of autologous platelet-rich plasma in the treatment of intractable skin ulcer: a case series. *Open Journal of Regenerative Medicine*, 1(03), 29.
 21. Middleton, K.K., V. Barro, B. Muller, S. Terada & F.H. Fu, 2012. Evaluation of the effects of platelet-rich plasma (PRP) therapy involved in the healing of sports-related soft tissue injuries. *The Iowa Orthopaedic Journal*, 32, 150.
 22. Hammond, J.W., R.Y. Hinton, L.A. Curl, J.M. Muriel & R.M. Lovering, 2009. Use of autologous platelet-rich plasma to treat muscle strain injuries. *The American Journal of Sports Medicine*, 37(6), 1135-42.
 23. Vang, S.N., C.P. Brady, K.A. Christensen, K.R. Allen, J.E. Anderson, J.R. Isler, D.W. Holt & L.M. Smith, 2007. Autologous platelet gel in coronary artery bypass grafting: effects on surgical wound healing. *The Journal of Extracorporeal Technology*, 39(1), 31.
 24. Pallua, N., T. Wolter & M. Markowicz 2010. Platelet-rich plasma in burns. *Burns*, 36(1), 4-8.
 25. Marck, R.E., E. Middelkoop & R.S. Breederveld, 2014. Considerations on the use of platelet-rich plasma, specifically for burn treatment. *Journal of Burn Care & Research*, 35(3), 219-27.
 26. Ozelik, U., Y. Ekici, H.Y. Bircan, C. Aydogan, S. Turkoglu, O. Ozen, G. Moray & M. Haberal 2016. Effect of topical platelet-rich plasma on burn healing after partial-thickness burn injury. *Medical science monitor: International Medical Journal of Experimental and Clinical Research*, 22, 1903.