



The Levels of Complement C5a in Wound Infected with *Pseudomonas aeruginosa* in Albino Rat

Hawra'a Ala'a Hassen1, Kifah Fadhil Hassoon2

^{1,2}Department of Microbiology / University of Kufa \ Faculty of Veterinary medicine

E-mail: alaahawraa92@gmail.com

kefahf.hasson@uokufa.edu.iq

Received date:15 Jun 2022 Accepted:(484)23 Jun 2022 page: (16-21) Published:30 Jun 2022

DOI: <https://doi.org/10.36326/kjvs/2022/v13i13351>

Abstract

Wounds infection is pathogen-infected to the point where it triggers a local and systemic reaction in the host. Multiple pathogens typically colonize wounds, and *Pseudomonas aeruginosa* has a higher prevalence in wound infection. This study tried to assess the immune response by measuring the level of complement fragment C5a in the serum of rats that induced wound infected with *Pseudomonas aeruginosa*. 51 female Albino rats models with weight (100-400g) and the average age of 150 days were selected for this study. The animal was divided into three groups (infected wound , wound without infection, and healthy control) and the procedure was performed by inducing 10 mm excisional wound on the dorsal region of rats and after 24h from inducing wound contaminated the wound region in the infected group only with bacterial suspension that contains 2.5×10^6 CFU of *P. aeruginosa*. Then at specific determined time points (24hrs, 48hrs, 72hrs) after infection blood samples and skin biopsy samples were collected. By using ELISA kitt sandwich methods we found that C5a is highly elevated in the infected group in comparison with other animal groups. And the histological section showed no signs of inflammation during 24hrs while necrosis of the dermis layer was observed after 48hrs and 72hrs.

Keyword: C5a, immune response, wounds infection

Introduction:

Wound can infected by both gram positive and gram negative bacteria. *P. aeruginosa* is one of the highly prevalent and hazardous microbes involved in the etiology of serious nosocomial infections, and it is typically found in hospitals' wet environments. It is a saprophyte and can invade normal humans [1]. It has the ability to infect most organs of the body such as gastrointestinal tract and central nervous systems, as well as the skin, eye, ear, blood, soft tissue, bone, and joints, but Cutaneous infections are a special concern because of their frequency and come into direct contact with the outside world [2]. The body's immunological response is

triggered when the wound becomes infected like the complement system [3].

The complement system is one of the innate immune system effector mechanisms that aid in the quick clearance of infections and dead or dying cells, as well as determining the range and limits of the inflammatory immune response [4] [12]. Activation of the complement is a process that happens in skin wounds and has been linked to altered wound healing in a variety of models and by one of the three standard pathways complement can trigger its activation (classical, lectin, or alternative) [5]. Many potent effectors are

produced as a result of complement activation, including anaphylatoxin C5a [3].

C5a is a type of complement fragment that is produced during complement activation and causes a variety of biological responses [6]. C5a is a strong inflammatory mediator and chemoattractant through its classical receptor C5aR. Which acts to attracting

Materials and Methods:

Bacterial Sample:

A stock sample of *Pseudomonas aeruginosa* isolated from human burn patients at the Burn Center of Al- Sadder Medical City in Al-Najaf, Iraq were used for this study. The isolate sample was cultured on MacConkey agar and Blood agar and incubated at 37°C for 24 hours. On the MacConkey agar the

Preparation of Bacterial Dose:

Overnight culture was Inoculated into one bacterial culture tube containing 5 ml of fresh BHI broth and incubated for 18 h at 37°C. The subculture was centrifuged (10 min, 6000 rpm). The bacterial pellet was washed once and resuspended in PBS solution to obtain 2.5×10^6 CFU by spectrophotometer at OD600nm measurement [8].

Animal Infection:

The procedure starts with shaving the dorsal region of rats with hair clippers and sterilizing the skin with iodine and alcohol. Then make an excision wound (10 mm diameter) on the rat's back using surgical scissors and forceps. After 24h from inducing wound, contaminated the wound region with bacterial suspension that might contain 2.5×10^6 CFU of *P. aeruginosa*. A swab was taken from the wound surface after 24 hours from inducing infection and cultured on MacConky agar to ensure that the infection was occurring [8]. Blood samples and skin biopsy will be taken for immunological and histological examination at (24hrs, 48hrs, 72hrs) after infection.

Complement C5a Estimation:

A disposable syringe was used to collect two milliliters of blood by a cardiac puncture. For serum separation, blood samples were placed in a gel tube and centrifuged for 5 minutes at 3000 rpm. Sera were kept at -70°C for further research. The sandwich ELISA

macrophages and neutrophils to the site of inflammation and causes an increase in an oxidative burst, phagocytosis, and granule enzyme release [7]. It can also stimulate macrophages and monocytes to produce TNF- α and IL-1 which is critical for the healing process [5]

bacterial growth appeared non-lactose ferment, while beta hemolysis was appeared on Blood agar culture. And as conforming identification for bacterial sample the VITEK-2 compact system were used. The Gram-negative identification card (ID-GNB card) shown catalase, oxidase and citrate positive result while indole, methylred, urease and H₂S appeared negative.

principle was employed with ELISA kits (BT LAB company/China) and according to the manufacturer's instructions, the optical density (OD) is determined spectrophotometrically at a wavelength of 450 nm.

Histopathological Examination :

The cross-sectional full-thickness skin sample was isolated from each group of rat were collected at (24hrs, 48hrs, 72hrs) for the histopathological alterations. The samples were fixed in 10% buffered formalin, processed and blocked with paraffin, and then sectioned into 5 μ m sections and stained with hematoxylin and eosin.

Statistical Analysis:

The data were analyzed using the ANOVA computer program, with a P value of less than 0.05 considered significant.

Ethics approval:

The experimental processes protocols were approved by Research Centre's Ethics Committee's suggestion, of the of Kufa University, Council on Guidelines to ensure that experimental animals have properly cared. (authorization from the Animal Experimentation Ethics Agency; Ethic no. 12917).

Result:

Isolation of *Pseudomonas aeruginosa* From Wounds After Inducing Infection:

A smear was taken from the wound surface and cultured on MacConky agar as a

confirming step for the infection occurring. The results indicate that animals in the infected group were shown positive culture as

in Figure (1). However the animals in wound without infection group were appeared clear from infection.

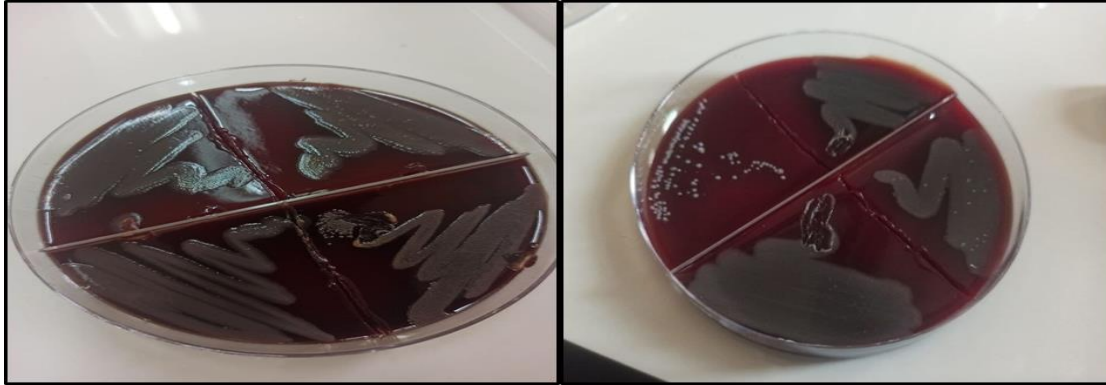

Figure (1): Isolation of *P. aeruginosa* from wounds after inducing infection

Histopathological Examination:

The wound area in the wounded group without infection showed a normal feature of the wound healing process without any sign of inflammation in the dermis layer in each of (24, 48, and 72) hours after inducing the wound as in Figure (2 : A, B, C). While in the infected group the wound area showed no signs of inflammation in the dermis layer

after 24hrs as in Figure (3: A). But after 48hrs and 72hrs the necrosis of fibrous tissue was observed in the lower dermis layer of the wound area, where fibrocytes' necrosis formed spaces (arrowheads) in affected areas. Also, the infiltration of inflammatory cells (arrows) was observed in the affected areas as in Figure (3: B, C).

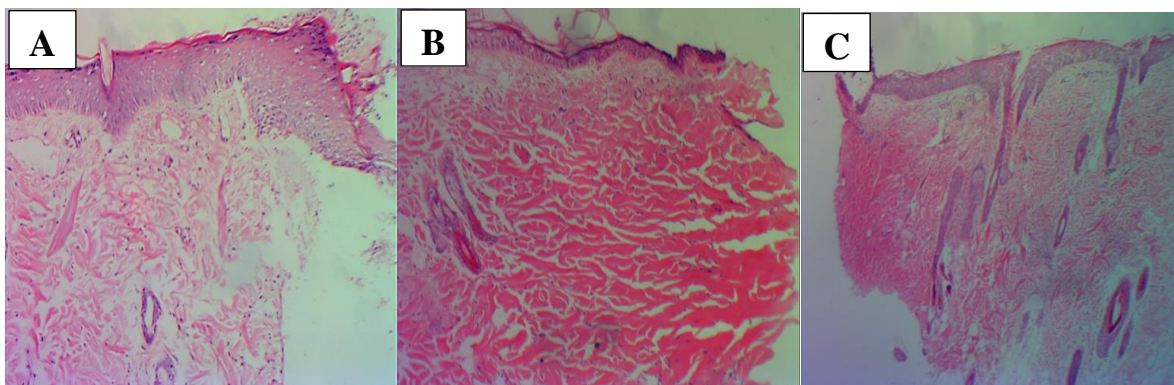


Figure (2): Photomicrograph of the wound without infection (A) 24hrs (B) 48hrs and (C) 72 hrs after wound induction. H&E. A, B and C: x100

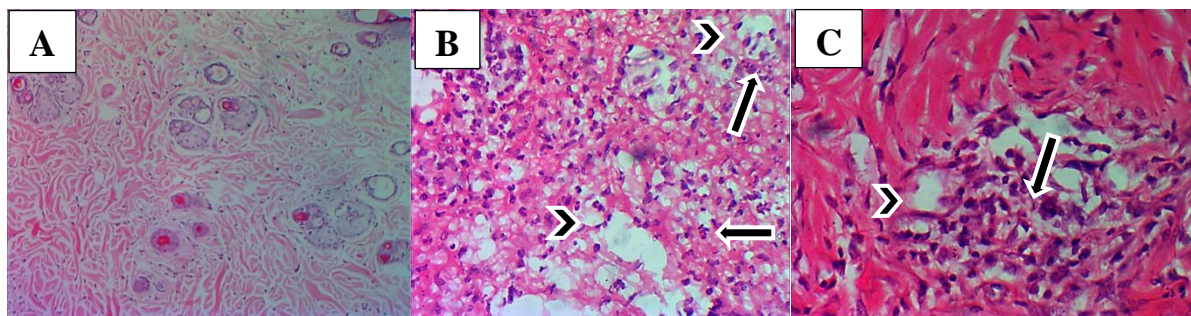


Figure (3): Photomicrograph of *Pseudomonas* infected wound (A) 24hrs (B) 48hrs and (C) 72 hrs after wound infection. H&E. (A) x100 (B) and (C) x400.

Serological Test:

When compared between the level of C5a concentration produced at different times intervals founding that after 24hrs from inducing infection, mean concentration in the infected group and non-infected wound respectively was (1.52 ± 0.84)pg/ml and (0.148 ± 0.04) pg/ml and $P < 0.0001$, while in healthy control was (0.146 ± 0.002) pg/ml and $P < 0.0001$. The statistical analysis showed a highly significant difference between different values at $P \leq 0.05$ as in Figure (4).

While after 48hrs from induce infection, mean concentration in the infected group and non-infected wound respectively was ($1.72 \pm$

0.92) pg/ml and (0.144 ± 0.03) pg/ml and $P < 0.0001$, while in healthy control was (0.146 ± 0.002) pg/ml and $P < 0.0001$. The statistical analysis showed a highly significant difference between different values at $P \leq 0.05$ as in Figure (4).

Finally, after 72hrs from induce infection the mean concentration in the infected group and non-infected wound respectively was (1.71 ± 0.92) pg/ml and (0.119 ± 0.02) pg/ml and $P < 0.0001$, while in healthy control was (0.146 ± 0.002) pg/ml and $P < 0.0001$. The statistical analysis showed a highly significant difference between different values at $P \leq 0.05$ as in Figure (4).

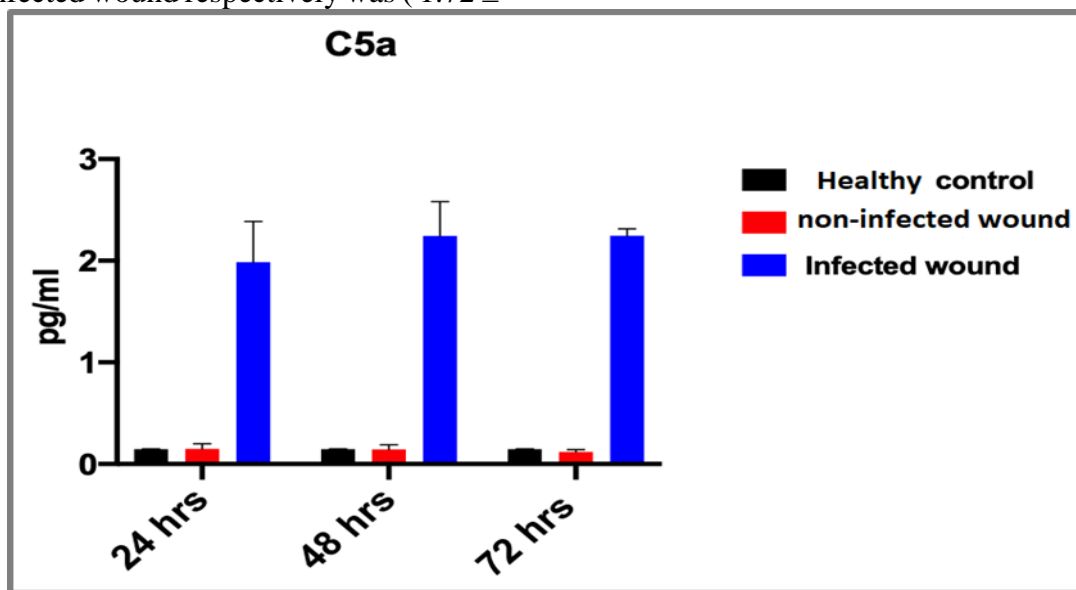


Figure (4): Serum Concentration of C5a Produced from Studied Group at Different Time (24,48 ,72) hrs

Discussion :

The wound area in the infected group showed normal features of the wound healing process, where no signs of inflammation in the dermis layer were observed after 24hrs, this may be related to *P. aeruginosa* colonizing the upper epidermal layers before invasion into the dermis, causing the epidermis layer to loss and de-keratinization of the skin constructs, as well as partial loss of basement membrane [2].

The results of the present study also showed that necrosis of fibrous tissue was observed in the lower dermis layer of the wound area at 48hrs, and 72hrs, where the necrosis of fibrocytes formed a space in affected areas. In addition, infiltration of inflammatory cells

was observed in affected areas. This concurs with Pletzer and co-workers showed that on 48hrs the disease further progressed into the deep skeletal muscle area and around the necrotic tissue, dermal neutrophil infiltration and a large amount of cell debris were apparent, Also shown at 72hrs inflammation extended further into the upper dermis and the underlying muscle tissue started to push to the surface, the early abscess/pus as observed by the accumulation of cellular debris, mild fibroblastic proliferation at the edges of the necrotic tissue and further developed into extensive fibroblastic proliferation [9].

The present study revealed a highly significant difference in the level of C5a

produced from the infected group with those who obtained in the non-infected and healthy control at different times lines (24, 48, 72) hours. The present result seems to be similar with opinion obtained by Sinno and co-workers that founding the topical application of complements C3 and C5 to wounds increased inflammatory cellular recruitment, which they contributed to the common mechanism of action of complement wound healing effects, as well as an increase in fibroblast infiltration and collagen deposition, which they attributed to the likely mechanism of action of complement wound healing effects. Furthermore, the complements C3 and C5 have been demonstrated to speed up and improve wound healing when used separately and in

References:

1. AL-Shamaa, N. F., Abu-Risha, R. A., & AL-Faham, M. A . Virulence genes profile of *Pseudomonas aeruginosa* local isolates from burns and wounds. *Iraqi journal of biotechnology*. 2016; 15(3). <https://jige.uobaghdad.edu.iq/index.php/IJB/article/view/197>
2. Ruffin, M., & Brochiero, E. . Repair process impairment by *Pseudomonas aeruginosa* in epithelial tissues: major features and potential therapeutic avenues. *Frontiers in cellular and infection microbiology*. 2019; 9, 182. <https://doi.org/10.3389/fcimb.2019.00182>
3. Al-Jebouri, M. M., & Al-Mahmood, B. Y. R . Prevalence of Different Types of Micro-Organisms and Levels of Complement C5a in Patients with Acute-Phase Wound Infections. *Open Journal of Pathology*. 2019; 9(02), 19. <https://doi.org/10.4236/ojpathology.2019.92003>
4. Schartz, N. D., & Tenner, A. J. The good, the bad, and the opportunities of the complement system in neurodegenerative disease. *Journal of Neuroinflammation*. 2020; 17(1), 1-25. <https://doi.org/10.1186/s12974-020-02024-8>
5. Cunnion, K. M., Krishna, N. K., Paller, H. K., Pineros-Fernandez, A., Rivera, M. G., Hair, P. S., ... & Dobrian, A. D. Complement activation and STAT4 expression are associated with early inflammation in combination [10]. Triplett and Hurwitz also mentioned that mast cell aggregation and progressive angiogenesis as is the fact that the existing bacteria or any microbe induces recruitment of inflammatory cells, which leads to extended wounds [11].

Conclusions:

The study concludes that complement (C5a) is highly affected by wound infection and recorded a high concentration in the infected group compared with other animals group. And appearing that no signs of inflammation in the dermis layer were observed after 24hrs. While necrosis of fibrous tissue was observed in the histological section of the lower dermis layer after 48hrs and 72hrs , and the infiltration of inflammatory cells was observed in affected areas.

diabetic wounds. *PloS one*. 2017; 12(1), e0170500.

<https://doi.org/10.1371/journal.pone.0170500>

6. Liang, D. Y., Li, X., Shi, X., Sun, Y., Sahbaie, P., Li, W. W., & Clark, J. D. The complement component C5a receptor mediates pain and inflammation in a postsurgical pain model. *Pain*. 2012; 153(2), 366-372. <https://doi.org/10.1016/j.pain.2011.10.032>
7. Abd, A . Dimerization of complement C5a receptors in inflammatory responses (Doctoral dissertation, University of Sheffield); 2017. <https://theses.whiterose.ac.uk/18150>
8. Maura, D., Bandyopadhyaya, A., & Rahme, L. G. Animal models for *Pseudomonas aeruginosa* quorum sensing studies. In *Quorum Sensing*. Humana Press, New York, NY. ; 2018. pp. 227-241. https://doi.org/10.1007/978-1-4939-7309-5_18
9. Pletzer, D., Mansour, S. C., Wuerth, K., Rahanjam, N., & Hancock, R. E . New mouse model for chronic infections by Gram-negative bacteria enabling the study of anti-infective efficacy and host-microbe interactions. *Mbio*. 2017; 8(1), e00140-17. <https://doi.org/10.1128/mBio.00140-17>
10. Sinno, H., Malhotra, M., Lutfy, J., Jardin, B., Winocour, S., Brimo, F., ... & Prakash, S. . Complements c3 and c5 individually and in

combination increase early wound strength in a rat model of experimental wound healing. *Plastic Surgery International*, 2013.

<https://doi.org/10.1155/2013/243853>

11. Triplett, A., & Hurwitz, A. A . Complement and Adaptive Immunity: Roles for the Anaphylatoxins C3a and C5a in Regulating Tumor Immunity. *International Trends in Immunity*. 2014; 2, 78-82.

<http://www.researchpub.org/journal/iti/iti.html>

12. Lu, J. D., Milakovic, M., Ortega-Loayza, A. G., Marzano, A. V., & Alavi, A. Pyoderma gangrenosum: proposed pathogenesis and current use of biologics with an emphasis on complement C5a inhibitor IFX-1. *Expert Opinion on Investigational Drugs*. 2020; 29(11), 1179-1185. <https://www.tandfonline.com/loi/ieid20>