



Protective Effect of *Petroselinum crispum*(parsley)extract on histopathological changes in liver ,kidney and pancreas induced by Sodium Valproate- In male Rats

Assistant lecture: Adnan M. Jassim

College of Veterinary Medicine, Al –Qassim Green University

Abstract:

The present study was done to investigate the protective effect parsley extract against liver ,kidney ,pancreas damage induced by sodium valproate in rats, The protective effect of alcoholic parsley extract against toxicity induced by sodium valproate (SVP) in male rats was studied. These experiment was carried out along 7 weeks, twenty four male rats divided into three equal groups. Group (1) was kept as normal control (given vehicle), while rats of group (2) were given orally SVP in a dose of 500 mg/kg /day. While group (3) protected by parsley extract dose of 200 mg/kg /day and receive orally SVP in a dose of 500 mg/kg /day for 7 weeks at end of experiment animal were scarified and tissue of liver ,kidney and pancreas were isolated for study histopathological changes .

The histopathological changes of liver reveal mild degree of steatosis reflected by micro vacuoles of the cytoplasm , Loss of normal arraying of hepatocytes indicates mild degree of liver atrophy , central vein. Focal liver necrosis, the dead cells are replaced by leukocytic infiltration .The histopathological changes of kidney tissue treated with valproate reveal The proximal and the distal convoluted tubules show hydropic changes (small white vacules within the cytoplasm) and The glomeruli show hypercellularity. More ever study reveal there is no histopathological changes could be detected in pancreas except there is interstitial edema in animal treated with valproic acid.

Conclusion: *Petroselinum crispum*(parsley) exhibited significant anti-hepatotoxic activities and protective activity on kidney damage induced by valproic acid .

Key words : valproate , parsley , liver ,kidney ,pancreas.

دراسة فعالية المستخلص الكحولي لبذور البقدونس في حمايه انسجه الكبد والكلية والبنكرياس من تأثير الفالوبريت في ذكور الجرذان

عدنان منصور جاسم

كلية الطب البيطري، جامعة القاسم الخضراء

الخلاصة:

تم في هذه الدراسة اختبار فعالية المستخلص الكحولي لبذور البقدونس في تعديل التأثيرات السمية لعقار فالوبروات ا لصوديوم في الجهاز التناسلي الذكري للجرذان، استمرت هذه الدراسة لمدة سبعة أسابيع . استخدمت في هذه الدراسة (18) من ذكور الجرذان قسمت عشوائيا إلى ثلاثة مجاميع ، المجموعة الأولى مثلت السيطرة ، والمجموعة الثانية جرعت بعقار فالوبروات ا لصوديوم بجرعة 500ملغم /كغم ، وإما المجموعة الثالثة

جرعت بعقار فالوبر وات ١ لصوديوم بجرعة 500 ملغم \كغم ، والمستخلص الكحولي لبذور البقدونس بجرعة 200 ملغم \كغم. استمرت هذه الدراسة لمدة سبعة أسابيع، وفي نهاية التجربة شرحت الحيوانات وتم عزل الكبد والكلية والبنكرياس. أوضحت المقاطع النسجية المأخوذة من الكبد المعاملة بالعقار لوحدة تضيق وضهور فجوات دقيقة في الساييتوبلازم مع فقدان ترتيب لخلايا ، حدوث ضمور في الخلايا الكبدية مع تنخر ابري وتعويض الخلايا الميتة بارتشاح الخلايا البيضاء، بينما أظهرت نتائج المعالجة بالمستخلص الكحولي لبذور البقدونس فعاليتها في إزالة التأثيرات السمية للعقار وإعادة تجديد الخلايا التالفة مع ظهور الخلايا الكبدية بشكل طبيعي ولم تظهر أي تغيرات على مستوى النسيج، في حين المقاطع النسجية المأخوذة من الكبد المعاملة بالعقار لوحدة . أظهرت تغيرات تنكسية في الأنابيب المتلوية الدانية والقاصية مع تحوي الساييتوبلازم وزيادة فرط التنسج بينما أظهرت الكلية في الحيوانات المعالجة خلايا نسجية طبيعية . من جانب آخر لم تظهر أي تغيرات مرضية على مستوى انسجه البنكرياس مما يشير إلى أن العقار ليس له تأثير على مستوى انسجه البنكرياس . لذا يوصى باستخدام مستخلص البقدونس في علاج حالات أمراض الكبد لما له من تأثيرات في أصلح الانسجه وأزاله السموم من الجسم .

الكلمات المفتاحية: فالوبروات بقدونس كلية كبد بنكرياس.

Introduction:

Epilepsy affects 5 -10 per 1000 of the general population. valproic is an eight carbon branched chain fatty acid with a broad spectrum of anticonvulsant activity, The increased clinical use of valoproate has been accompanied by reports of hepatic dysfunction and renal tubular defects (1,2,3). Valproic acid, a frequently used drug for the treatment of epilepsy, has been used worldwide (4). 5 found that theme sever hepatotoxicity associated with Valproic acid is due to depletion of β oxidation with increased synthesis of toxic unsaturated Valproic acid derivates. Another hypothesis lies in the possible However, valproic acid therapy is responsible for a number of fatal cases of hepatic failure (6). Hence the mechanism by which valproic acid causes hepatotoxicity is poorly understood.

VPA, a widely used anticonvulsant drug, induced the deterioration of trace metal homeostasis, including zinc (Zn) deficiency in experimental animals (7). Two types of serious side-effects are associated with the use of VPA: hepatotoxicity and teratogenicity (8, 9). This teratogenic effects includes neural tube.

The toxicity is apparently due to metabolites of VPA generated by w-oxidation, which is one of three major metabolic pathways of VPA. It was found that steatosis and necrosis of hepatocyte are the main histopathological changes in

liver of albino rat induced by toxic dose of Valproic acid (10). (11) studied the effect of Valproic acid on the exocrine part of pancreas when used alone and when given concomitantly with L-carnitine. When animals treated with Valproic acid alone the result obtained, showed variable degree of acinar degeneration and cellular infiltration between the acinar. According to (12), the teratogenic effects of Valproic acid on rats, was in form of abortions, reduction in the number of live fetuses and defects of the tail, rib phalanx, cytotrophoblasts and suppressed proliferation of fetal capillaries, reduced diameter nearing obliteration of umbilical vessels with or without karyorrhexis of embryonic tissue. the lesion in the placental labyrinth were specific but in the embryonic tissues they were generalized.

Parsley is a member of the Umbelliferae family that has been employed in the food, pharmaceutical, perfume, and cosmetics industries (12,13). On other hand parsley leaf is used for treatment of constipation, flatulence, jaundice, colic, edema, rheumatism, diseases of prostate and liver. It has also been used as an aphrodisiac, improved productive performance in broiler, antimicrobial, (14) ant anemic, hemorrhagic, anticoagulant, antihyperlipidemic, antihep-atotoxic and laxative (15,16). It has been used to treat lumbago, as a blood pressure regulator, to treat eczema, knee, ache, impotence and

nose bleed (17). Parsley seed are also used as a diuretic and the hypoglycemic activity of parsley has been shown by (18). The constituents of parsley which include ascorbic acid, carotenoids, flavo-noids, coumarins, apiole, various terpenoic compounds, phenyl propanoids, phthalides, furano coumarins, and tocopherol, have been chemically investigated (19). Components of fresh parsley leaf scavenge superoxide anion in vitro (20), and the methanol extracts of parsley scavenge hydroxyl radical in addition to protecting against ascorbic acid induced membrane oxidation (21).

Materials and Methods:

Plants extract

parsley seeds were collected from local market Medicinal plants in ALQassim city. Preparation of the extract

The dried seed were pulverized into fine powder using a grinder and stored in an air tight container. About 750 ml of 70% ethanol was added to 100 g of powder and kept on a mechanical shaker(magnetic stirrer)at 55 C for 72 h, the content was filtered and kept in an incubator at 37°C for 36 hrs ,The concentrated extract was stored dry at -20 in deep freeze, The percentage yield of the *parsley* 20.4% then *weighting extract by electrical imbalance*

according to dose used in this study and dissolved in D. W then shaken with until dissolved completely.

Animals:

Mature male rats of Sprague Dawley strain weighing 300-400 g b.wt. each and 12-14 week old were obtained from the Laboratory Animal Colony, koeffah university . The rats were kept under controlled hygienic conditions in plastic cages and fed on basal diet for one week before starting the experiment for acclimatization. Water was provided *ad libium*.

Experiment and grouping of rats:

Twenty four male rats were randomly divided into 4 groups, each of 6animals.

Group I: Control group- male rats received orally 0.5 ml sterile water for 7 weeks .

Group II: The animal received sodium valproate in a dose of 500 mg/kg b.wt./ day for 7 weeks

Group III : parsley 200mg/kg extract administered along with sodium valproate in a dose of 500 mg/kg b.wt./ day for 7 weeks.

At end of the experiment liver ,kidney and pancreas were isolated , under pentobarbital , then kept in 10% formalin solution pending for histopathological examination ..

Result :

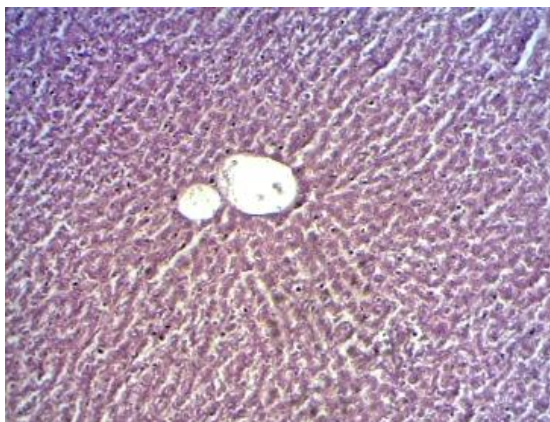

Figure1. Normal liver :This picture shows the normal liver histology. C, central vein. H, column of hepatocytes radiating from the central vein. S, liver sinusoids. E&H stain X40.

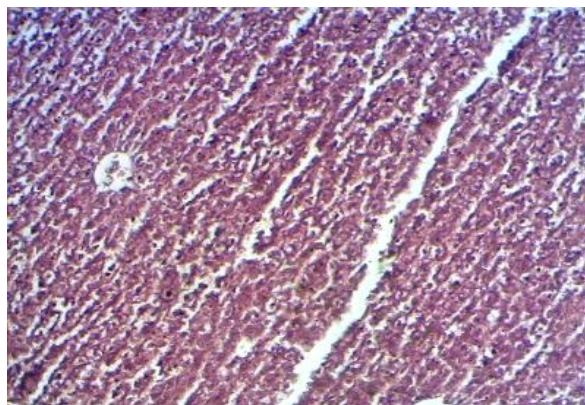


Figure 2. Liver of animal given clofibrate: The liver shows mild degree of steatosis reflected by micro vacuoles of the cytoplasm (V). Loss of normal arraying of hepatocytes indicates mild degree of liver atrophy (A). C central vein. Focal liver necrosis, the dead cells are replaced by leukocytic infiltration(L). E&H stain X40.

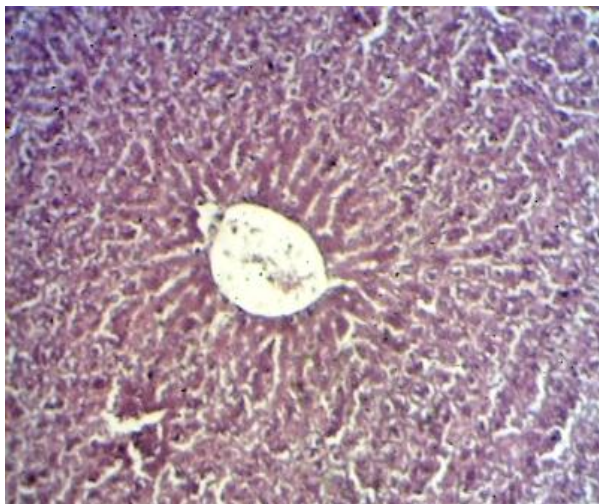


Figure 3. Liver of animals given protective substance: The liver shows no histopathological changes. The liver show normal arraying of hepatocytes from the central vein (C) forming column (H) and separated by sinusoids (s) as in figure 1. E&H stain X100.

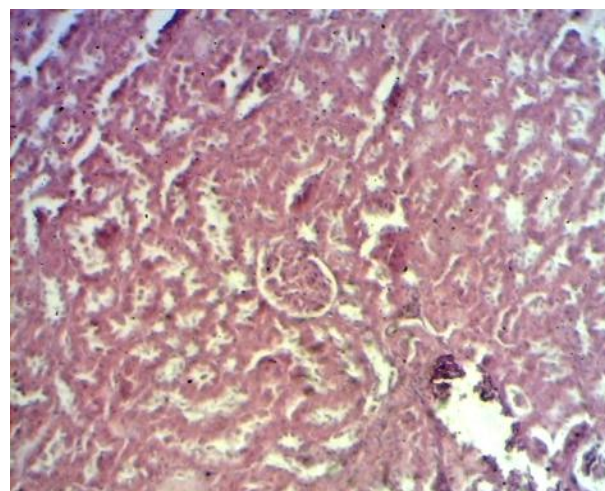


Figure 4. Kidney of control animal: The kidney shows normal histological structures consisting of glomerulus (G), proximal convoluted tubules (P) and distal convoluted tubules (D)

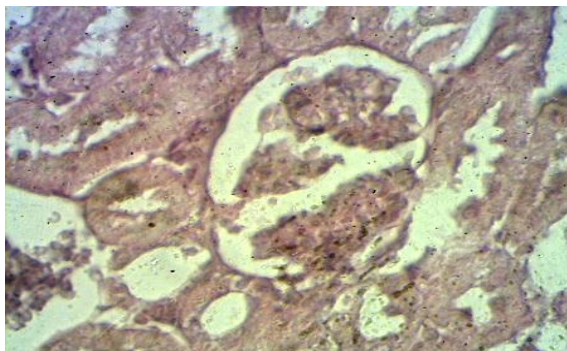


Figure 5. kidney of animal given clofibrate: The proximal (P) and the distal (D) convoluted tubules show hydropic changes (small white vacuoles within the cytoplasm). The glomeruli show hypercellularity. E&H stain X10.

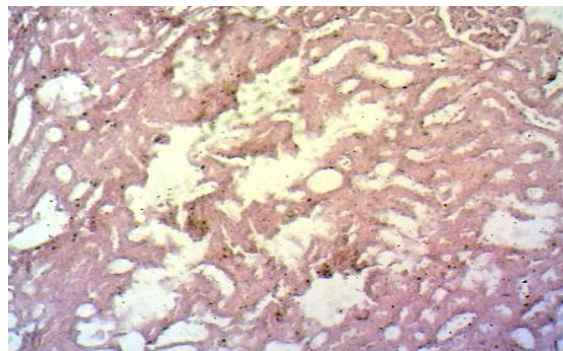


Figure 6. kidney of animal given protective substance: The kidney show normal histology; no histopathological changes could be detected. G, glomerulus. P proximal convoluted tubules. D, distal convoluted tubules

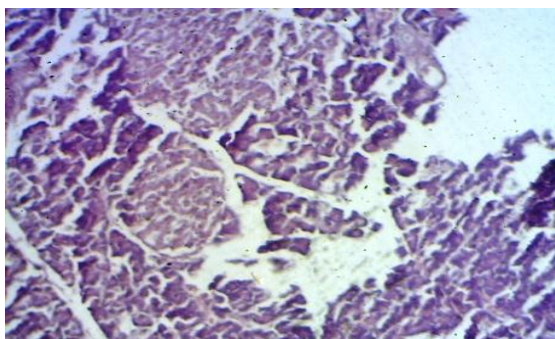


Figure 7. Pancreas of control animal :The pancreatic tissue shows the normal histologic structure composed of ; lobules (L), islet of Langerhan (IL). The pancreatic acini with dark basophilic cytoplasm

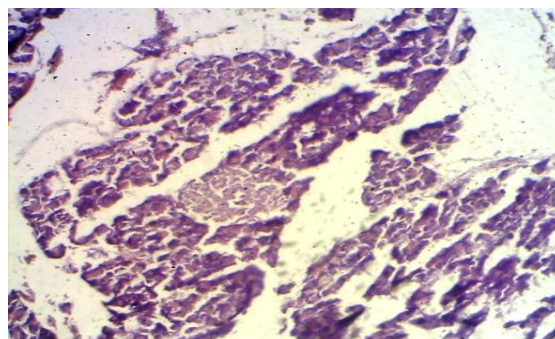


Figure 8. pancreas of animal given clofibrate : The pancreas shows no significant histological changes except there is interstitial edema (O). IL, islet of Langsrhans, A, acinus. L, lobule. IN, interstitial tissue

Discussion:

The liver tissue of Valproic acid treated for 7 weeks shows mild degree of steatosis reflected by micro vacuoles of the cytoplasm, Loss of normal arraying of hepatocytes indicates mild degree of liver atrophy, central vein. Focal liver necrosis, the dead cells are replaced by leukocytic infiltration. These results were in agreement with the finding of (22,10) : who reported the histopathological changes of toxic dose of Valproic acid in liver of albino rats, these changes represented in partly distorted in the lobular architecture, in addition to foci of inflammatory cell infiltrate focal necrosis and congestion in the portal areas, vacuolar degenerative changes, enlarged atypical hepatocytes (22,23) reported that Valproic After 30 days administration of Valproic acid, hepatocytes revealed variation in shapes and size of nucleus. This may be confirmed by (24) who reported that Valproic acid treatment caused significant nuclear alterations in normal drug-filtering organs (liver and kidney tissue), this due to the fact of Valproic act as Histone deacetylase inhibitors and promising anticancer agents that change the acetylation status of histones and loosen the chromatin structure. On the other hand histopathological changes of kidney tissue treated with valproate reveal The proximal and the distal convoluted tubules show hydropic changes (small white vacuoles within the cytoplasm) and The glomeruli show hypercellularity. While group treated with parsley show normal histology; no histopathological changes could be detected in glomerulus, proximal convoluted tubules, distal convoluted tubules. This result was in agreement with the (25) Electronmicrograph of valproic acid rat kidney Reveal degenerative changes especially in renal glomerular basal membrane and foot (26) demonstrated liver treated with SVP showed A portal

tract fibrosis expansion, with increase of ALT and AST liver enzyme. The mechanism by which VPA causes liver damage is believed to be mediated by some of its metabolites (27). VPA is metabolized primarily in the liver by three routes; cytochrome P450, fatty acid, β -oxidation and conjugation to active and inactive metabolites. Some VPA metabolites (β -oxidation) are thought to be potentially hepatotoxic (28,29).

Our study reveal there is no histopathological changes could be detected in pancreas except there is interstitial edema in animal treated with valproic acid. This result is in agreement with (30) animals treated with Valproic acid, showed variable degree of acinar degeneration and cellular infiltration between the acinar.

The efficacy of any hepatoprotective drug is essentially dependent on its capability to either reduce the harmful effects or to maintain the normal hepatic physiological mechanism which have been unbalanced by the hepatotoxin. The results of the present study revealed that the ethanolic extract of Parsley possesses significant hepatoprotective effect against experimental valproate-induced liver & kidney damage in male rats.

The antioxidant activity of parsley has been reported previously. (31) reported that parsley oil is rich in myristicin which showed a high activity as an inducer of the detoxifying enzyme GST in the liver and small intestinal mucosa of female mice. Reduction of myristicin yielded dihydromyristicin that retained the GST-inducing activity (32) indicated that parsley oil contain flavonoids (apiin, luteolin-, apigenin-glycosides), essential oil (apiol, miriszticin), coumarins, (bergapten, imperatorin) and vitamin C. (33) indicated that vitamin E and C caused partial decrease of embryo toxicity and congenital malformation induced by VPA in mice.

The protective role of parsley may be attributed to its higher content of these flavonoids and vitamin C which either scavenge free radical which aid to remove damage from liver and kidney when compared with valproate drugs. On the other hand (18) concluded that, parsley extract probably, due to its antioxidant property, has a protective effect against hepatotoxicity caused by CCL4 and diabetes and have free radical scavenging and membrane protective effects (32,33) reported a significant inhibitory effect of Parsley on experimentally induced kidney stone in laboratory animals. Moreover, parsley has a diuretic effect that aids removal of toxic material valproate from body tissue. (43) show that parsley removes toxic injury of sodium valproate on testes of male rats. On the other hand (35,36) reported ability of parsley extract to protect the hepatopancreas of fish against subacute aflatoxicosis (AFB1).

Serum lipids (TC, TG) of hypercholesterolemic rats fed on diets with either parsley were significantly lower ($P < 0.05$) compared while protective effects liver from atrophy and vacuolation of hepatocyte (37). (38) show rats treated with parsley extract significant increase in serum total protein, globulin, hemoglobin, packed cell volume and serum and kidney superoxide dismutase, glutathione-peroxidase and glutathione S-transferase.

Reference :

- 1- Toktam, F.; Agha, Adel. J. (2012): Role of Omega-3 fatty acids in preventing metabolic disturbances in patients on olanzapine plus either sodium valproate or lithium: a randomized double-blind placebo-controlled trial. *DARU Journal of Pharmaceutical Sciences* 20:43
- 2- Rodriguez, R. and Veltri, R. W. (2009): Valproic acid causes dose- and time-dependent changes in nuclear structure in

prostate cancer cells in vitro and in vivo. *Mol. Cancer Ther.*, 8 (4): 802–808

- 3- Zimmerman, H.J. and Ihsak, K.G. Valproate-induced hepatic injury: analyses of 23 fatal cases. *Hepatology*. 1982;2:591-597.

- 4- Siemes, H. and Nau, H. (1991): Valproate associated hepatotoxicity pathogenesis, clinical aspects, therapy and prevention. *Klin Padiatr.*, (6): 411-419.

- 5- Martindale. (1983): The extra Pharmacopoeia. 31st ed. London: The Royal Pharmaceutical Society, metabolism. *Arch. Biochem. Biophys.* 223:381-392.

- 6- Wiegand, T.; Osion, R. and Hern, E. (2009): Valproate toxicity. *Eur. J. toxicity*, 44:39-42.

- 7- Bosetti, F., Weerasinghe, G.R., Rosenberger, T.A., Rapoport, S.I. (2003): Valproic acid downregulates the conversion of arachidonic acid to eicosanoids via cyclooxygenase-1 and -2 in rat brain. *Journal of Neurochemistry.*, 85, 690-696.

- 8- Anita, Singh.; Tej K Bhat and Om P, Sharma. (2011): Clinical Biochemistry of Hepatotoxicity. *J Clin Toxicol Clin Pharmacology*: 2161-0495

- 9- Amrani, Amel.; Zama, Djamil.; Boubekri, Nassima.; Benaissa, Ouahiba.; Meraihi, Zahia Benayache, Fadila.; Benayache Samir and

- 10- Khan, S.; K.; Shakoor, K. A.; Jan, M. A.; Khattak, A. M. and Shah, S. H. (2005): study of histopathological changes in the liver of albino rats, induced by toxic dose of Valproic acid. *Gomal journal of medical sciences*, (3):15-18.-

- 11- Ali M Alizadeh.; Hossein Nahrevanian.; Azam Moslehiand Saleh Azizian.(2013): Protective Effect of Ghrelin on Sodium Valproate-induced Liver Injury in Rat. *Journal of Stress Physiology & Biochemistry*, Vol. 9 No. 1 2013, pp. 96-105
- 12--Khan, S. K.; Shakoor, K. A.; Jan, M. A.; Khattak, A. M.and Shah, S. H. (2005): study of histopathological changes in the liver of albino rats, induced by toxic dose of Valproic acid. *Gomal journal of medical sciences*, (3):15-18.
- 13-Yada, T., Kaiya, H., Mutoh, K., Azuma, T., Hyodo, S., Kangawa, K. (2006): Ghrelin stimulates phagocytosis and superoxide production in fish leukocytes. *Journal of Endocrinology.*, 189, 57-65.
- 14-Lopez ,MG.; Sanchez-Mendoza, I.R and Ochoa-Alejo N. (1999): Compative study of volatile components and fatty acids of plants and in vitro cultures of parsley (*Petroselinum crispum* (Mill) nym ex hill). *J. Agric. Food Chem.*, 47: 3292-3296.
- 15-Kreydiyyeh ,S.I.; Usta ,J.; Kaouk, I and Al-Sadi R. (2001): The mechanism underlying the laxative properties of parsley extract. *Phytomedicine*, 8: 382-388. .
- 16- Nielsen, S.E.; Young ,J.F.; Daneshvar, B.; Lauridsen S,T.; Knuthsen P. and Sandstrom B. (1999): Effect of parsley intake on urinary apigenin excretion, blood antioxidant enzymes and biomarkers for oxidative stress in human subjects. *British J. Nutrition*, 81: 447-455.
- 17-Manderfeld, M.M.; Schafer, H.W.; Davidson ,P.M and Zottola EA. (1997): Isolation and identification of antimicrobial furocoum-arins from parsley. *J. Food Prot.*, 60: 72-77.
- 18-Ozsoy-Sacan ,O.; Yanardag ,R.; Orak, H.; Ozgey ,Y.; Yarat, A and Tunali T. (2006): Effects of parsley (*Petroselinum crispum*) extract versus glibornuride on the liver of streptozotocin-induced diabetic rats. *J Ethnopharmacol*, 104 (1-2): 175-181
- 19-Tunali, T.; Yarat , A.; Yanardag , R.; Ozcelik ,F.; Ozsoy, O.; Ergenekon, Gand Emekli N (1999): Effect of parsley (*Petroselinum crispum*) on the skin of STZ induced diabetic rats. *Phytother. Res.* 13: 138-141.
- 20-Campanella ,L.; Bonanni, A.; Favero G. and Tomassetti M. (2003): Determination of antioxidant properties of aromatic herbs, olives and fresh fruit using an enzymatic sensor. *Analytical and Biochemistry*, 375: 1011-1016
- 21-Fejes, S.; Blazovics, A.; Lemberkovics, E.; Petri ,G.; Sz"oke E. and Kery A. (2000): Free radical scavenging and membrane protective effects of methanol extracts from *Anthriscus cerefolium* L. Hoffm.) and *Petroselinum crispum*(Mill.) nym. ex A.W. Hill. *Phytother Res.*, 14(5): 362-365.
- 22- Ibrahim,M. A(2012): Evaluation of Hepatotoxicity of Valproic acid in albino mice, Histological and Histoistochemical studies. *Life Science Journal*;9(4)
- 23-Wiegand,T.; Oslon,R. and Hern,E.(2009):Valproate toxicity. *Eur.J. toxicity*, 44:39-42.
- 24-Rodriguez, R.and Veltri, R. W. (2009): Valproic acid causes dose- and time-dependent changes in nuclear structure in prostate cancer cells in vitro and in vivo. *Mol.Cancer Ther.*, 8 (4): 802–808
- 25-Amrani Amel.; Zama Djamila.; Boubekri Nassima.; Benaissa Ouahiba.;Meraihi Zahia2 Benayache Fadila.; Benayache Samirand Bettuzzi

- Saverio. (2012).The protective effect of *Chrysanthemum fantanesii* extract, vitamin E and C on sodium valproate-induced embryotoxicity in pregnant mice Medicinal Plants Research Vol.6(19), pp. 3535-3544, 23
- 26-Mandana ,Sadeghi Niaraki.; Fatemeh, Nabavizadeh.; Gholam H. Vaezi.;Ali M Alizadeh.; Hossein Nahrevanian.; Azam Moslehiand Saleh Azizian.(2013): Protective Effect of Ghrelin on Sodium Valproate-induced Liver Injury in Rat. *Journal of Stress Physiology & Biochemistry*, Vol. 9 No. 1 2013, pp. 96-105
- 27- Shaat, E.A., Samia, M.A., Madkour, S. (2006): Effect of L-Carntine and deferoxamine on hepatotoxicity, erythrocyte ergothioneine and testicular testosterone synthesis in sodium valproate-treated rats. *Bull. Alex. Fac. Med.*, 42,123-124.
- 28 -Isharwal, S.; Kortenhorst, M. S.; van Diest, P. J.; W.H.;Chowdhury, W. H.; Marlow, C.; Carducci, M. A.;Rodriguez, R.and Veltri, R. W. (2009): Valproic acid causes dose- and time-dependent changes in nuclear structure in prostate cancer cells in vitro and in vivo. *Mol.Cancer Ther.*, 8 (4): 802–808
- 29-Tong V, Teng XW, Chang TK, Abbott FS (2005): Valproic acid I: time of lipid peroxidaion biomarkers, liver toxicity, and valproic acid metablite level in rats. *Toxicol. Sci.*, 86(2): 427-435.
- 30-EL-Deeb, T. (2006): effect of Valproic acid on the pancreatic acini of
- 32-Fejes, S.; Kery, A.; Blazovics, A.; Lugasi ,A.; Lemberkovics ,E.; Petri G. and Szoke E. (1998): Investigation of the in vitro antioxidant effect of Petroselinum crispum (Mill.) Nym. ex A. W. Hill. *Acta Pharm Hung.*, 68(3): 150-156
- 33-Reyhaneh ,Sariri.(2012). Antioxidant activity exhibited by medicinal plants, vegetables and fruits from North of Iran. *Research Signpost Trivandrum* : 205-236.
- 34- adnan.m.; musawy,E. and kutaffa, M .(2013): study the effect of alcoholic of ginseng & parsley in modulates sodium valoproate induced reproductive toicity in male rats.ALqadisya journal of vet .med .sci of 5th conference 11(3)32-44.
- 35-Wong YYP, and Kitts DD, (2006): Studies on the dual antioxidant and antibacterial properties of parsley and cilantro extracts. *Food Chem.* 97: 505-515.
- 36- EL- Barbary ,B.; mehrim, A. (2009): protective effect of antioxidant medicinal herbal rosemary and parsley ,on sub acute aflatoxicine in oreochromis niloticus. *Journal of fisheries and aquatic science* 4(4): 178-190 .
- 37- El-Kherbawy, G.M.; . Ibrahim , E.S and S.A. Zaki.(2011)Effects of Parsley and Corianderleaves on hypercholesterolemic rats. The 6th Arab and 3rd InternationalAnnual Scientific Conference on: 1227 -1240.
- 38- Nabila M. Rashwan .(2012) : Biological Study on the Effect of Arginine Parsley and on Renal Toxicity in Rats. *World Journal of Medical Sciences* 7 (4): 264-269.