

The possible cardioprotective effect of valsartan in the amelioration of myocardial I/R injury induced by ligation of coronary artery in a rat model

Najah Rayish Hadi^a, Fadhil Ghaly Yousif^B Suhaad Traiji zamil^c,
^DYasmeem Ali Hussien

^A Department of Pharmacology and Therapeutics, College of Medicine, Kufa University, Iraq

^B Department of cardiovascular surgery, College of Medicine, Kufa University, Iraq

^c Department of Pharmacology, College of pharmacy, Basrah University, Iraq

^D Department of Pharmacology and Therapeutics, College of Medicine, Kufa University, Iraq

Abstract

Ischemia/reperfusion injury describes the experimentally and clinically prevalent finding that tissue ischemia with inadequate oxygen followed by successful reperfusion initiates a wide and complex array of inflammatory responses that may aggravate local injury as well as induce impairment of remote organ function by mechanisms that involves oxidative stress, inflammation, and apoptosis. In this study, we investigated the cardio protective effects of Valsartan in regional ischemia/ reperfusion injury. adult male Albino rats were randomized into 4 equal groups. Group (1) sham group: rats underwent the same anesthetic and surgical procedure as the control group except ligation of LAD coronary artery , Group(2) control group: rats subjected to regional ischemia for 25 min by ligation of LAD coronary artery and reperfusion for 2 hours ,Group(3) control vehicle group: rats received (normal saline) vehicle of valsartan via I.P injection and subjected to regional ischemia for 25 min and reperfusion for 2 hours , Group(4) valsartan treated group : rats pretreated with valsartan 10mg/kg I.P 30 minutes before ligation of LAD coronary artery then subjected to the surgical procedure with ligation of LAD for 30 minutes followed by 120 minutes reperfusion. At the end of reperfusion, Heart was divided into two parts, the apex for histopathology and the remaining part used for determination of tissue TNF- α , and IL-6 It has been found that Valsartan treated group showed significant reduction ($P < 0.05$) in TNF α with respect to the control groups. Histopathology study revealed that the treatment with Valsartan significantly ($P < 0.05$) improved cardiac injury as compared with control groups, we concluded that Valsartan reduces inflammatory reaction associated with ischemia/reperfusion injury induced by LAD ligation in addition to its reduction for cardiac injury induced by ischemia reperfusion.

تأثير الوقائي للقلب المحتمل للvalsartan في تحسن عضلة القلب جراء نقص الأرواء وإعادة إعادته
لعضلة القلب من الإصابة الناجمة عن ربط الشريان التاجي في ذكور الجرذان.

نجاح رايش هادي فاضل غالي يوسف سهاد تريجي زامل ياسمين علي حسين.

الخلاصة

يمثل نقص أرواء عضلة القلب وإعادة الأرواء مشكلة ذات صلة سريريته بأن نقص تروية الأنسجة مع عدم كفاية الأكسجين يليه ضحه الناجح يبدأ مجموعة واسعة ومعقدة من العمليات الالتهابية التي قد تؤدي إلى تقادم

الإصابة المحلية وكذلك تحت على ضعف وظيفة الأجهزة الأخرى عن طريق الآليات التي تتطوي عليها مثل الأكسدة والالتهابات وموت الخلايا المبرمج. أجريت هذه الدراسة لمعرفة الدور الوقائي المحتمل للفالسارتان في تحسين حالة الإصابة الموضعية بالنقص القلبي بأمدادات الدم وإعادة الأرواء لعضلة القلب الناجمة عن ربط الشريان التاجي الأمامي الأيسر النازل في ذكور الجرذان. تم استخدام أربعة وعشرون ذكراً بالغاً من الجرذان السويسريه البينضاء في هذه الدراسة وقد تم توزيعهم بصورة عشوائية إلى أربع مجاميع متساوية: 1-مجموعة النظاهر: وهي المجموعة التي مرت بنفس ظروف التخدير وخطوات التجربة لكن لم تجري عليها عملية ربط الشريان التاجي الأمامي الأيسر النازل، 2-مجموعة السيطرة (الغير معالجة): وهي المجموعة التي تعرضت إلى الإصابة القلبية بنقص الأرواء الدموي لمدة 30 دقيقة عن طريق ربط الشريان التاجي الأمامي الأيسر النازل وإعادة الأرواء لمدة ساعتين 3-مجموعة المذيب: وهي المجموعة التي حققت بمحلول ملحي 0.9% مذيب للفالسارتان داخل تجويف البريتون و تعرضت إلى الإصابة القلبية بنقص الأرواء الدموي لمدة 30 دقيقة عن طريق ربط الشريان التاجي الأمامي الأيسر النازل وإعادة الأرواء لمدة ساعتين 4- المجموعة المعالجة بالفالسارتان: وهي المجموعة التي حققت بالفالسارتان بجرعة (10ملغم/كغم) داخل تجويف البريتون قبل نصف ساعة من عملية ربط الشريان التاجي الأمامي الأيسر النازل وإعادة الأرواء لمدة ساعتين. في نهاية التجربة قسم القلب إلى قسمين القسم الأعلى لفحص النسيج والقسم الأسفل لقياس مستوى TNF- α و IL-6. أظهرت النتائج أن المستوى إلى TNF- α و IL-6 قد ازدادا معنوياً ($p < 0.05$) في مجموعة التحكم، أما النتائج النسيجية بعد عملية ربط الشريان التاجي الأمامي الأيسر النازل الأيسر فقد أظهرت أن جميع قلوب الجرذان قد تضررت معنوياً ($p < 0.05$). وقد وجد أن المجموعة التي تلقت العلاج بالفالسارتان أظهرت انخفاضاً كبيراً في مستوى TNF- α و IL-6 مقارنة مع مجموعة التحكم. من خلال نتائج هذه الدراسة يظهر بأن الفالسارتان يحسن من ضرر القلب الناتج لدى الجرذان التي تعرضت إلى عملية ربط الشريان التاجي الأمامي النازل الأيسر المسببة للإصابة بالنقص القلبي بالإرواء الدموي/ إعادة الأرواء

Corresponding author Email: yas.ali50@yahoo.com

keyword: ischemia reperfusion injury, Valsartan.

Introduction

Although restoration of blood flow to an ischemic organ is essential to prevent irreversible cellular injury, reperfusion may enhance tissue injury in excess of that produced by ischemia alone⁽¹⁾. Ischemia contributes to the pathophysiology of many conditions including myocardial infarction, peripheral vascular insufficiency, stroke and hypovolemic shock. The major mechanisms of Ischemic reperfusion injury are oxidative stress (mainly oxygen-free radicals), apoptosis, neutrophil-endothelium interactions, and hypercontracture (i.e., myocyte Ca²⁺ Over loading), endothelial cell activation with microvascular dysfunction, and altered myocardial metabolism. Ischemic reperfusion injury prompts a release of cytokines and other proinflammatory mediators that activate both the neutrophils and the coronary vascular

endothelium. Adaptive cellular responses activate the innate immune system with its Toll-like receptors (TLRs) and the complement system as well as the adaptive immune system.

Valsartan is a potent, nonpeptide tetrazole derivative and selectively inhibits Angiotensin II Receptor type 1⁽²⁾. The selective AT1 receptor blocker (ARB) exerts a variety of pleiotropic effects, including anti-oxidative, anti-apoptotic, and anti-inflammatory effects⁽³⁾. Navalkar *et al.*, (2001) found that cardioprotective effects of valsartan (ARBs) related to mechanisms beyond blood pressure lowering, anti-inflammation, anti-atherosclerosis, target organ protection⁽⁴⁾.

Valsartan inhibited TLR4 and NF- κ B expressions concomitant with an improvement in myocardial injury, such as smaller infarct size, fewer

release of myocardial enzymes, and proinflammation mediators. **Varagic et al.,(2008)** suggested that valsartan plays essential role in the protective effects on myocardial I/R injury and the possible protection mechanism is due to its anti-inflammation function via TLR4/NF-kB signaling pathway⁽⁵⁾.

Materials And Methods

A total of 28 adult male albino rats weighting (200-250 g) were purchased from Animal Resource Center, National Center for Drug Control and Research. They were housed in the animal house of Kufa university/ College of Medicine in a temperature-controlled ($25^{\circ}\pm 1^{\circ}\text{C}$) room (humidity was kept at 60–65%) with alternating 12-h light/12-h dark cycles and were allowed free access to water and chow diet until the start of experiments.

Study Design

After the two week of acclimatization 28 rats were randomized into 4 groups, 7rats in each group as follow:

In Group I:(Sham) rats underwent to the same anesthetic and surgical procedure but without ligation of Left Anterior Descending (LAD).

In Group II:control group ; rats underwent Myocardial ischemia for 30 minutes by ligation of (LAD) & reperfusion fore 2 hr.

In Group:III : (vehicle group):rats pretreated with normal saline(vehicle for Valsartan) was given intraperitoneal injection at 30 minutes before ligation of LAD & reperfusion fore 2 hr

In Group:IV (Valsartan pretreated I/R group) rats pretreated via Valsartan 10mg/Kg/ dissolved in saline solution⁽⁶⁾ intraperitoneal injection at 30 minutes before ligation of LAD & reperfusion fore 2 hr. bosentan prepared immediately before injection.

Surgical ligation of the LAD

All rats were anesthetized by intraperitoneal (IP) injection of 100 mg/kg ketamine and 5 mg/kg xylazine⁽⁷⁾. After intubation of the trachea by a 20 fg cannula and the endotracheal tube was connected tightly to the ventilation machine. The ventilation rate was fixed from 120-135 breath/minute with tidal volume 20 ml/kg body weight, with 100% oxygen. The intercostal muscle layer was gradually cut with micro fine scissors After that the pericardium was opened the left ventricle was visible , the LAD was ligated with an 8-0 Prolene suture. The chest wall was closed and at the end of reperfusion time, the animal was re-anesthetized by (IP) mixture of 100 mg/kg ketamine and 5 mg/kg xylazine and the chest was re-opened then the right ventricle was punctured with a syringe needle so that about 3 ml of blood was aspirated for later blood analysis. After that, the heart was isolated and divided into 2 pieces , the apical part used for histological examination and the basal was used for measuring the tissue parameters .

Samples Collection

At the end of reperfusion, blood was collected from the ventricles at the apical side. Hearts were cut from their main arteries (aorta and pulmonary artery), rinsed with normal saline to remove any blood, and stored in deep freeze (-20°C to -80°C).

The ventricles were cut from the atrioventricular junction and divided into two parts, lower (apical) and upper parts. The apical parts of the heart was further divided into two parts, one part used for apoptosis study while the other part was fixed in 10% formalin and processed by routine histological methods and embedded in paraffin blocks⁽⁸⁾. For subsequent histological

examination, 5µm-thick horizontal sections were cut and stained with haematoxylin-eosin (H&E).

Samples Preparation

Preparation of Sample for TNF- α and IL-6

The upper parts of the ventricles were washed with cold normal saline to remove any blood, stored in deep freeze (-20°C), and then homogenized with high intensity liquid processor in 1:10 (w/v) phosphate buffered saline that contain 1% triton X-100 and protease inhibitor cocktail (**15**). The homogenate was centrifuged with 2,500 g at 4°C for 20 min. The supernatant was collected and used in TNF- α determination.

Statistical Analysis

Statistical analyses were performed using SPSS 20.0 for windows 7 (IBM,

USA). Data were expressed as mean \pm SEM unless otherwise stated. One way Analysis of Variance (ANOVA) was used for multiple comparisons among all groups. In all test; $P < 0.05$ was considered statistically significant.

Results

Valsartan reduced myocardial inflammatory response

The levels of myocardial cytokines (TNF- α and Il-6) were found to be significantly elevated ($P < 0.05$) in control group (II) and control vehicle (III) compared with sham group (I). At the same time, cardiac cytokine (TNF- α and Il-6) were significantly decreased ($P < 0.05$) in Valsartan treated group (IV) with respect to both control and control vehicle groups, (Figure 1) and (Figure 2).

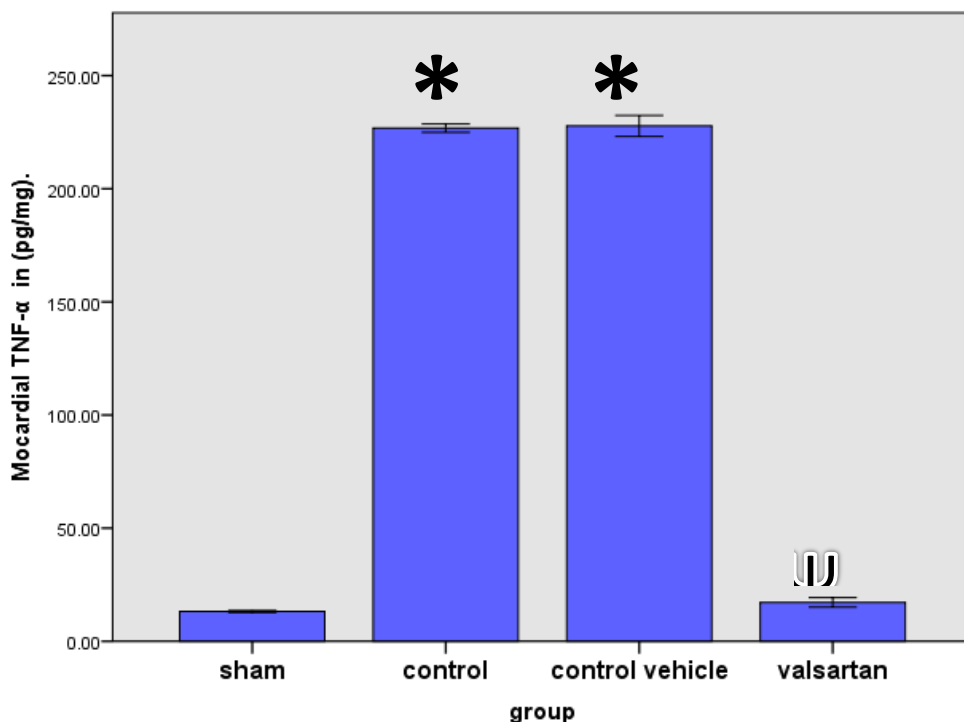


Figure 1: Mean cardiac level of TNF-α in (pg/mg). * vs. sham group, ^ψ vs. control vehicle group

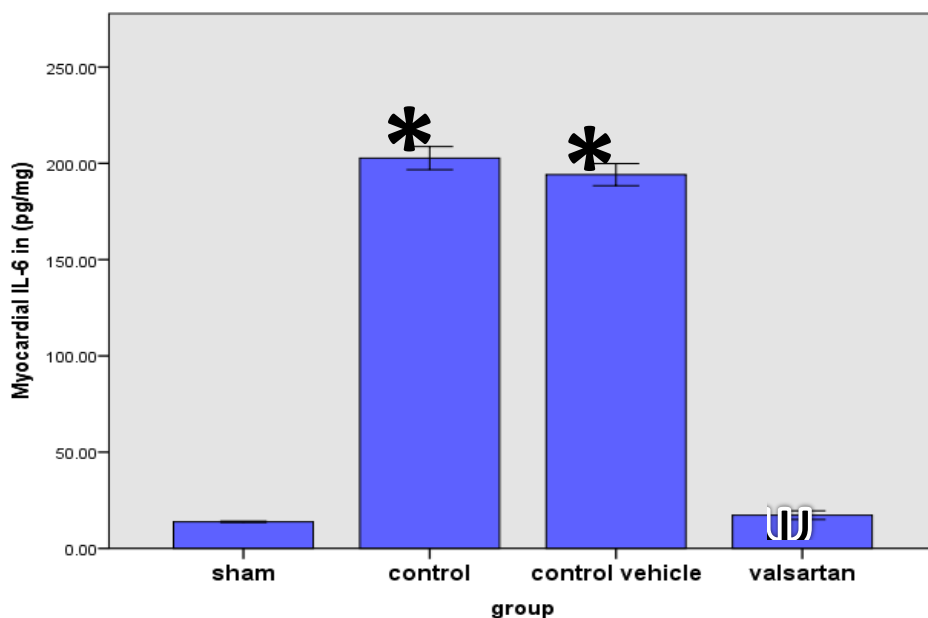


Figure (2): mean of myocardial IL-6 level (pg/mg) .* vs. sham group, ^ψ vs. control vehicle group .

Histopathological Findings

A cross- section of heart tissue obtained from the sham group showed normal cardiac structure (score 0); no interstitial edema, no diffuse myocardial cell swelling and necrosis, no neutrophils infiltration, no hemorrhage, no capillary compression and no evidence of apoptosis. There was statistically significant difference between control group and sham group ($P < 0.05$) and the total severity scores of control group showed that 28.6% of the group had severe cardiac injury(score3), 28.6% had moderate cardiac injury(score 2) and 42.8% had a highly severe cardiac injury(score 4). There was statistically insignificant

difference between control group (II) and control vehicle (III) and the total severity scores of control vehicle group (III) showed injury showed that 14.3% of the group had moderate cardiac injury, 57.1% had severe cardiac injury and 28.5% had a high severe cardiac injury. Treatment of Rat with Valsartan improved cardiac injury significantly ($P < 0.05$) as compared with control vehicle (III) group and the total severity scores of this group showed that 14.3% of the group had no damage(score0) and 57.1% had mild cardiac injury (score 1) and 28.5% had moderate cardiac injury(score 2) , As shown in figure (3).

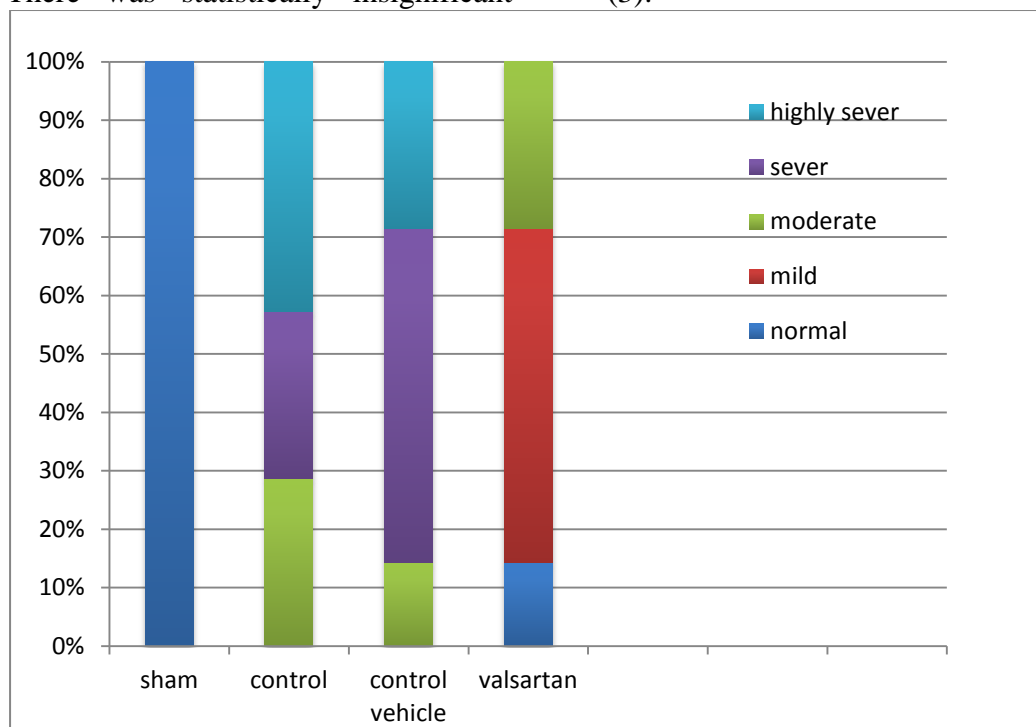


Figure 3. Component bar chart the relative frequency of different histopathology grading of abnormal heart changes among the four experimental groups.

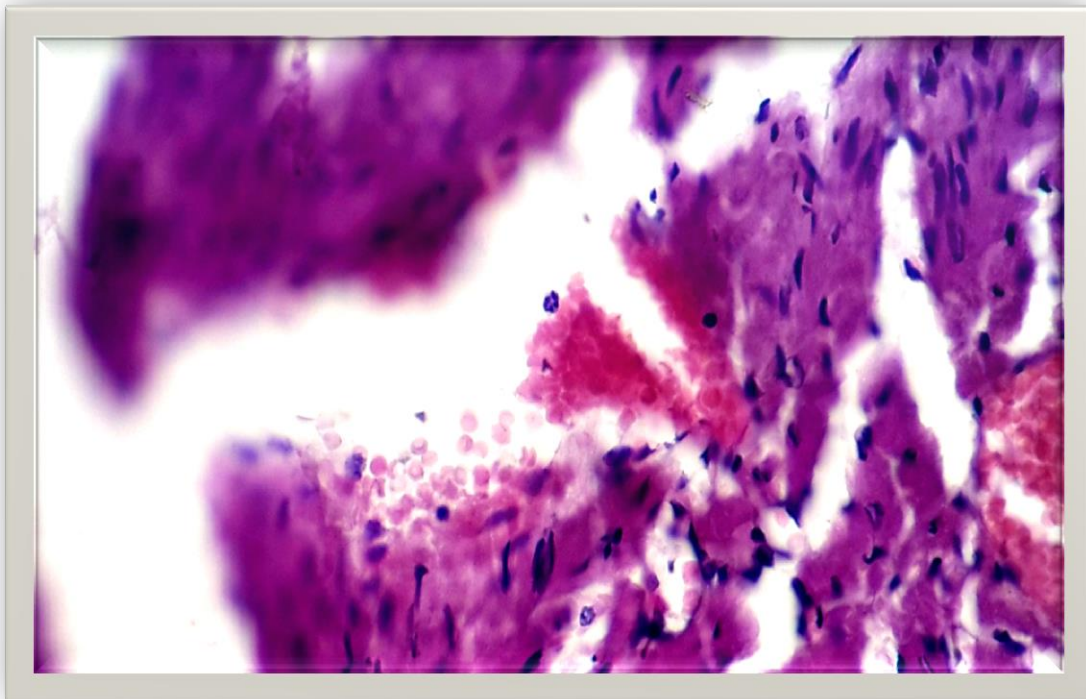


Figure (5): section for the cardiac tissue from the active control group showing sever hemorrhage ,interstitial edema and neutrophil infiltration.The section stained with Haematoxylin and Eosin (X 40)

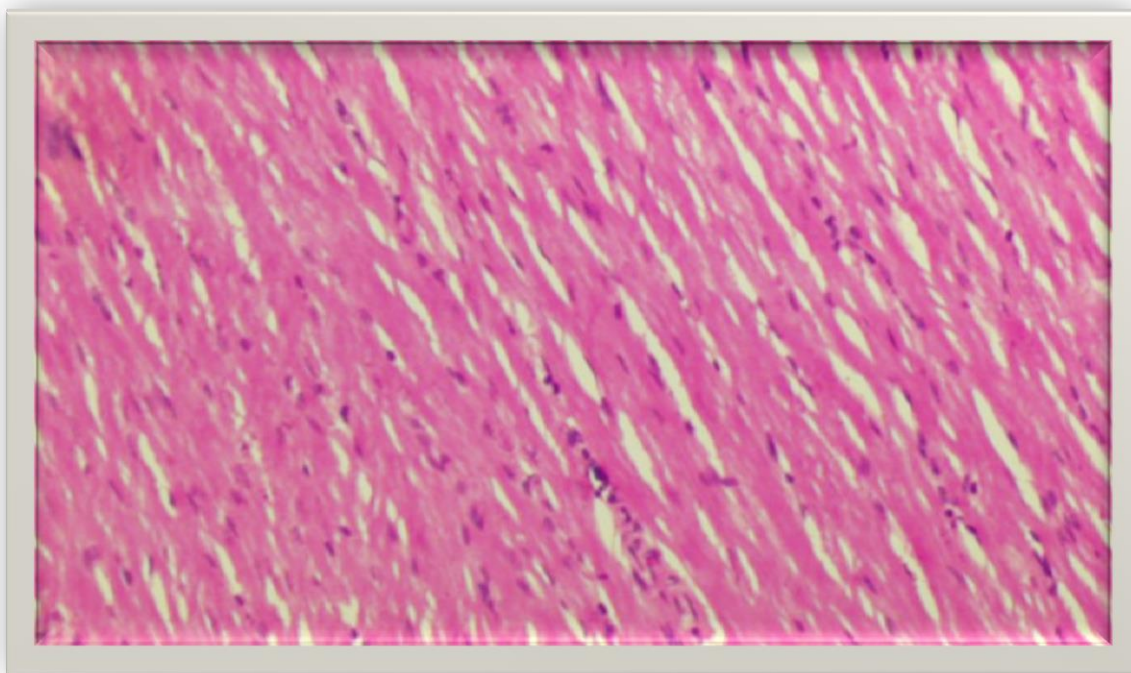
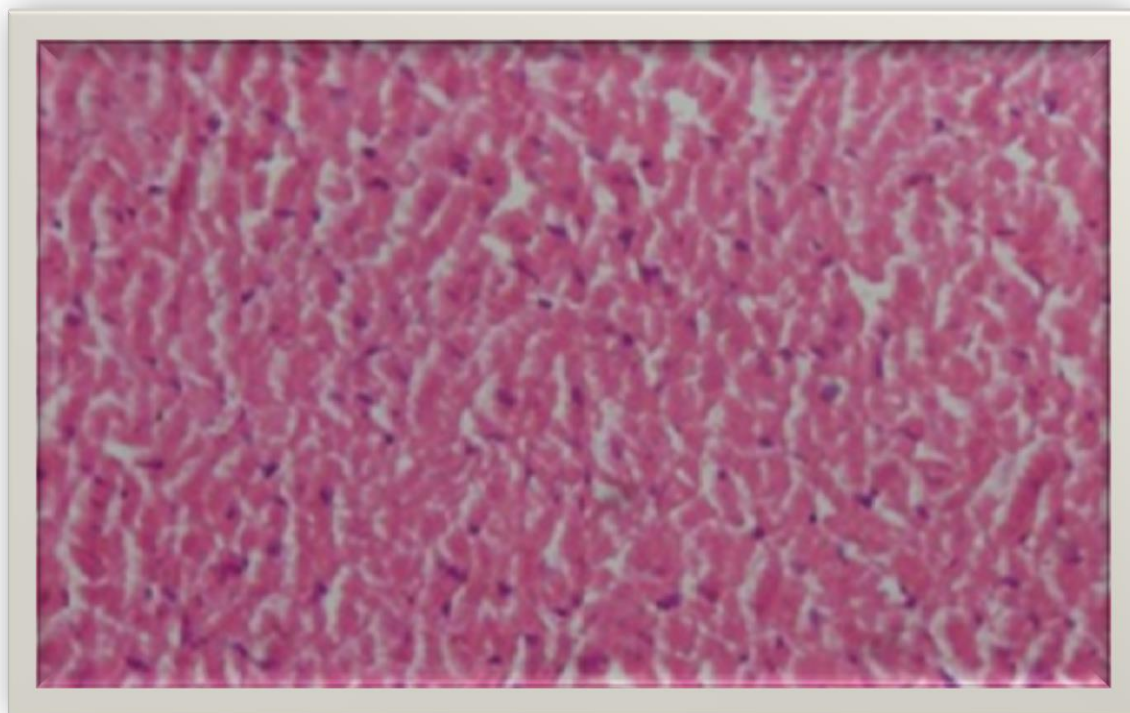


Figure (4) section from the cardiac tissue from the sham group clarifying the normal architecture . This section was stained with H&E (X 40).



Figure(8): section for the cardiac tissue from the Valsartan treated group. The section show mild cardiac injury. the section stained with Haematoxylin and Eosin (X 40)

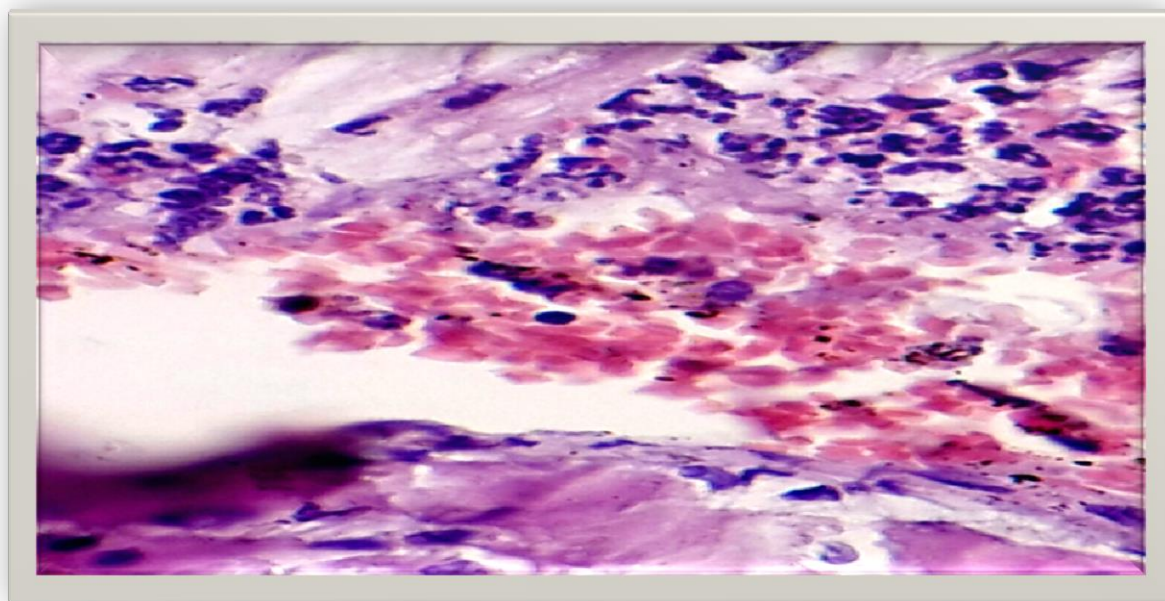


Figure (7): section of cardiac tissue for the control vehicle group showed hemorrhage,heavy neutrophil infiltration , odema and necrosis.The section stained with Haematoxylin and Eosin (X 40)

Discussion

As show in the results, pretreatment with Valsartan (group IV) significantly ($P < 0.05$) reduced the inflammatory cytokine (TNF- α , IL-6) levels when compared to the control group (II) and control vehicle group (III).

Valsartan is ARB, angiotensin II type 1 receptor involved in TNF- α Production. In the rat, early, short-term AT 1 receptor blockade limited post-infarct cardiac TNF- α production and diminished myocardial alterations observed after myocardial infarction. Also, Valsartan inhibited TLR4 and NF- κ B expressions concomitant with an improvement in myocardial injury, such as smaller infarct size, fewer release of myocardial enzymes, and proinflammation mediators. These findings suggest that valsartan plays a pivotal role in the protective effects on myocardial I/R injury. This protection mechanism is possibly due to its anti-inflammation function via TLR4/NF- κ B signaling pathway.

Wu *et al.* (2001) found that Valsartan attenuated the expression of MCP-1, TNF- α , IL-6, IL-1 β , and infiltration of leukocytes and macrophages in the injured arteries⁽⁹⁾. The present study is in agreement with Wu *et al.* (2013) Valsartan inhibited of NF- κ B translocation to nucleus and decreased plasma TNF- α levels⁽¹⁰⁾.

Li *et al.*, (1999) observed that the effect of Ang II were significantly attenuated by a specific AT1R blocker, indicating and that it is the AT1R activation mediates the pro-apoptotic effects of Ang II⁽¹¹⁾.

Treatment of rat with valsartan improved cardiac injury significantly as compared with control group and the total severity score of this group showed a mild cardiac injury.

Wu *et al.* (2013) demonstrated that The ratio of ischemia-reperfusion induced infarct size was significantly reduced in the Valsartan treated group⁽¹⁰⁾.

Yang *et al.* (2009) showed that valsartan caused significantly less severe myocardial injury and inflammatory cells infiltration⁽¹²⁾.

References:

- 1-Muller V, Losonczy G, Heemann U, Vannay A, Fekete A, Reusz G, et al. Sexual dimorphism in renal ischemia-reperfusion injury in rats: possible role of endothelin. *Kidney Int.* 2002;62(4):1364-71.
- 2.Saydam M, Takka S: Bioavailability File: Valsartan. *FABAD J. Pharm. Sci.* 2007; 32: 185 - 196.
3. Jung KH, Chu K, Lee ST, Kim SJ, Song EC, Kim EH, et al. Blockade of AT1 receptor reduces apoptosis, inflammation, and oxidative stress in normotensive rats with intracerebral hemorrhage. *J Pharmacol Exp Ther.* 2007;322(3):1051-8.
4. Navalkar S, Parthasarathy S, Santanam N, Khan BV. Irbesartan, an angiotensin type 1 receptor inhibitor, regulates markers of inflammation in patients with premature atherosclerosis. *J Am Coll Cardiol.* 2001;37(2):440-4.
5. Varagic J, Frohlich ED, Susic D, Ahn J, Matavelli L, Lopez B, et al. AT1 receptor antagonism attenuates target organ effects of salt excess in SHR without affecting pressure. *Am J Physiol Heart Circ Physiol.* 2008;294(2):H853-8.
6. Jugdutt BI, Menon V. Upregulation of angiotensin II type 2 receptor and limitation of myocardial stunning by

angiotensin II type 1 receptor blockers during reperfused myocardial infarction in the rat. *J Cardiovasc Pharmacol Ther.* 2003;8(3):217-26.

7. Wiedemann D, Schneeberger S, Friedl P, Zacharowski K, Wick N, Boesch F, et al. The fibrin-derived peptide B beta (15-42) significantly attenuates ischemia-reperfusion injury in a cardiac transplant model. *Transplantation.* 2010;89(7):824-9.

8. Bancroft J.D., and Stevens A. *Theory and practice of histological techniques.* Churchill Livingstone. Melbourne 1982; 2:125.

9. Wu L, Iwai M, Nakagami H, Li Z, Chen R, Suzuki J, et al. Roles of angiotensin II type 2 receptor stimulation associated with selective angiotensin II type 1 receptor blockade with valsartan in the improvement of inflammation-induced vascular injury. *Circulation.* 2001;104(22):2716-21.

10. Wu B, Lin R, Dai R, Chen C, Wu H, Hong M. Valsartan attenuates oxidative stress and NF-kappaB activation and reduces myocardial apoptosis after ischemia and reperfusion. *Eur J Pharmacol.* 2013;705(1-3):140-7.

11. Li D, Tomson K, Yang B, Mehta P, Croker BP, Mehta JL. Modulation of constitutive nitric oxide synthase, bcl-2 and Fas expression in cultured human coronary endothelial cells exposed to anoxiareoxygenation and angiotensin II: role of AT1 receptor activation. *Cardiovasc Res* 1999. Jan;41(1):109-15.

12. Yang J, Jiang H, Yang J, Ding JW, Chen LH, Li S, et al. Valsartan preconditioning protects against myocardial ischemia-reperfusion injury through TLR4/NF-kappaB signaling pathway. *Mol Cell Biochem.* 2009;330(1-2):39-46.