

## Some Toxic Effects of Potassium Dichromate on Liver and kidney cortex of adult male rabbits

Mohammed Abdulrazzaq Assi

College of health and medical technology

Community health department

[razaq\\_assi@yahoo.com](mailto:razaq_assi@yahoo.com)

### Abstract

Twenty four mature adult male rabbits were divided into three groups, each group was involved eight rabbits. The experiment period was reached to six weeks. Administration route of potassium dichromate was orally via drinking water. The first group represented control group. The second treated group was administrated 50mg/kg.Bw. Of potassium dichromate, while the second treated group was administrated 60mg/kg.Bw. Of potassium dichromate. (The present work symptoms on treated groups were appeared as depression), loss of appetite, followed by hyper salivation, lacrimation and diarrhea. The liver tubules of first treated group showed fatty degeneration and intracytoplasmic vacuolization of hepatocyte, while the kidney cortex was revealed glomerulonephritis in some glomeruli, interstitial connective tissue oedema, and degeneration and necrosis in the epithelial lining of proximal and distal convoluted tubules in the first and second treated groups. On the other hand, the liver lobules of rabbit was belonged to second treated group revealed polymorphic nuclear leukocytic infiltration which surrounded the central vein, as well as sever fatty degeneration in the hepatocytes due to effect of potassium dichromate at dose 60ml/kg.B.w, this dose led to sever congestion in the branches of renal vessels in the kidney cortex of rabbits.

**Keyword:** potassium dichromate, liver, kidney cortex.

### بعض التأثيرات السمية للبوتاسيوم دايكرومات على الكبد وقشرة الكلية لذكور الارانب البالغة

م.م. محمد عبد الرزاق عاصي

كلية التقنيات الصحية والطبية/ كوفة

قسم صحة مجتمع

[razaq\\_assi@yahoo.com](mailto:razaq_assi@yahoo.com)

### الخلاصة:

قسم اربعة وعشرون ارنباً بالغاً الى ثلاث مجموعات، تضم كل مجموعة ثمانية ارانب وصلت مدة التجربة الى ستة اسابيع. كانت طريقة اعطاء بوتاسيوم دايكرومات عن طريق الفم بماء الشرب. مثلت المجموعة الاولى مجموعة سيطرة. اعطيت المجموعة الثانية 50ملغم/كغم من وزن الجسم، بينما اعطيت مجموعة المعاملة الثانية 60ملغم/كغم من وزن الجسم لمادة البوتاسيوم دايكرومات. ظهر علامات على ارانب الدراسة الحالية تمثلت بالانحطاط، وفقدان الشهية، تبعت زيادة في افراز اللعاب، وافراز الدموع، والاسهال. شوهد الفصيص الكبدى لمجموعة المعاملة الاولى بحدوث تنكس دهني، وتفجى داخل الهيولى الخلايا الكبدية بينما اظهرت قشرة الكلية

التهاب الكبدية لبعض الكبيبات، ووذمة في الانسجة الضامة البينية وتخر وتكس في الظهر المبطنة للنيبات المتلوية الدانية والقاصية لقرشرة الكلية لمجموعات المعاملة الاولى والثانية، من ناحية اخرى، فان الفصييص الكبدي الذي يعود لارانب المجموعه المعاملة الثانية، لوحظ ارتشاح لخلايا الدم البيض عديدة النوى والتي تحيط حول الوريد المركزي، علاوة على تنكس دهني شديد في الخلايا الكبدية بسبب تأثيره البوتاسيوم داكرومات بجرعة 60ملغم/كغم من وزن الجسم، وهذه الجرعة ادت الى احتقان شديد في فروع الاوعية الدموية الكلوية لقرشرة كلية الارانب.

### Introduction:

Chromium compounds are present in two kinds; trivalent Cr (III) is weak transmitted across membranes and hexavalent Cr (VI) cross through cellular membranes (1). Trivalent kind complexes with intracellular macromolecules, these toxic compounds are responsible for many toxic and mutagenic effects of chromium (2). Chromium compounds are used in metal finishes, paints and stainless steel (3). Increased utilization of hexavalent chromium and improper disposal lead to various health hazard (4). Chromium in a small doses is represented an important nutrient responsible for carbohydrate metabolism (5). The health effects of exposure to chromium are correlated to it is valence and solubility, and to the exposure pathway, exposure level and particle size (6). The respiratory tract is the major target organ for chromium (VI) following inhalation exposure in human (7). Occupational exposure to chromium compounds has been studied in the chromate production, chrome-plating and chrome pigment, ferrochromium production, gold mining, leather tanning and chrome alloy production industries, workers in the chromate industries are exposure to lung cancer (8). There is limited data on the neurotoxicity of chromium (VI). In rats, decreased motor activity and pondered balance were noticed following a four weeks exposure to 100mg Cr (VI)/ kg/ daily as sodium chromate in drinking water (9). Available information suggest that chromium (VI) can adversely affect the male reproductive system, these effects involved decreases in the testicles, and some accessory glands

weights, decreased sperm counts, sperms deformities and change in sexual behavior (10). Hexavalent chromium in the presence of glutathione has been demonstrated to produce genotoxic DNA adducts that inhibit DNA replication and are mutagenic (11). The available human and animal information provide strong evidence that the acute exposure to high level may result in kidney failure (12). The aim of present study is to investigate the histological change in the liver and kidney cortex of rabbits were exposed to different doses of hexavalent chromium.

### Material and methods:

(24) Healthy mature adult male rabbits, breed and maintained in animal house of kufa Education College were used in the present study. They were fed with standard pellet diet and water and libitum. The animals were used in each experiment approximately of the same age (4-6 months), the mean of total body weight of all rabbits (1045 gm.).

The animals were divided randomly into three groups, each group with eight animals period of the study extended to six weeks, the route of administration, orally through drinking water. The first group is control group given distilled water. The second treated group was administrated (50 mg/kg.Bw.) of potassium dichromate in drinking water daily for experiment period six weeks, while the third group was administrated (60mg/kg.B.w.) of potassium dichromate dissolved in drinking water/ daily. The experiment analysis was involved histo-pathological changes of liver and kidney cortex.

For tissue processing, liver and kidney were removed from sacrificed animal, clean from adipose connective tissues, these organs were excised and fixed in (10%) formaldehyde, then the histological specimens were dehydrate in the serial graduate of ethyl alcohol concentrations (50%, 70%, 80%, 90%, 100%), after that clearing in xylol, and embedded in paraffin, the blocks of histological specimens were sectioned at (six) micrometers by using rotatory microtome, the histological sections were stained by heamatoxy and eosin (13).

#### **Results and discussion:**

There is relationship among workers health and the amounts of industrial pollution provoked by industries manufacturing chromium containing materials. So, numerous and different in vitro and in vivo studies on chromium have been undertaken either in animals or in human being (14).

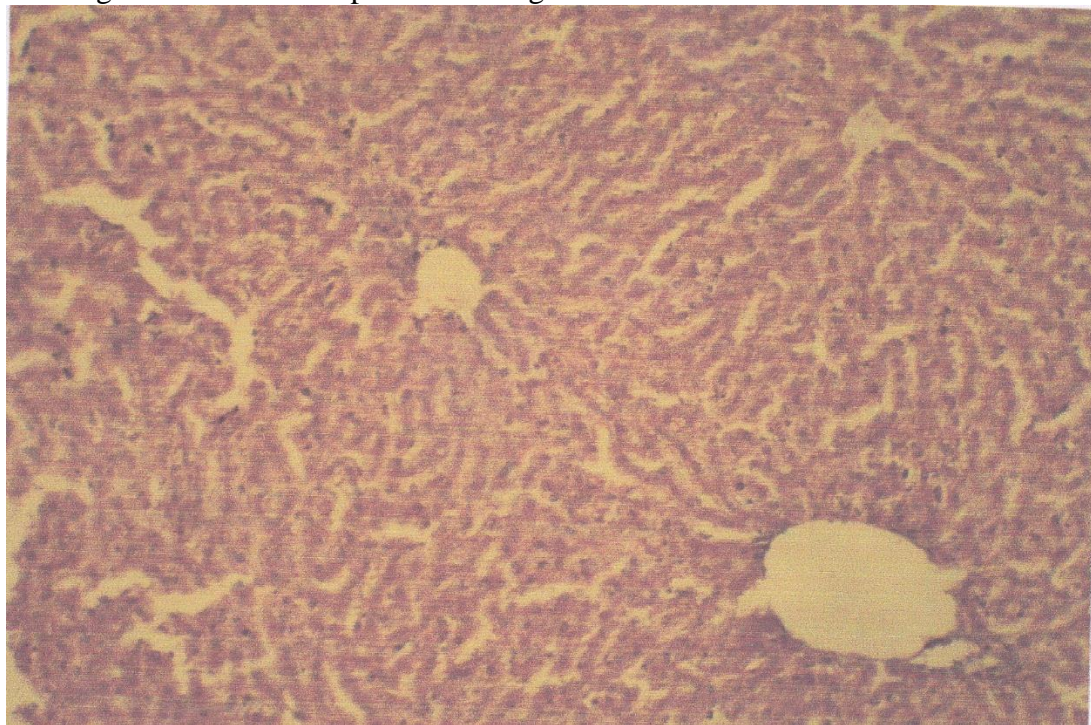
The present study symptoms were appeared initially as loss of appetite and depression, followed by hyper salivation, lacrimation and diarrhea during first hour of administration and persist up to six hours, the animals remained exhausted and fine muscular tremor up to (12) hours, some of toxic symptoms of chromium exposure may be similar with observations of previous studies (15) who stated that exposure to high level dose of chromium might result in damage to the mucous membranes in digestive tract, clinical symptoms were represented by vomiting and diarrhea followed by liver and kidney failure, and cardiovascular shock followed by liver and kidney necrosis (16). The normal histological structure of rabbit liver lobule was composed hepatic cords consist of hexagonal (cuboidal) epithelial cells which radiated from central vein (branch from hepatic vein), among the hepatic cords there are large diameter capillaries which termed hepatic sinusoids (figure 1). Normal kidney of rabbit was divided into cortex and medullary, the cortex was composed, renal corpuscles (glomeruli, Bowman's capsule) and renal

tubules which represented by proximal and distal convoluted tubules (figure 2). (These tubules were lined by simple cuboidal epithelium. The present work studied the effect of potassium dichromate on the liver and kidney cortex of rabbit at dose (50mg/kg.B.w.) for experiment period that extended into six weeks), the study revealed the effect of chromium on the liver lobules which appeared, slightly congestion of central vein, fatty degeneration in the hepatocytes, and the cytoplasm of some hepatocytes were appeared vacuolated (figure 3). Also histological observation on the kidney cortex, showed mild glomerulonephritis interstitial edema in the interstitial connective tissue and degeneration in some epithelial lining of proximal and distal convoluted tubules (figure 4). The previous studies were accordance with present work, they reported that administrated sodium dichromate in the drinking water to rats and mice led to focal ulceration, hyperplasia and metaplasia in the glandular tissue in the duodenum and stomach (17), also histological findings of the effect of chromium hexavalent on the male reproductive system appeared pronounced morphological changes with enlarged intracellular spaces and tissue damage (18). Our study findings in the third treated group which was administrated (60mg/kg B.w.) of potassium dichromate for experiment time were revealed slight enlargement of central vein in the rabbit liver lobules which surrounded by inflammatory cells (lymphocytes, neutrophils), clear vacuolization in cytoplasm of hepatocytes, and fatty degeneration and necrosis which occurs in some hepatocytes (figure 5), these observations were documented with current studies (19). Mentioned that potassium dichromate induced apoptosis and oxidative stress in the hepatocytes. Some workers explained the mechanism by which the chromium lead to apoptosis, and some of chromium damage present physical barrier to (DNA) replication, other (DNA) lesions are potentially pre-

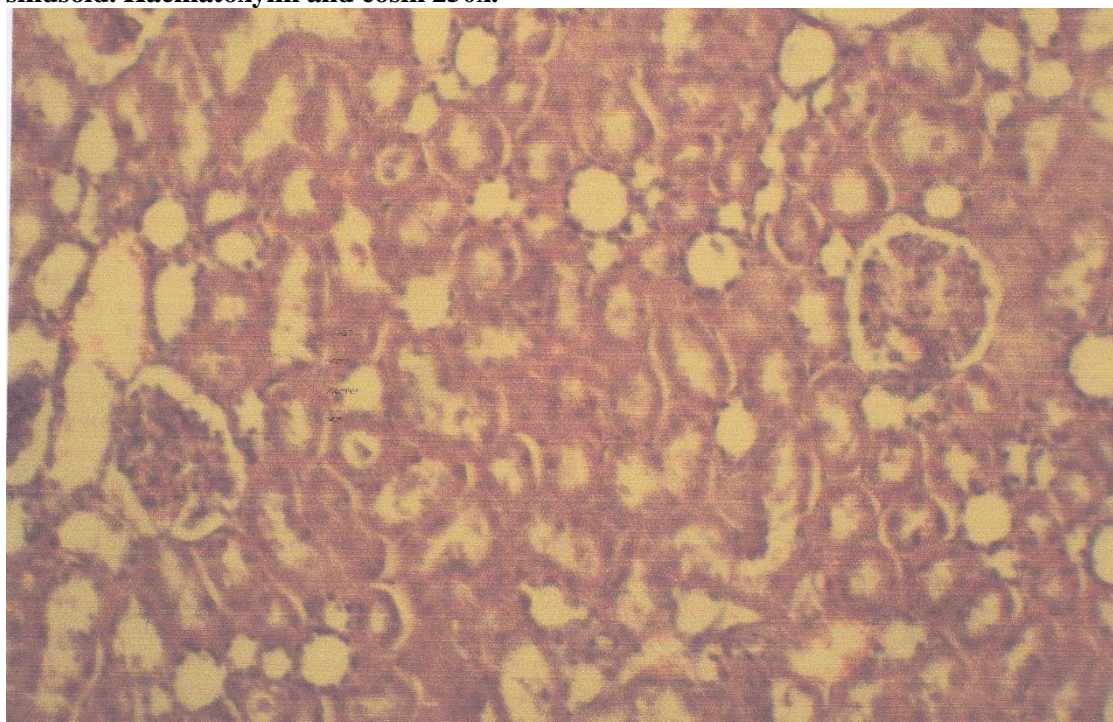
mutagenic and lead to (DNA) damage and cell cycle stop (20).

Figure (6) showed histological alteration in the rabbit kidney cortex that represented by moderate to severe glomerulonephritis, edema was distributed among the kidney tubules, from another hand congestion in the branches of renal vessels and necrosis and degeneration in the epithelial linings

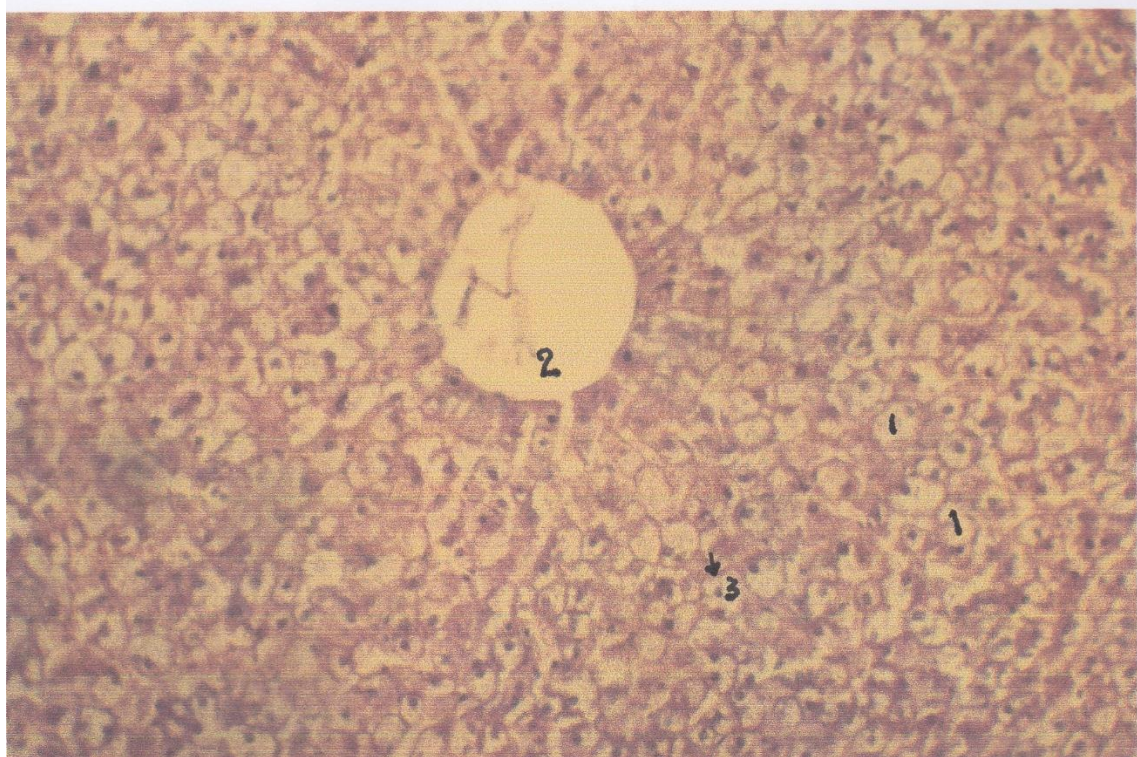of kidney tubules. Our observations was agreed with previous study (21). They reported sever renal impairment, renal failure and necrosis of renal tubules have been reported in cases of fatal and near fatal ingestion of hexavalent chromium and impaired renal function have been investigated in workers exposed to air borne chromium.



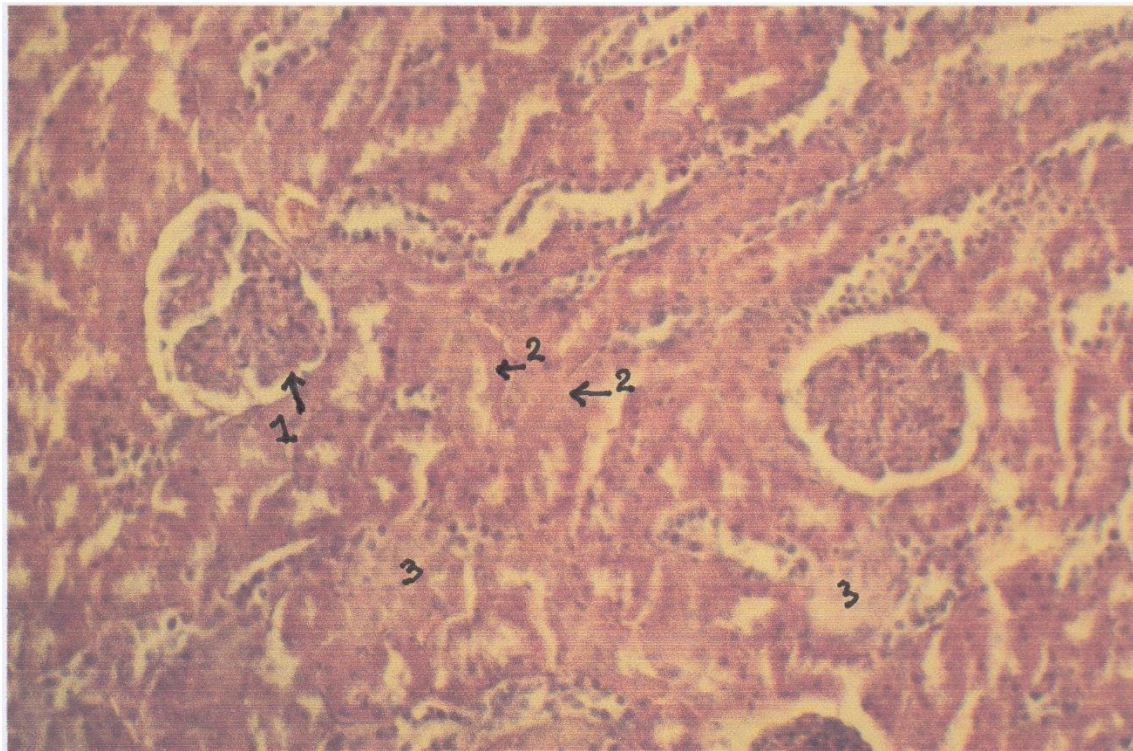
**Figure 1: showed normal liver lobules of rabbit, control group, it is consist of central vein, the hepatic cord composed from cuboidal epithelial cells, among the hepatic cords there are hepatic sinusoid. Haematoxylin and eosin 250x.**



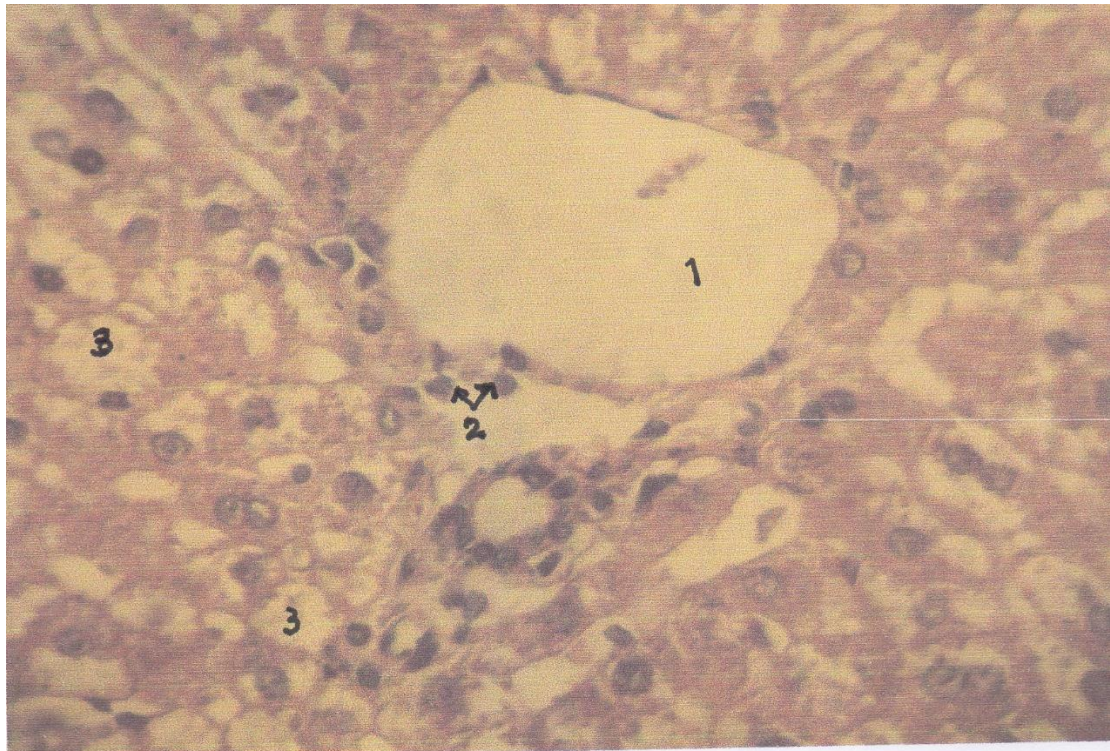
**Figure 2: Normal kidney cortex of rabbit, control group it is composed from glomeruli, it surrounded by Bowman's capsule, and proximal and distal convoluted tubules which lined by simple cuboidal epithelium. Haematoxylin and eosin 250x.**



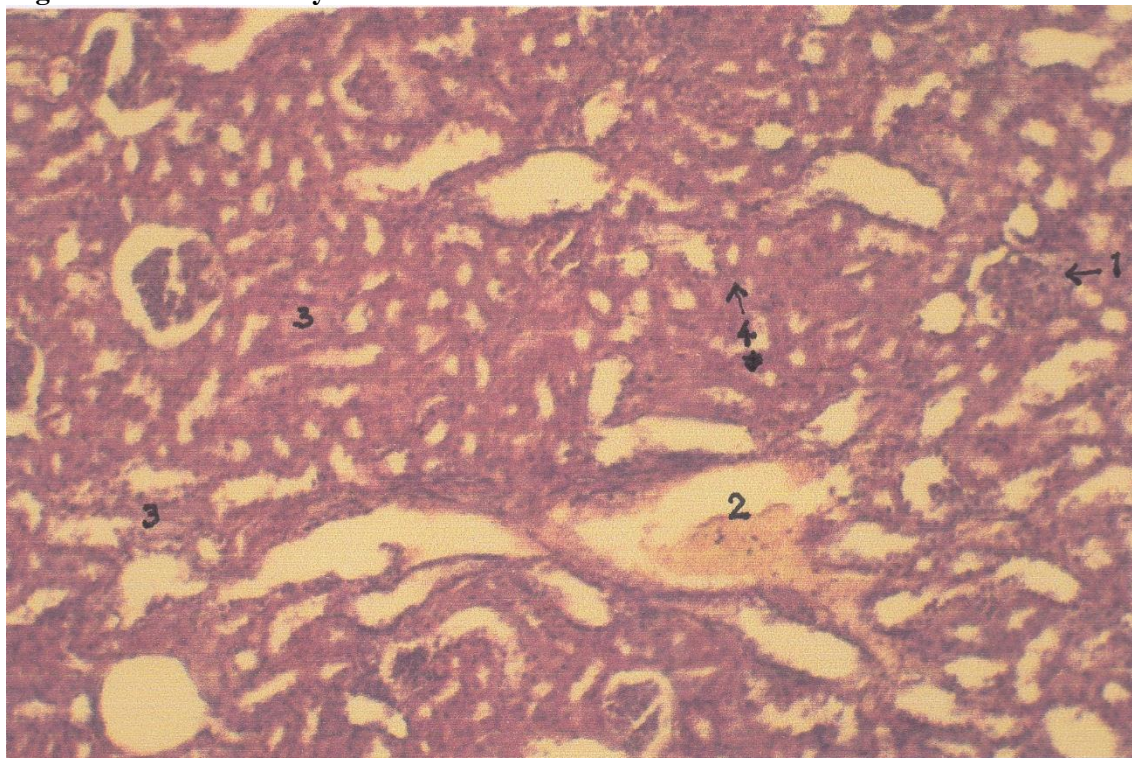
**Figure 3: Liver lobule of rabbit (first treated group) was administrated 50mg potassium dichromate /kg.B.w. For experiment period six week. Intracytoplasmic vacuoles in hepatic cells (1). Slightly congestion in central vein (2). Fatty degeneration in hepatocytes (3). Haematoxylin and eosin 250x.**



**Figure 4: Kidney cortex of rabbit belong to first treated group was administrated 50mg potassium dichromate/kg.B.w. For experiment period six week. Glomerulonephritis in some glomeruli (1). Degeneration in proximal and distal convoluted tubules (2). Interstitial connective tissue edema (3). Haematoxylin and eosin 250x.**



**Figure 5: Liver lobule of rabbit (second treated group) was administrated 60mg potassium dichromate/kg.B.w. For experiment period six weeks. Slightly enlargement of central vein (1). Nuclear poly morph infiltration (2). Vacuolization in the hepatocytes cytoplasm (3) due to fatty degeneration. Haematoxylin and eosin 450x.**



**Figure 6: Kidney cortex of rabbit, second treated group was administrated 60mg potassium dichromate/kg.B.w. For experiment period six weeks. Sever glomerulonephritis (1) in some glomeruli. Congestion in the branches of renal blood vessel (2). Necrosis and degeneration in the epithelial lining of kidney tubules (3). Interstitial edema (4). Haematoxylin and eosin 250x.**

**References:**

- 1-Gouille, J.; Sausseureau, E.; Grosjean, J.; Mahieu, L. Thouret, J. (2012). Accidental potassium dichromate poisoning. Toxicokinetics of chromium. Forensic Sci. Int.; 10:217.
- 2-Von Burg, R., Liv, D. (1993). Chromium and hexavalent chromium. J. Appl. Toxicol.; 13:225-230.
- 3-Cohen, M.; Kargacin, B.; Klein, C.; Costa, M. (1993). Mechanisms of chromium carcinogenicity and toxicity. Crit. Rev. toxicol.; 23:255-281.
- 4-Banu, S.; Stanley, J.; Lee, J.; Stephen, S.; Arosh, J. and Hoyer, P. (2011). Hexavalent chromium- induced apoptosis of granulosa cells involves selective sub-cellular translocation of Bcl-2 members, ERK ½ p53. Toxicol-Appl. Pharmacol.; 3:253-256.
- 5-Samuel, J.; Atanley, J. and Vengatesh, G. (2012). Ameliorative effect of vitamin (c) on hexavalent chromium- induced delay in sexual maturation and oxidative stress in developing Wister rat ovary and uterus. Toxicol. Ind. Health; 8:720-733.
- 6-Casta, M. (1997). Toxicity and carcinogenicity of Cr (VI) in animal model and human. Crit. Rev. In toxicol.; 27:432-442.
- 7-Langard, S. (1993). Role of chemical species and exposure characteristics in cancer among persons occupationally exposed to chromium compounds. Scand. J. work Environ. Health.; 19:81-89.
- 8-Alderson, M.; Rattan, N. and Bidstrud, L. (1981). Health of workmen in the chromate-planting industry in Britain. Br. J. Ind. Med.; 38:117-124.
- 9-Diaz-Mayans, J.; Laborda, R. and Nunez, A. (1986). Hexavalent chromium effect on motor activity and some metabolic aspects of wister albino rats. Comp. Biochem. Physiol.; 83:191-195.
- 10-Afonne, O.; Orisakwe, O.; Ekanem, I. and Akumka, D. (2000). Zinc protects chromium-induced testicular injury in mice. Indian. J. Pharm.; 34:26-31.
- 11-Snow, E. (1994). Effect of chromium on DNA replication in vitro Environ. Health precept; 3:41-44.
- 12-Katz, A. and Salem, H. (1993). The toxicology of chromium with respect to it is chemical speciation: a review. J. Appl. Toxicol.; 13:217-224.
- 13-Bancroft, J. and Stevens, A. (1982). Theory and practice of histological techniques. 2<sup>nd</sup> edition. Churchill, Livingstone, pp:647.
- 14-Antonini, J.; Lewis, A.; Roberts, J. and Whaley, D. (2003). Pulmonary effects of welding fumes: review of worker and experimental animal studies. AM. J. Ind. Med.; 43:350-360.
- 15-Stiff, A.; Friedl, J. and Laengle, F. (1988). Liver transplantation for potassium dichromate poisoning. N. Engl. J. Med., 338:766-767.
- 16-World Health Organization (WHO). (1988). Chromium Environmental Health Criteria, 61 Geneva. Switzerland. UNEP. Pp:1-16.
- 17-Bucher, J. (2007). Toxicity of sodium dichromate dehydrate administrated in drinking water to males and females rats and mice toxic Rep. Ser.; 27:1-4.
- 18-Rhouma, K.; Marouani, N. and Tebouri, O. (2012). Effect of hexavalent chromium on reproductive functions of male adult rats. Rep. Biol.; 12:119-133.
- 19-Wang, x.; Lou, x.; Shen, Y.; Xing, M. and Xu, L. (2010). Apoptosis-related protein changes induced hexavalent chromium in mice liver. Environ. Toxicol.; 25:77-82.
- 20-Patlolla, A.; Barnes, C.; Yedjou, C.; Velma, V. and Tchounwou, P. (2009). Oxidative stress, DNA damage, and antioxidant enzymes activity induced by hexavalent chromium in spargue-Dawley rats. Environ. Toxicol.; 24:66-73.
- 21-Agency for toxic substances and diseases registry (ATSDR) (1993). Toxicology profile for chromium USA. Department Health and Human Services. Public Health Service. Atlanta, GA. 80-92.