

Dermatitis associated with the *Ornithonyssus bacoti*

Sundus N. Al-Huchaimi

PhD), Dept. of Microbiology, College of Medicine, Kufa University, Iraq

sundus.alhuchaimi@uokufa.edu.iq

Received date: 15 Oct 2017

Accepted:(423) 4 Jan 2018

(21-25) Published: 31 Jun 2018

Abstract :

Cutaneous lesions caused by *Ornithonyssus bacoti* are misdiagnosed as other infection with bacteria or fungi or as allergies . Dermatitis in the persons working in animal house was infested with *O. bacoti* is reported in this study .A small number of studies confirmed that the *Ornithonyssus* species may cause dermatitis in human. The physical examination for patients showed separate papules scattered over their (arms, shoulder ,legs) , restlessness and urticaria -like dermatitis Microscopic examination was performed for 80 parasite from rat in animal house and 20 from clothing of researchers that worked in animal house and confirmed by PCR amplification. This study demonstrated the

Keywords: Dermatitis, *Ornithonyssus bacoti* , PCR

التهاب الجلد المرتبط ب *Ornithonyssus bacoti*

سندس نصيف الحجيبي

جامعة الكوفة/كلية الطب/فرع الاحياء المجهرية

الخلاصة :

الاصابات الجلدية المتسببة بواسطة ال *Ornithonyssus bacoti* تشخص بشكل خاطئ كأصابات اخرى تنتج عن البكتيريا او الفطريات او كحساسية .التهاب الجلد في الاشخاص العاملين في البيوت الحيوانية نتيجة الاصابة بهذا الطفيلي وصفت في هذه الدراسة .عدد قليل من الدراسات اكدت ان هذا الطفيلي قد يسبب التهاب الجلد في الانسان .الفحص الفيزيائي للمرضى اظهر بثرات منفصلة تنتشر فوق الساقين , الكتفين والذراعين مع الحكه وعدم الراحة .الفحص المجهرى انجز ل 80 طفيلي عزل من الجرذان الموجودة في البيت الحيواني و20 نموذج من ملابس الباحثين الذين يعملون في البيت الحيواني واكدت النتائج بواسطة تقنية ال Polymerase Chain Reaction هذه الدراسة اظهرت بوضوح امراضية هذه العوامل المسببة للانسان والحيوان

Introduction

Ornithonyssus bacoti is a [parasite](#) can infect laboratory rodent colonies and have wide host range . This parasite can irregularly infest humans when skin contact between them occur (Beck,2008).

Baumstark *et al.*,(2007) mentioned that the information is inadequately existing for distribution and occurrence of

Ornithonyssus bacoti on pet rodents in worldwide. The insufficiency of information, due in part to misdiagnosis makes the disease seem less universal than it is.

Jyoti *et al.*,(2016) explained that some morphologic characters such as hairiness, caudally pointed scutum , typical form of the anal plate with a cranial anus) allow for

differentiation of the *Ornithonyssus bacoti* from other species.

Sang *et al.*, (2013) said that the consulted physician consider cutaneous lesions due to other causes, reflection of a parasitic cause subsequent to finding parasites in the living or working place or when symptomatic therapies were failed. Once the parasite bites its host, nonspecific dermatitis occur due to an inflammatory reaction to its saliva. Secondary excoriations due to scratching are common.

Our objective was to afford a resource that will support in the plan and current evaluation of institutional occupational health and safety programs.

Materials and Methods

Study areas and specimens

The study was conducted on 100 specimens, 80 parasite from rat and 20 from clothing of researchers. Mites were collected from January 2016 to January 2017 in animal house of Kufa University in the province of Najaf AL Ashraf. The student was suffering from severe itching and papular urticaria and their general health

had constantly been good, with no history of systemic diseases or use of any drugs.

Mites Collection: Mites collection was occurred by 2 ways, the first by brushing the anesthetized rodent hairs (fed, red/brown in color and sluggishly motile). The second, the parasites were picked up from personnel clothing (unfed, white/grey in color and actively motile).

processing and storage of collected mites:

The specimens were cleaned in 20% KOH using warm bath water for 15 min, placed them in 5% acetic acid for 30 sec, then specimens were transmitted to 70% ethanol to preserve, prepared as microscopic and identified.

Morphological identification of mites: The prepared specimens were examined under a microscope in $10\times$, $40\times$ and $100\times$ based on morphological characteristics and according to different keys.

DNA extraction

DNA was extracted from mites by using Geneaid Genomic DNA extraction tissue kit and completed the steps based on company guidelines. Extracted DNA was kept in -20°C until PCR was performed

Polymerase Chain Reaction (PCR)

PCR technique was performed for detection of Internal transcribed spacer (ITS) gene in *Ornithonyssus bacoti*. ITS1 (18S and 5.8S) rRNA genes, while ITS2 is (5.8S and 28S) rRNA genes.

Primer	Sequence		Amplicon
<i>Orni-ITS1</i>	F	TCCATTCACTCACTCTTGGGC	501bp
<i>Orni-ITS2</i>	R	AATATGCTTAAATTCAGGGGGTCG	

The PCR master mix was prepared according to kit instructions as following table:

PCR master mix		volume
genomic DNA		5uL
primers	F	1µl of 10pmole
	R	1µl of 10pmole
PCR water		13µl
Total		20µl

These components were add to premix pellet in premix tube, then were mixed by vortex . The PCR thermocycler conditions were done in the following steps:

Step 1: 95 °C for 5 min

Step 2 : 95 °C for 1 min : 30 cycles

Step 3 : 60 °C for 1 min

Step 4 : 72 °C for 1 min

Step 5 : 72 °C for 5 min

The final PCR products were subjected to electrophoresis in a 1% agarose with ethidium bromide stain, and visualized under U.V transilluminator.

Results: The physical examination for patients showed separate papules scattered over their(arms, shoulder ,legs) , restlessness and urticaria -like dermatitis.

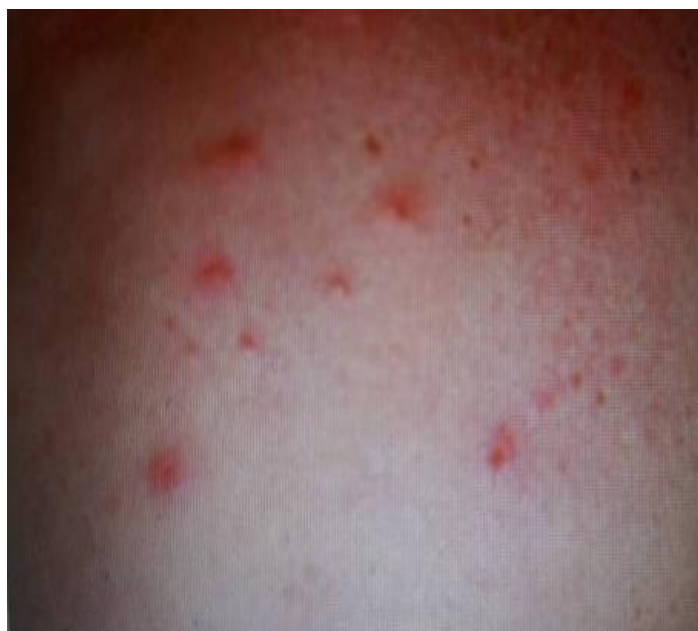

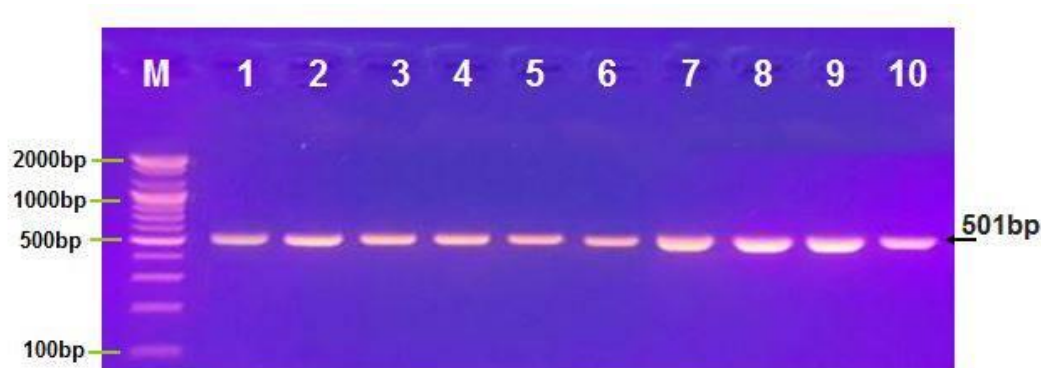
Fig.1: pruritic papules on the hand of patient with *O.bacotii*

Morphological identification of mites

All specimens were identified morphologically according to the keys of Jalil Abul-hab,(1978,1984) .

Mites DNA detection

The study revealed that 100 specimens (100%) get positive result for PCR ,while there were no specimens with negative results, were *Ornithonyssus bacoti* detected in all specimens .



Agarose gel electrophoresis of *Ornithonyssus bacoti* isolates in PCR. Lane M ,DNA size marker (2000-100bp), lane 1-10 (501bp) *Ornithonyssus bacoti* isolates.

Discussion

Several type of mites are associated with human dermatitis but the *O.bacoti* was the more common causative agent in this cases ,although none of these mites are truly parasitic on humans (Rahdar *et al.*;2015).

Watson,(2008) said that the laboratory rodents consider host to different mite species including *Ornithonyssus bacoti*

Beck and Pfister (2009)said that the *O. bacoti*, may infest human skin, causing symptoms also Beck, (2008) said that the mite induce non specific dermatitis by their saliva and part of mouth therefore The accurate diagnosis of dermatitis due to *O.bacoti* is difficult and requires finding of parasite in the environment of its host .For these reason the case report about this subject are rarely recorded in the human literature.

Watson,(2008) mention that *O.bacoti* were similar in morphology other species of mites such as *Dermanyssus gallinae* and *Ornithonyssus sylvarum* therefore the identification of this parasite requires special knowledge about the morphological characteristics of these parasites.

In Iraq, there is restricted data existing about the dermatitis that result from *O.*

bacoti ,t his may be due to misdiagnosis of this parasites and non-recording of such infestation.

Rahdar and Vazirianzadeh,(2009) mentioned that the diagnosis of mites is difficult because of the similarity among different species involved and the diagnosis based on light microscopy is not satisfactory and does not show detail morphology to categorize the mites into their taxonomic level for that reason the polymerase chain reaction was much more sensitive in identification and differentiation from other similar parasites and its treatment aspect in human infested with *O. bacoti* .

The finding in this study consistent with Cole *et al.*,(2005) and Baumstark *et al.*, (2007) whom indicated that there are association between infestation and job also Jyoti et al., (2016) mentioned that an outbreak of dermatitis occurred in researchers and the worker in animal houses.

Some studies such as Reeves *et al.*; (2007) showed that the *Bartonella* species, hantavirus ,*Coxiella burnetti*, and *Rickettsia* species isolated from *O. bacoti* therefore incidence of human dermatitis

has to be considered important and passable control measures to be necessary.

This study concluded that the *O. bacoti* was the causative agent of dermatitis in the researchers and worker in animal houses. PCR was reliable to confirm the microscopic examination that based on morphological characters.

References

1. Beck W. (2008). Occurrence of a house-infesting tropical rat mite (*Ornithonyssus bacoti*) on murides and human being. Travel Med Infect Dis. 6:245–249.
2. Baumstark, J.; Beck, W. and Hofmann, H. (2007) Outbreak of Tropical Rat Mite (*Ornithonyssus bacoti*) Dermatitis in a Home for Disabled Persons. Dermatology ;215:66–68.
3. Jyoti Nath, A.; Islam, S. and Sahu, S. (2016). Use of scanning electron microscopy to confirm the identity of tropical rat mite (*Ornithonyssus bacoti*): the cause of rat mite dermatitis. J Parasit Dis. 40(1): 161–165.
4. Sang Lip, C.; Hwang, S.; Kwon, B.; Kim, D.; Jun, D. and Kee Cho, B. (2013.) Outbreak of Rat Mite Dermatitis in Medical Students. International Journal of Dermatology. 37 (8): 591–598.
5. Abul Hab, j. (1978, 1984). Medical and Veterinary Entomology in Iraq. University of Baghdad Press, 451 pages.
6. Rahdar, M.; Vazirianzadeh, B.; Rointan, E. and Amraei, K. (2015). Identification of collected ectoparasites of rodents in the west of Khuzestan Province (Ahvaz and Hovizeh), southwest of Iran. Asian Pac J Trop Dis. 5(8): 627–631.
7. Watson J. (2008). New Building, old parasite: Mesostigmatid mites—an ever present threat to barrier rodent facilities. ILAR J. ;49(3):303–309.
8. Beck W, Fölster-Holst R. (2009). Tropical rat mite (*Ornithonyssus bacoti*)—serious ectoparasites. JDDG . 7(8):667–670.
9. Rahdar, M. and Vazirianzadeh, B. (2009) A case report of tropical rat mite infestation *Ornithonyssus bacoti* (Dermanyssidae: Acarina) in Ahvaz, SW Iran. JJM .2(2): 78–8078.
10. Cole, J. ; Sabol-Jones, M.; Karolewski .B., and Byford ,T. (2005) . *Ornithonyssus bacoti* infestation and elimination from a mouse colony. Contemp Top Lab Anim Sci. 44(5):27–30.
11. Reeves, W.; Loftis, A. and Szumlas, E. (2007). Rickettsial pathogens in the tropical rat mite *Ornithonyssus bacoti* (Acari: Macronyssidae) from Egyptian rats (*Rattus* spp) Exp Appl Acarol. 41:101–107.