

Effect of ferulic acid on Myocardial Ischemia/Reperfusion Injury In Male Mice.

Bassim I. Mohammad AL-Sheibani*

Najah Raiesh Hadi **

Najwan Abdulameer Atia **

Fadhil Ghaly. Yousif ***

* Department of Pharmacology and Therapeutics, College of pharmacy, Qadisiyah University, Iraq

** Department of Pharmacology and Therapeutics, College of Medicine, Kufa University, Iraq

*** Department of cardiovascular surgery, College of Medicine, Kufa University, Iraq

Abstract

Myocardial ischemia–reperfusion represents a clinically relevant problem associated with thrombolysis, angioplasty and coronary bypass surgery. Injury of myocardium due to ischemia–reperfusion includes cardiac contractile dysfunction, arrhythmias as well as irreversible myocytes damage.

A total of 24 Swiss albino adult male mice were randomized into 4 equal groups. Group (1) sham group; Group (2) control group; Group (3) control vehicle (DMSO) group; Group (4) Ferulic acid treated group.

Results of this study showed that levels of myocardial IL-6, were increased ($p < 0.001$) in the control group. Histologically, all mice in control group showed significant cardiac injury ($p < 0.001$). Ferulic acid significantly counteract the increase in myocardium level of IL-6 ($P < 0.001$). Histological analysis revealed that ferulic acid markedly reduced ($P < 0.001$) the severity of cardiac injury in the mice underwent LAD ligation procedure.

Keywords: Ischemia-reperfusion (I/R), systemic inflammatory response syndrome (SIRS), multiple organ dysfunction syndrome (MODS), Ferulic acid (FA), left anterior descending (LAD), Dimethylsulfoxide (DMSO).

تأثير حامض الفريولك على إنقاص الارواء الدموي وإعادته لعضلة القلب في ذكور الفئران

د. باسم ارحيم محمد الشيباني
د. نجاح رايش هادي ,
نجوان عبد الامير عطية الرماحي
د. فاضل غالي يوسف العمران

الخلاصة:

يمثل نقص الأرواء الدموي لعضلة القلب وإعادته مشكلة ذات صلة سريريّة مرتبطة بالاحتشاءات و القسطرة و جراحة تغيير الشرايين التاجية. تشمل إصابة عضلة القلب بسبب نقص التروية الدمويّة وإعادتها - ضعف مقلص القلب، عدم انتظام ضربات القلب وكذلك تلف الخلايا العضلية التي لا رجعة فيه. استخدم في هذه الدراسة أربع وعشرون ذكرا بالغاً من الفئران البيض السويسرية. وتم توزيعهم بشكل عشوائي إلى أربع مجاميع تشمل مجموعة النظار ومجموعة السيطرة (غير معالجه) ومجموعة المذيب و المجموعة المعالجة بحامض الفريولك.

وأظهرت النتائج ان المستوى إلى IL-6 قد ازدادت معنوياً ($p < 0.001$) في مجموعة السيطرة. أما النتائج النسيجية بعد عملية ربط الشريان التاجي الأمامي النازل الأيسر فقد أظهرت أن جميع قلوب الفئران قد تضررت معنوياً ($p < 0.001$). من خلال نتائج هذه الدراسة نجد بأن حامض الفريولك أظهر تأثيراً معنوياً ($p < 0.001$) على الالتهاب من خلال منع ارتفاع عامل الالتهاب IL-6 أما بالنسبة للنتائج النسيجية بينت ان حامض الفريولك أظهر انخفاضاً معنوياً ($p < 0.001$) بحدة الضرر الناتج بالفئران نتيجة عملية ربط الشريان التاجي الأمامي النازل الأيسر المسببة للإصابة بالنقص القلبي بالإرواء الدموي/ إعادة الأرواء.

Introduction:

Myocardial ischemia is a condition in which blood flow and oxygen to the cardiac muscle is decreased by partial or complete blockage of an artery carrying blood to the myocardium leading to death of an affected cardiac muscle, while the restorations of blood flow to an ischemic heart refer to myocardial reperfusion (1).

Reperfusion injury is the [tissue](#) damage caused when [blood](#) supply returns to the tissue after a period of [ischemia](#) or lack of [oxygen](#) (2). The absence of [oxygen](#) and [nutrients](#) from blood during the ischemic period creates a condition in which the restoration of [circulation](#) results in [inflammation](#) and [oxidative](#) damage through the induction of [oxidative stress](#) rather than restoration of normal function (3).

Ischemia and reperfusion injuries (I/R) are a primary cause of cardiac failure, morbidity, and mortality after cardiac operations (4) and heart infarctions (5).

I/R injury represents a fundamental common pathway of tissue damage in a wide variety of disease and surgical processes such as major trauma, acute mesenteric ischemia, septic and hypovolemic shock, abdominal aortic aneurysm surgery, and cardiopulmonary bypass (6).

Interruption of blood supply results in ischemic injury to all body systems and especially to high metabolically active tissues (7). Paradoxically, restoration of blood flow to the ischemic tissue augments cell injury by delivering toxic mediators induced in the ischemic tissue into the circulation thus affecting distant organs. This might lead to the development of systemic inflammatory response syndrome (SIRS), which can progress to multiple organ dysfunction syndrome (MODS) (6).

I/R injury promotes a release of oxygen free radicals, cytokines and other proinflammatory mediators that activate both the neutrophils and the coronary vascular endothelium. Activation of these cell types promotes the expression of adhesion molecules on both the neutrophils and endothelium, which recruits neutrophils to the surface of the endothelium and initiates a specific cascade of cell-cell interactions, leading first to adherence of neutrophils to the vascular endothelium, followed later by trans endothelial migration and direct interaction with myocytes (8).

I-R injury may occur in a variety of clinical settings, including reperfusion after thrombolytic therapy, coronary angioplasty, organ transplantation, aortic cross-clamping or cardiopulmonary bypass (9). Ferulic acid a 4-hydroxy-3-methoxycinnamic acid isolated from the root of *S.buergeriana*, is a kind of phenolic acid that is abundant in many of herbal medicines (10).

FA is a ubiquitous phenol in seeds and leaves of various plants and an antioxidant found in many staple foods, such as fruits, vegetables, cereals, coffee and in plant constituent exhibiting a wide range of therapeutic effects such as anticancer, antidiabetic, cardio protective and neuroprotective, anti-inflammatory activity (11).

Chen et al.(2009) found that salt of FA can inhibit myocardial cell death after anoxia/reoxygenation by reducing Ca^{2+} overload. However, the molecular target of FA in cell death signaling during I/R has not been fully identified (12).

Ferulic acid can resist platelet aggregation, inhibit platelet 5-hydroxytryptamine release, and inhibit platelet thromboxane A₂ (TXA₂) generation. It can reduce myocardial ischemia and oxygen consumption (13) and is used in clinical practice to treat coronary heart disease and angina pectoris mainly through inhibiting lipid oxidation, lowering cholesterol content in serum and antithrombotic effects. It can prevent atherosclerosis so as to treat coronary heart disease (14).

2-Materials and Methods

2.1. Animals

A twenty-four adult males Swiss Albino mice weighing 28-33 g were purchased from Animal Resource Center, the Institute of embryo research and treatment of infertility, Al-Nahrain University, Iraq. The animals were apparently healthy and they were housed in the animal house of College of Medicine/University of Kufa in a temperature-controlled ($25 \pm 2^{\circ}\text{C}$) room with alternating 12-h light/12-h dark cycles and were allowed free access to water and chow diet until the start of the experiments. The study was approved by the ethical commitments of institution.

2.2. In vivo myocardial I/R model

The *in vivo* myocardial I/R model was modified from a previous study (15). Briefly, mice were anesthetized with 100mg/kg ketamine and 10mg/kg xylazine (16). The mice were intubated and Mechanical ventilation is then achieved by connecting the endotracheal tube to scientific ventilator (Harvard Model) at a respiratory rate of 138 breath/minute with a tidal volume of 20 mL/kg body weight. A left thoracotomy was carried out to expose the heart. The LAD is then transiently ligated (or can be tied with a slipknot) using a 6-0 polypropylene suture for a 30-minute ischemic period (17). After a 30-min ischemia, by Microsurgical scissors are used to cut the knot in the ligature (or by releasing the slipknot) the heart was reperfused for 2 h. Immediately after finishing the reperfusion time the mouse was sacrificed ,starting by

injection of high dose from ketamine and xylazine, after giving good time for the animal to go into deep anesthesia, the mouse is positioned and the chest is opened in flap like manner revealing the heart then a needle of the syringe is introduced into right ventricle to aspirate around 2 ml of blood for later plasma analysis. After that hearts were rapidly removed for quantification of myocardial injury by biochemical studies.

2.3. Experimental groups and protocols

After the two week of acclimatization the mice were randomized into 4 groups, 6 mice in each group as follow:

1. **Sham group**: mice underwent the anaesthetic and surgical procedures but without left anterior descending (LAD) coronary artery occlusion.
2. **Control group**: (induced untreated group) mice underwent LAD coronary artery occlusion (for 30 min.), then reperfusion for 2 hours.
3. **Control vehicle (DMSO) treated group**: mice pretreated with Dimethylsulfoxide (DMSO) 1% v/v in normal saline i.p. at 1hr. before ischemia .
4. **Ferulic acid treated group (FA)**: mice pretreated with FA 50

mg/kg i.p. at 1 hr. before ischemia.

2.4. Tissue Preparation for measurement of (IL-6)

Cardiac tissues collected 120 minutes after reperfusion were homogenized in a solution containing 1:10(w/v) phosphate buffered saline that contain 1% triton X-100 and protease inhibitor cocktail (18). by using high intensity liquid processor. After homogenization, samples were centrifuged at 14,000 rpm for 20 min at 4°C (19) the supernatant was collected and used in IL-6 measurement using commercially available ELISA kits (Bioscience) according to the manufacturer's instructions.

2.5. Histopathological Analysis and Damage Scoring

Tissues were fixed in 4% paraformaldehyde and embedded in paraffin. Sections were stained with hematoxylin and eosin for histological evaluation of tissue damage. In order to have a quantitative estimation of cardiac damage, sections (n=6 for each animal) were scored by 2 independent observers blinded to the experimental protocol. The following morphological criteria were considered: score 0, no damage; score 1 (mild), interstitial edema and focal necrosis; score 2 (moderate), diffuse myocardial cell swelling and necrosis; score 3 (severe), necrosis with the presence of contraction bands and neutrophil

infiltrate; and score 4 (highly severe), widespread necrosis with the presence of contraction bands, neutrophil infiltrate, and hemorrhage.

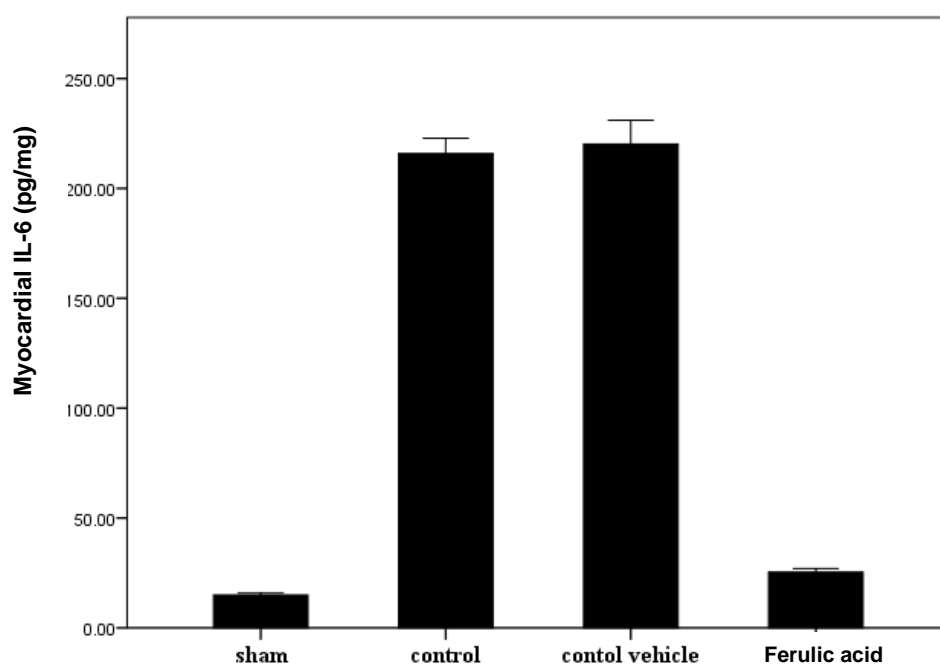
2.6. Statistical Analysis

Statistical analyses were performed using cytokines following MI/R were SPSS 20.0 for windows.Inc. Data were analyzed by ELISA. [Figure\(1\)](#) shows expressed as mean \pm SEM. Analysis of that MI/R injury increased significantly Variance (ANOVA) was used for the ($p < 0.001$) the levels of myocardium multiple comparisons among all groups IL-6 compared with the sham group followed by post-hoc tests using LSD ($P < 0.001$). In the ferulic acid method.

3. RESULTS

3.1. Ferulic acid reduced myocardial IL-6 following MI/R injury

Myocardium levels of inflammatory cytokines following MI/R were analyzed by ELISA. [Figure\(1\)](#) shows expressed as mean \pm SEM. Analysis of that MI/R injury increased significantly Variance (ANOVA) was used for the ($p < 0.001$) the levels of myocardium multiple comparisons among all groups IL-6 compared with the sham group followed by post-hoc tests using LSD ($P < 0.001$). In the ferulic acid treatment group, myocardium levels of IL-6, were reduced significantly compared with the control group ($P < 0.001$).



Figure(1): The mean of myocardial IL-6 level (pg/mg) in the four experimental groups at the end of the experiment

3.2. Histopathological findings

Treatment of mice with Ferulic acid improved cardiac injury significantly ($P < 0.001$) as compared with control vehicle group and the total severity scores mean of this group showed that 83.3% had mild cardiac injury and 16.7% had moderate cardiac injury. A cross section of sham mouse's heart showed a normal cardiac structure. All mice in this group showed normal hearts 100% as shown in table(1). There was statistically insignificant difference between control group and control vehicle group ($P > 0.001$) and the total severity scores of the control vehicle group showed 16.7% of the group had moderate, 66.7% had severe and 16.7% had highly severe cardiac injury.

Table (1): The differences in histopathological scoring of abnormal heart

	Sham group		Control group		Control Vehicle group		Ferulic acid treated group	
Normal	6	100%	0	0	0	0	0	0
Mild	0	0	0	0	0	0	5	83.3%
Moderate	0	0	0	0	1	16.7%	1	16.7%
Sever	0	0	4	66.7%	4	66.7%	0	0
Very Sever	0	0	2	33.3%	1	16.7%	0	0
Total cardiac injury	6	100%	6	100%	6	100%	6	100%

changes among the four experimental groups

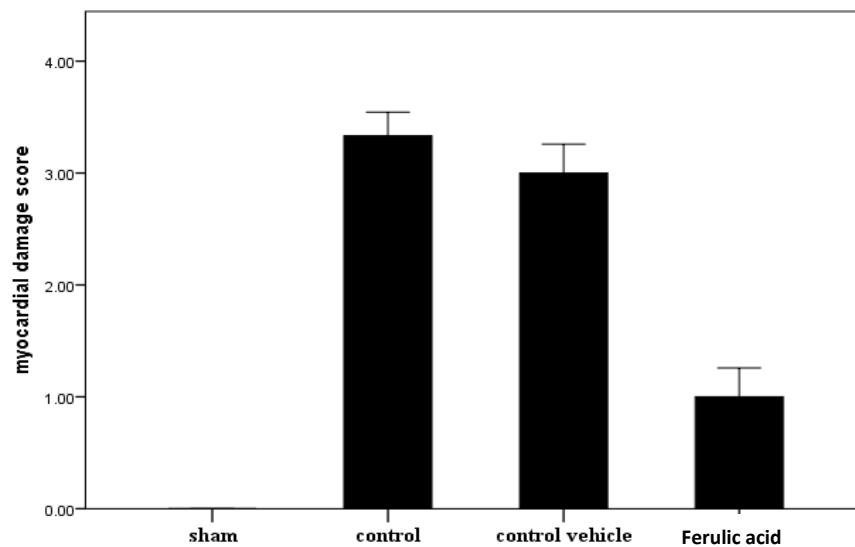


Figure (2): Error bar chart shows the difference in mean \pm SEM values of total severity scores in the four experimental groups.

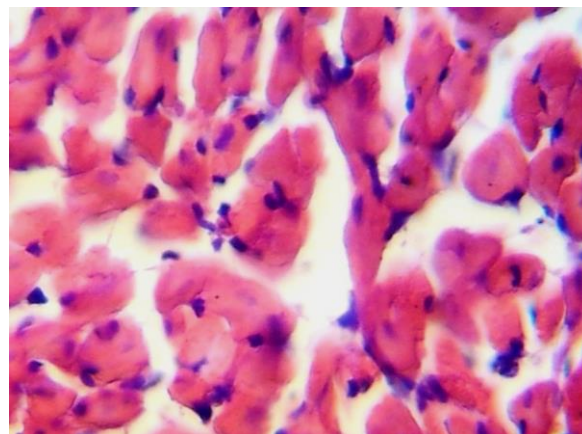


Figure (3): Photomicrograph of heart section of normal mice shows the normal architecture. The section stained with Haematoxylin and Eosin (X 10).

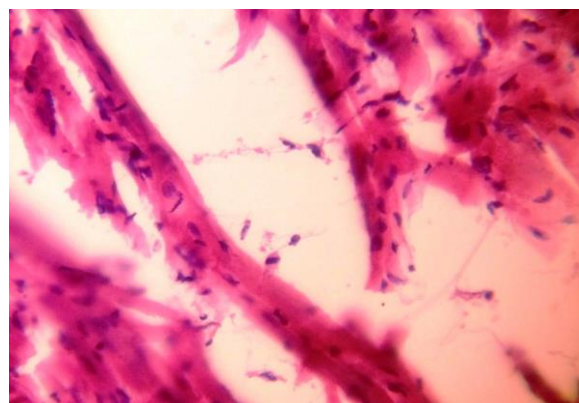


Figure (4): Photomicrograph of cardiac section for the control vehicle group showed interstitial edema, haemorrhage and PMN infiltration. The section stained with Haematoxylin and Eosin (X 40).

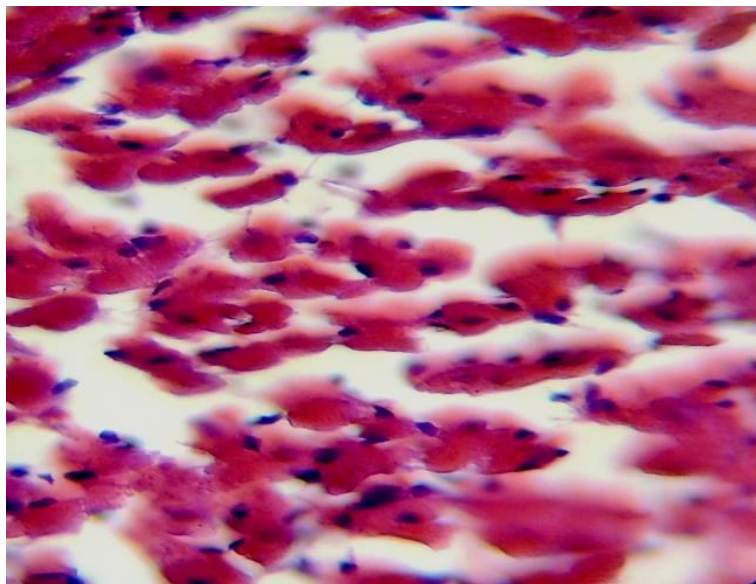


Figure (5): Photomicrograph of cardiac section in ferulic acid treated group. The section show almost normal cardiac tissue, the section stained with Haematoxylin and Eosin (X 40)

4- Discussion

The major findings of the present study are as follows. Firstly, that the inflammatory cytokine (IL-6) play important role in the pathology of myocardial I/R. Secondly, ferulic acid pretreatment played a protective role against myocardial I/R injury. The protective effects of ferulic acid during myocardial I/R injury were correlated with the attenuation of inflammation and Myocardial damage.

Cardiovascular disease(CVD) with all its appearances and complications is responsible for approximately 50% of all deaths in the world today (20). One

of the major contributing factors to CVD and heart failure is the loss of function or indeed death of cardiomyocytes due to coronary vessel occlusion (ischemia) followed by restricted blood flow (reperfusion) to the heart and a corresponding oxygen deprivation due to hypoxia (21). The early reperfusion phase is characterised by enhanced release of ROS from endothelial cells and cardiomyocytes, as well as enhanced expression of cytokines and adhesion molecules, The enhanced expression of chemokines during the first hours of reperfusion triggers further recruitment of neutrophils and monocytes into the

infracted myocardium which lead to increase the cardiac damage by further releasing ROS, inflammatory mediators and proteases (22).

Kim and Lee(2012) indicated that ferulic acid attenuates ischemia/reperfusion-induced hepatocyte apoptosis via inhibition the increases in the serum tumor necrosis factor- α levels and TNF receptor type-1-associated DEATH domain protein and TNF receptor-associated factor-2 protein expressions(23).

Obayashi *et al.*(2005), Kosmadaki *et al.*(2003) observed that IL-6 and TNF- α are secreted by epidermic keratinocytes and play an important role in UV-mediated photobiology. IL-6 could cause fever and promote the synthesis of C- reactive protein (CRP). There have been reports indicate that immediate adding TNF- α antibody after UV irradiation reduced cell debris formation and apoptosis remarkably(24,25).

Lin *et al.*(2010) confirmed that the levels of IL-6 and TNF- α increased after 30~90 mJ/cm² of UVB irradiation, which further implied the significance of cytokines in UV-induced skin injury. After Ferulic acid treatment, IL-6 and TNF- α secretion was apparently reduced (P< 0.001)(26).

5-Referances

- 1- Ansorge S, Reinhold D, Lendeckel U. (2003):Propolis and some of its constituents down-regulate DNA synthesis and inflammatory cytokine production but induce TGF- β 1 production of human immune cells. *Z Naturforsch.* 58c: 580- 89.
- 2- Grace P. (2005). Ischemia reperfusion injury. *British Journal of Surger.* 81: 637-47.
- 3- Manipuri P, Indala R, Jagaralmudi A, Ramesh Kumar K. (2013). Hepatoprotective Effect of Inularacemosa on Hepatic Ischemia/reperfusion Induced Injury in Rats. *J Bioanal Biomed* 5: 022-027.
- 4- Basgut B, Kayki G, Bartosova L, Ozakca I, Seymen A, Kandilci H, *et al.*(2010). Cardioprotective effects of 44Bu, a newly synthesized compound, in rat heart subjected to ischemia/reperfusion injury. *Eur J Pharmacol* 640:117–123.
- 5- Heusch G, Musiolik J, Gedik N, Skyschally A. (2011) .Mitochondrial STAT3 activation and cardioprotection by ischemic postconditioning in pigs with regional myocardial ischemia/reperfusion. *Circ Res* 109:1302–8.
- 6-Leng Y, Zhang Y, Zhang Y, Xue X, Wang T, Kang Y. (2011). Ischemic post-conditioning attenuates the intestinal injury induced by limb ischemia/reperfusion in rats. *Braz J Med Biol Res*, 44(5):411-17.
- 7- Mallick I, Yang W, Winslet M, Seifalian A. (2004). Ischemia-reperfusion injury of the intestine and protective strategies against injury. *Dig Dis ci* , 49(9):1359-77.
- 8-Jordan J, Zhao Z, Vinten-Johansen J. (1999). The role of neutrophils in

myocardial ischemia-reperfusion injury. Cardiovasc Res. Sep;43(4):860-78.

9-Eltzschig HK, Collard CD .Vascular ischaemia and reperfusion injury. Br Med Bull. 2004 Oct 19;70:71-86.

10- [Graf E.](#) (1992). Antioxidant potential of ferulic acid. [Free Radic Biol Med.](#) Oct;13(4):435-48.

11- Gohil K, Kshirsagar S and Sahane R. (2012). Ferulic Acid – A Comprehensive Pharmacology Of An Important Bioflavonoidvol. 3(1): 700 - 10.

12- Chen H, Liao Z, Huang Q, He M. (2009). Sodium ferulate attenuates anoxia/reoxygenation-induced calcium overload in neonatal rat cardiomyocytes by NO/cGMP/PKG pathway. Eur. J. Pharmacol. 603:86–92.

13- Zhang M, Shen Y. (1994). Anti-hypoxia effect of caffeic acid and ferulic acid. Northwest PharmaceuticalJournal;9:118.

14- Wang H, Shi E. (2007). The advance in the research on phamacology action of ferulic and its derivatives. Acta Academiae Medicinae Neimongol;29:601-3.

15- Kolk M, Meyberg D, Deuse T, Tang-Quan K, Robbins R, Reichenspurner H, *et al.*(2009). LAD-ligation: a murine model of myocardial infarction. [J Vis Exp.](#) Oct 14;(32). pii: 1438.

16- Feitoza C, Goncalves G, Semedo P, Cenedeze M, Pinheiro H, Beraldo F, *et al.*(2008). Inhibition of COX 1 and 2 prior to renal ischemia/reperfusion injury decreases the development of fibrosis. Mol Med 14(11-12): 724-30.

17- Maekawa N, Wada H, Kanda T, Niwa T, Yamada Y, Saito K, *et al.*(2002). Improved myocardial ischemia/reperfusion injury in mice lacking tumor necrosis factor-alpha. J Am Coll Cardiol. Apr 3;39(7):1229-35.

18-Zhang M, Xu YJ, Saini HK, Turan B, Liu PP, Dhalla NS.Pentoxifylline attenuates cardiac dysfunction and reduces TNF-alpha level in ischemic-reperfused heart.Am J Physiol Heart Circ Physiol.(2005 b)Aug;289(2):H832-9. Epub 2005 Apr 15.

19-Granado M, Fernández N, Monge L, Figueras JC, Carreño-Tarragona G, Amor S, García-Villalón AL. Effects of coronary ischemia-reperfusion in a rat model of early overnutrition. Role of angiotensin receptors. PLoS One. 2013;8(2):e54984. doi: 10.1371/journal.pone.0054984. Epub 2013 Feb 1.

20-Allender S, Scarborough P, Peto V. (2008). European cardiovascular disease statistics. 2008 edition.

21- Barry S, Townsend P, Latchman D, Stephanou A. (2007). Role of the JAK-STAT pathway in myocardial injury. Trends Mol Med; 13(2):82-89.

22-Steffens S, Montecucco F, Mach F .The inflammatory response as a target to reduce myocardial ischaemia and

reperfusion injury. Thromb Haemost. 2009 Aug;102(2):240-7.

23-Kim H, Lee S. (2012). Ferulic acid attenuates ischemia/reperfusion-induced hepatocyte apoptosis via inhibition of JNK activation. Eur J Pharm Sci. Apr 11;45(5):708-15.

24- Obayashi K, Kurihara K, Okano Y, Masaki H, Yarosh D. (2005):L-Ergothioneine scavenges superoxide and singlet oxygen and suppresses TNF-alpha and MMP-1 expression in UV-irradiated human dermal

fibroblasts. J Cosmet. Sci. 56(1): 17-27.

25- Kosmadaki MG, Yaar M, Arble BL, Gilchrest BA. (2003): UV induces VEGF through a TNF-alpha independent pathway.FASEB J. 17(3): 446-8.

26- Lin XF , Min W and Luo D. (2010): Anticarcinogenic effect of ferulic acid on ultraviolet-Birradiated human keratinocyte HaCaT cells. Journal of Medicinal Plants Research. 18 August Vol. 4(16): pp. 1686-1694, ISSN 1996-0875.