

Parasitological and pathological study for Parasitic cysts in animals and Human of Iraq

Khairy A. Dawood Ruaa A. Talib

College of Al-Mustaqbl University /Babylon / Iraq

Abstract

There are some parasitic cysts occur in animals and human , one of the most important is the hydatid cysts . More than thirty years hydatidosis was followed in Mosul , Baghdad , Al- Qa-disyia , Babylon and Najaf . Hydatid Cysts were collected from animals of slaughter houses of these provinces , while Human cases were followed in surgical rooms of main hospitals . Sheep hydatidosis was the highest percent (45%)more than other animals , while the lowest was in buffalo 5% .

Fertile hydatid cysts and sterile cysts were identified by eosin stain , so the highest percent of fertile cysts were in sheep 74% while the lowest was in cattle 22% , while sterile cysts were highest in cattle .Viability of the protoscolices were examined by eosin stain .

Beside hydatid cysts two other cysts were recorded depend on morphologic and pathologic Characterizations , therefore hydatid cyst of *Echinococcusgranulosus* was the highest percent , but there are other cysts were diagnosed as *Cysticercustenuicollis*(Larval stage of *Taeniahydatigena*) . *Coenuruscerebralis*(Larval stage of *Multicepsmulticeps*).

دراسة طفيلية مرضية للأكياس الطفيلية في الحيوان والإنسان في العراق

خيرى عبدالله داود روى على طالب
كلية المستقبل الجامعة / بابل / العراق

الخلاصة:

أن أمراض الأكياس الطفيلية في الحيوان والإنسان عديدة ومتنوعة ولكن الأكياس العدرية (المائية) أكثرها شيوعاً وهو من الأمراض المستوطنة في العراق . أن الأكياس العدرية هي الدور اليرقي لطفيلي المشوكة الحبيبية *Echinococcusgranulosus* تمت متابعة هذا الطفيلي في عدة محافظات وجمعت الأكياس من الحيوانات المذبوحة في المجازر الخاصة بهذه المحافظات بينما حالات الإنسان تمت متابعتها في الصالات الجراحية للمستشفيات الرئيسية . الأكياس العدرية في الأغنام كانت أعلى نسبة من كل الحيوانات 45% بينما أقل نسبة سجلت في الجاموس 5% . الأكياس العدرية صنفت الى نوعين مخصبة وعقيمة حسب وجود الرويسات في الأكياس ، أعلى نسبة للأكياس المخصبة سجلت في الأغنام 74% وأقل نسبة في الأبقار 22% .

أن حيوية الرويسات تم فحصها باستخدام صبغة الأيوسين إذ أن بعض الرويسات حية والبعض الآخر ميتة

كما تم تشخيص نوعين آخرين من الأكياس الطفيلية اعتماداً على المواصفات الطفيلية والمرضية ، هذين الكيسين هما *Cysticercustenuicollis* والذي هو الدور اليرقي لطفيلي *Taeniahydatigena* والكيس الآخر هو *Coenuruscerebralis* وهو الدور اليرقي لطفيلي *Multicepsmulticeps*

Introduction :

Echinococcusgranulosus :

Hydatid cysts are the larval stage of *Echinococcusgranulosus* which is an adult worm lives in small intestine of dogs and other canine . Fertile hydatid cysts have protoscoleces which are produced from the germinal layer , but there are some of these cysts are sterile (non fertile) (Almaili , H . M.1997) .

Other researchers worked on epidemiology of hydatidosis in Iraq , Molan (1993) published data on epidemiology of hydatidosis and echinococcosis in Thegar province , southern Iraq , while Dawood , *et al* (1995) worked on incidence of hydatidosis in human and animals of Diwania/ Iraq .

If the dogs ingest fertile cysts (from infected organs of herbivorous) So the protoscoleces will evaginated its head and grow to adult worm in small intestine of dog . Adult worms produced eggs which passed with feces . When eggs are eaten by herbivorous or humans , the eggs hatch releasing first larval stage Oncosphere which is penetrate the wall of small intestine and migrate with blood circulation and where it is settled (in which organ) hydatid cysts will developed .

Thompson and lumbery(1995) considered the strains of *E.granulosus* are genetically differ and classified just one species which is infect man and animals .

Eckert , *et al* (1989 , 1993) worked many research on hydatid cysts and proved that *Echinococcusgranulosus* strain of

infection of dog is a (final host) , while pig and camels are the intermediate hosts .

Another research was published by Zhang *et al* (1998) about classification of echinococcosis species depend on DNA by using PCR (polymerase chain reaction) , and nine strains were recorded with different DNA genotypes . This information was insured by Eckert , *et al* (2001) .

Eckert , *et al* (2001) . Published a manual of echinococcosis in human and animals by the world health organization as a wide *range problem* .

Ould Ahmed Salem *et al* (2011) published a study on epidemiology on echinococcosis and characterizations of human and livestock hydatid cysts infection in Muritania .

Al- Mialy , H. M. (1997) found highest percent of fertile cysts present in sheep while the lowest percent was in cattle infection , while Enrico , *et al* (2010) Published a data on treatments for alveolar cysts in human .

Taeniahydatigena :

Definitive hosts : dogs , foxes , wolves , localized in small intestine.

Intermediate hosts : sheep , cattle , deer , horses , pig .

Larval stage (*Cysticercustenuicollis*) localized in liver and abdominal cavity (Taylor , M.A. *et al* 2007) .

Reza Salavatiet *al* (2013) worked on molecular and morphological characterizations of *Taeniahydatigena* isolated from sheep infection in Iran , Several variations were found

among rRNA sequence of this parasite .

Coenurus cerebralis ;

Achenef M. *et al* (1999) recorded 210 heads infected with coenurus cysts during one year in Ethiopia . These cases were diagnosed clinically and post mortem inspection .

Ozmen , O . *et al* (2005) observed twelve sheep from seven different flocks in Turkey (total number 1400 heads) suffered coenurosis caused by larval stage of *Taenia multiceps*.

Synonym of *Coenurus cerebralis* is *Multiceps multiceps* which live in small intestine of Dogs , Jackles , Foxes , and Wolves (Final hosts) while sheep goat , cattle , deer , pig , horses and man (Intermediate hosts) . This parasite localized in brain and spinal cord of intermediate hosts (Taylor , M. A. *et al* 2007).

Materials and Methods :

Regular visiting (weekly) to the slaughter houses in Mosul , Diwanyia , Najaf , Hila , at different interval (one year for each) . Total of number of examined animals (sheep , cattle , goats , camel and buffalo) were 68435 while infected cases were 6551 (1953 in Mosul , 1841 in Diwanyia , 1290 in Najaf , 1467 in Hila) .

Human cases recorded in Diwanyia only main Hospital , So the number of infected cases was 42 during one year only .

Internal organs of animals were inspected grossly, and infected organs were taken to the laboratory . Most cysts were collected from Liver , Lung , Spleen and very limited number in kidneys . These cysts were classified parasitological , size was measured , color , locations . Fertility of these cysts was studied directly by microscopic examination

for protoscolices While viability was estimated by eosin stain 1% .

Results :

Hydatid cysts (larval stage of *Echinococcus granulosus*) were the highest percent among all types of cysts (total number of inspected animals 68425 infected with cysts 6551 so the percent 9.57%) while hydatid cysts were 5371 , 82% from infected cases)

Cysticercus tenuicollis (larval stage of *Taenia hydatidigena*) was 851 in number 13% while *Coenurus cerebralis* (larval stage of *Multiceps multiceps*) was 329 in number 5% .

Hydatid cysts :

Grossly , size of hydatid cysts 1- 15 cm (Fig . 1) , color were milky , some of these cysts half embedding in parenchyma of organs and others complete embedding , cyst filled with hydatid fluid .

Metacestodes (hydatid cysts) are the larval forms of *Echinococcus granulosus* and *Echinococcus multilocularis*, therefore two types of hydatid cysts cystic (Unilocular) which is caused *E. granulosus* while multilocular cysts caused by *E. multilocularis* . Percents of unilocular cysts were 70% and multilocular cysts 30% .

Fertility of hydatid cysts was studied , samples of cysts were opened carefully and evacuated the hydatid fluid in beaker , then examined under microscope , so the presence of protoscolices (Fig. 2) means this cysts is fertile while cysts without protoscolices means sterile cysts . Sheep were high percent in fertility 75% , , goat 63% cattle 35% , buffalo 32% , camel 72% . Human was the highest 84% . Very rarely daughter cysts noticed in animals hydatid cysts but in human daughter cysts were present .

There are 40 cases human cases of hydatid cysts , most of these cysts were in liver but other cysts recorded as cases in different organs such as lung , spleen thyroid , salivary gland , and bones . Only two cases of *Coenuruscerebralis* were present in cranial cavity .

Viability of the protoscolices was tested by Eosin stain , so red protoscolices , it means living protoscolices while green means dead , proportion of live to dead protoscolices depend on the size and age of the cysts , small size (young cysts) have low ,number of dead protoscolices and vice versa .



Fig (1) : Largest Hydatid Cyst found in liver of Cow (Fifteen Cm.)

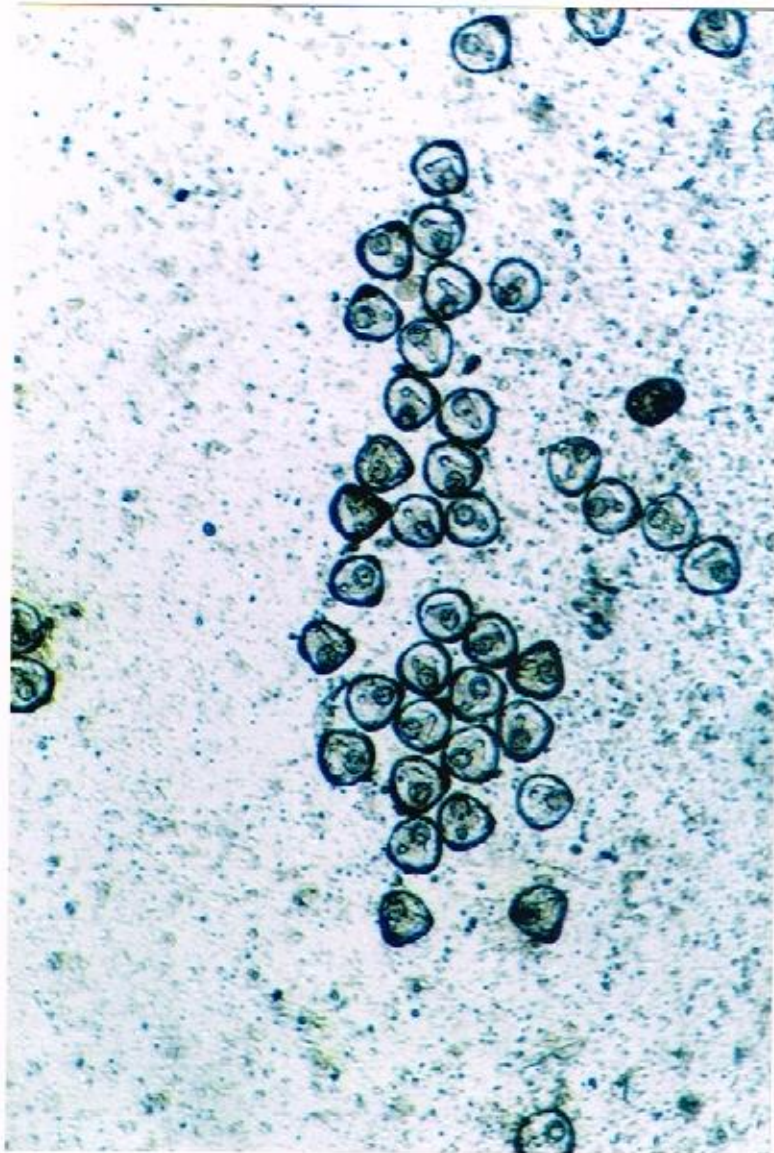


Fig (2) : Protoscolices evacuated from fertile cyst .

Cysticercustenuicollis :

Larval stage of *T. hydatigena* was recorded in liver infection of sheep and goat only ,it was superficial over the surfaces of liver not embedded in parenchyma of the liver as in hydatid cysts and these cysts were translucent , delicate cysts (Fig. 3) .

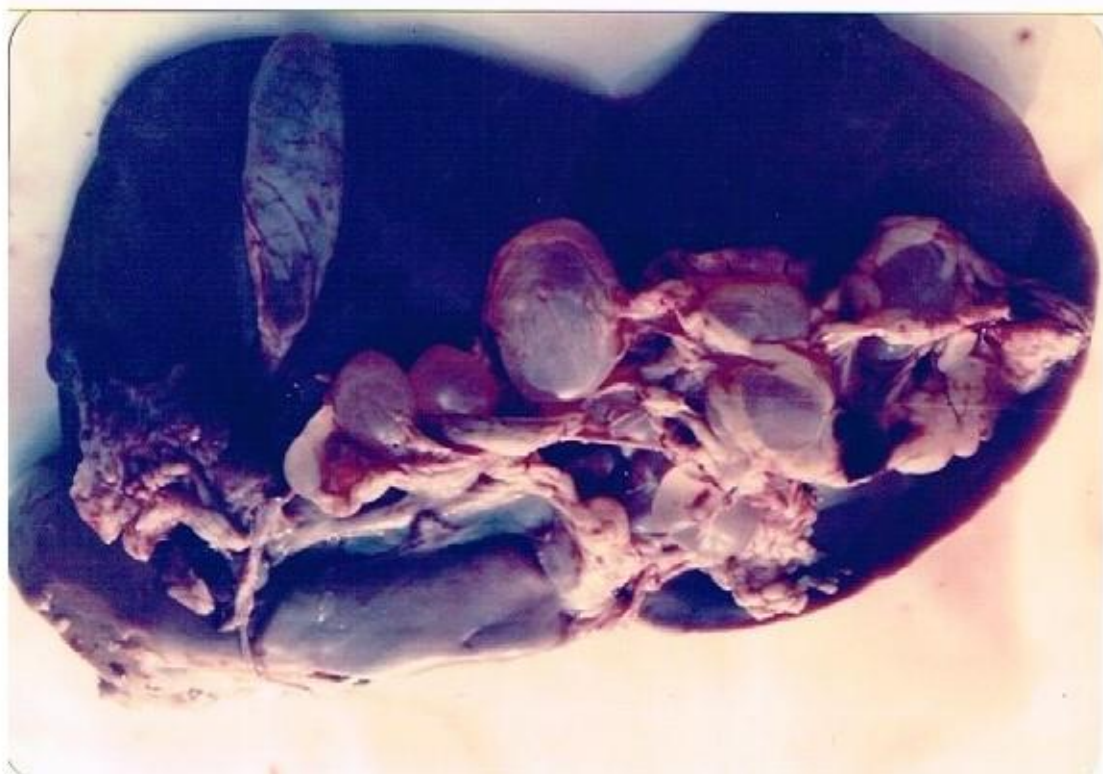


Fig (3) : Cysticercustenuicollis (larval stage) of *T. hydatidigena* , attached superficially in liver of goat .

Coenurus Cysts :

All cases of Coenurus cysts were recorded in this research in subcutaneous tissues and intramuscular locations . These cases were in cattle and goat . , size of the cysts were noticed grossly ranged from 5 – 10 cm , round in shape (Fig. 4) , External wall was semi-translucent so the scolices can be seen from outside .

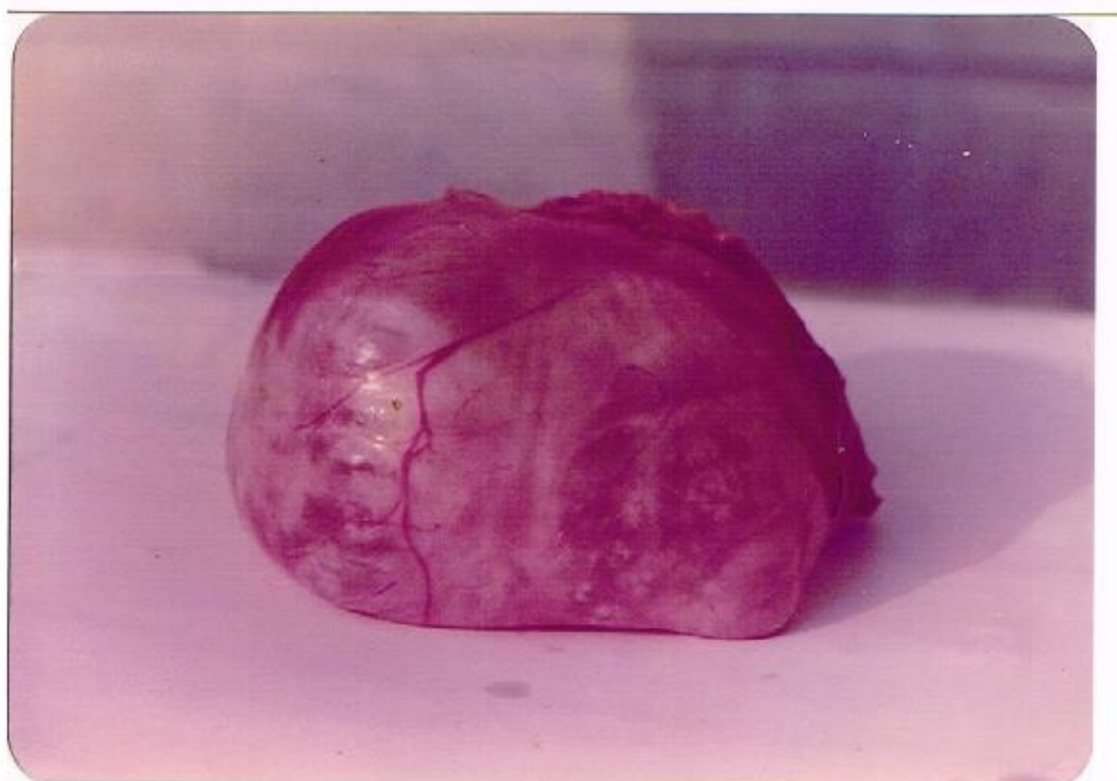

Fig (4) : Coenurus Cyst isolated from muscles of thigh of Ox .

Discussion :

It is preferable to say Echinococcosis for dogs (Final host) infection with *Echinococcusgranulosus*, adult worm , and hydatidosis for hydatid cysts , larval stage ,in animals , intermediate host (sheep , cattle , goat , buffalo , camels) and human .

No human infection with cysts of *T. hydatigena* only in animals (sheep and goat) and no localization in other organs only liver but did not noticed *Cysticercustenuicollis* attached to peritoneum or in abdominal cavity as Taylor *et al* (2007) mention that .

High percent of hydatidosis was recorded in camel of Morocco 80% , Algeria 56.5% and Sudan 45.4% (Ibrahim , M . and Craug , P. 1988) , while Dawood *et al* (1995) found 7% of camel hydatidosis , Sheep

was the highest 10.3 % in Iraq (these percent from the total number of inspected animals) .

In our present work highest percent of fertility of protoscoleces was in human 84% , sheep 75% and in camel 72% , the lowest were buffalo and cattle (32% , 35%) respectively , So this variations between fertility of parasite in different animals depend (host parasite relationship) , it means age of this relation , while variations between several countries depend several factors , geographic , strain of parasite , types of animals . There is no seasonal variation .

Coenurus cysts developed in subcutaneous and intramuscular sites , this agree with Taylor M. *et al* (2007) about what mention on coenurus cysts but did not noticed in cranial cavity or in spinal cord ,

only in human two cases were recorded and removed from cranial cavity by successful surgical operations

References

- 1 - Achenef , M. Markos , T. Feseha , G. Hibret , A. Temblely , S. (1999) .Coenuruscerebralis infection in Ethiopia Highland sheep : Incidence and observations on Pathogenesis and clinical Signs . Trop. Anim. Health. Prod. (1) : 15- 24 .
- 2 - Al- Maily , H. M. (1997) . Study of distribution of Hydatidosis in Diwania Province . MSc. Thesis , Al-Qadisyia Uni.
- 3 - Dawood , K. A. Abd , A. H. and Taher , F. H. (1995) . Incidence Of Human and Animal Hydatidosis in Diwania Area , The Vetrenarian /Vol. (4 , 5) .
- 4 - Eckert , J. Thompson , R. Michael , S. Kumaratilake , L. and Al-Saeah , H. (1989) . *Echinococcusgranulosus*of Camel origin : development in dogs and parasite Morphology Parasitol . Res. 75 : 536 – 544 .
- 5 - Eckert , J. Thompson , R. Lumbery , A. , Pawlowski , Z. Gottstein , B. and Morgan , U . (1993) . Further evidence for the Occurrence of a district strain of *Echinococcusgranulosus* In European pigs Parasitol. Res. 79 : 42- 48 .
- 6 - Enrico , B. Peter, K. and Dominique , A. V. (2010) . Expert Consensus for treatment of Cystic and Alveolar Echinococcosis in humans . ActaTropica, vol. 114 , p. 1-16 .
- 7 - Molan , A. L. (1993) . Epidemiology ofhydatidosis an Echino - CoccosisIn Theqar Province , Southern Iraq , Japanese , J.ofMedical Science and Biology ., 46 : 29 – 35 .
- 8 - Ould Ahmed Salem , Shneegans , F. Chollet , J.Y. and Jemli , M.H. (2011) . Epidemiological Studies on Echino -coccosis and Characterization of human and Livestock Hydatid Cysts in Mauritania . Iranian J. Of Parasitology , 6(1) , 49- 57 .
- 9 - Ozmen , O. Sahinduran, S. Haliqur , M. Sezer , K. (2005) . Clinico pathologic Observations on Coenuruscerebralis in naturally infected sheep . Schweiz Arch. Tierheilkd , 147 (3) : 129 – 134 .
- 10 - Reza , S . Zahra , B. Mitra , S . Mohammad , R. B.(2013) . Molecular and morphological Characterizations of Tape worm *TaeniaHydatidgen*(Pallas 1766) in sheep From Iran . J. Of Helminthology , 89 (02) : 1- 8 .
- 11 - Taylor, M.A. , Coop, R.L. and Wall, R.L. (2007) .Veterinary Parasitology , Text book , 3rd Edition , Blackwell Publishing .
- 12 - Thompson , R. and Lumbery A. (1995) . Echinococcosis and Hydatid Disease , 1st ed. Wallingford , CAB International
- 13- Zhang , L.H. Eslami , A. Hosseini , S.H. and Memanus , D.P. (1998) .Mitochondrial DNA markers compared for Human and Animals isolates indicate the presence of Two district Strains of*Echinococcusgranulosus*in Iran . World organization for animal health 12 , rue de Prony , Paris , France 1 – 16 .