

Histopathological changes of trachea in three genetic lines of broilers vaccinated with avian infectious bronchitis virus

Latif I. kadhim* Muayad A. Hussein** Mohammed S. Abdul-Aziz

*Department of Pathology and poultry diseases, Faculty of Veterinary Medicine, University of Kerbala

**Department of Pathology and poultry diseases, Faculty of Veterinary Medicine, University of Kerbala

Abstract

The histopathology of trachea was studied in three genetic lines of broilers which vaccinated with avian infectious bronchitis virus (IBV) vaccines. Differences in genetic immune response and susceptibility are known for many of the major viral pathogens of poultry. Consequently, the study was done. A total of 150 one-day-old consist of three chicken strains of broilers (Cobb 500, Ross 308 and Hubbard F-15) were assigned into six equal groups of 25 bird as follow G1, G2 and G3 were vaccinated with IBV Ma5 and 4/91 strains at day 8 and 21 respectively, while the last three groups G4, G5 and G6 did not vaccinated with IB vaccine and remained as control groups. The result revealed that the Hubbard chicken strain had moderate to severe post vaccinal reaction represented by deciliation and necrosis of mucosal epithelia, also desquamation of goblet cells and epithelia with mild infiltration of lymphocyte in the lamina propria with blood vessels congestion after 2 days of vaccination. Then focal sloughing of epithelial mucosa with sever hyperplasia of sub mucosal glands together with mild to moderate lymphocytic infiltration blood vessels congestion and multifocal deciliation of tracheal epithelia after 10 days of vaccination. In conclusion, Hubbard chicken strain may have the lowest and slowest immune response in comparison with Ross and Cobb chicken strains.

Key words: tracheal histopathology, infectious bronchitis vaccines, broilers strains.

الخلاصة:

اجريت الدراسة على ثلاث سلالات مختلفة من افراخ دجاج اللحم وهي كوب 500 وروز 308 وهابرد F-18 وتم اخذ مائة وخمسون فرخاً ووزعت الى ستة مجاميع متساوية. لقحت المجاميع الثلاثة الاولى بجرعتين من لقاح فايروس التهاب القصبات المعدي عتري Ma5 و 91/4 في اليومين الثامن والاحدى وعشرون على التوالي بينما بقيت المجاميع الثلاثة الاخرى بدون تلقيح واعتبرت كمجاميع سيطرة. درست التغيرات المرضية النسيجية للقصبات الهوائية في السلالات الثلاث في اليومين الثاني والعاشر بعد كل من التلقيح الاول والثاني. استنتج من ذلك وجود استجابة التهابية لسلالة هابرد ابطا و اقل مقارنة مع السلالتين كوب وروز.

Introduction

Poultry is an important source of meat worldwide, and the consumption of poultry products is still increasing. Broiler breeds are selected for their rapid growth, chicks are growing from 50 g at day of hatch to more than 2 kg within 6 weeks (1). Genetic developments of new broiler strains for rapid growth together with intensive husbandry conditions have expedite the outbreaks of avian diseases (2, 3).

Infectious bronchitis virus (IBV) is a very dynamic and evolving virus in most parts of the world where poultry are reared and is able to spread very rapidly in non-protected birds causing major economic losses to the global poultry industry (4, 5). Early exposure to IBV causes extensive damage to a wide range of epithelial surfaces in various parts of the body; infection of the trachea is mainly restricted to ciliated and mucus-secreting cells. The main method of protecting poultry from IB is the administration of live or killed vaccines (6). However, IB continues to cause economic losses in the poultry industry despite intensive vaccination programs in many countries (7). This is made more difficult to achieve because IBV exists in the form of many different antigenic or genotypic types, commonly referred to as variants (4). Because of the lack of researches on the influence of infectious bronchitis vaccines on different strains of broiler chickens, we constructed this study, which aims to exam tracheal histopathological changes.

Materials and methods

Birds and management

One hundred fifty chicks at one day old consist from three chicken strains of broilers (Cobb 500, Ross 308 and Hubbard F-15), 50 chicks from each

strain were purchased from local hatcheries. Upon arrival, the chicks were raised according to routine management practice as outlined by the National Research Council requirements (8). The chicks were assigned into six equal groups of 25 birds, the first three groups Ross, Cobb and Hubbard strains (G1, G2 and G3) respectively were vaccinated with live IBV Ma5 strain (Intervet - Holland) at day 8 and live IBV 4/91 strain (Intervet - Holland) at day 21 of experiment according to ELISA test, the last three groups Ross, Cobb and Hubbard strains (G4, G5 and G6) respectively were not vaccinated with live IB vaccine and remains as control groups.

Histopathological Examination

Specimens were taken from trachea at 2 and 10 days after each vaccination from all groups of experiment, the tissues were fixed, processed and stained with Hematoxylin and Eosin (H&E) stain according to Luna (9) and the histopathological changes were observed under light microscope.

Results

Histopathological changes of trachea at 2 day post first vaccination with Ma5

The non-vaccinated groups (G4, G5 and G6) with IBV showed no clear histopathological lesion (Figure 1, C). While vaccinated groups appear as follow: the G1 group showed prominence of cilia with mild to moderate epithelial mucosal hyperplasia associated with moderate lymphocytic infiltration (Figure 1, G1). Also the G2 showed prominence of cilia with diffuse lymphocytic infiltration in edematous sub mucosa (Figure 1, G2). But in the G3, the lesion revealed moderate lesions as following showed deciliation and

necrosis of mucosal epithelia also desquamation of goblet cells and epithelia with mild infiltration of

lymphocyte in the lamina propria with blood vessels congestion (Figure 1, G3).

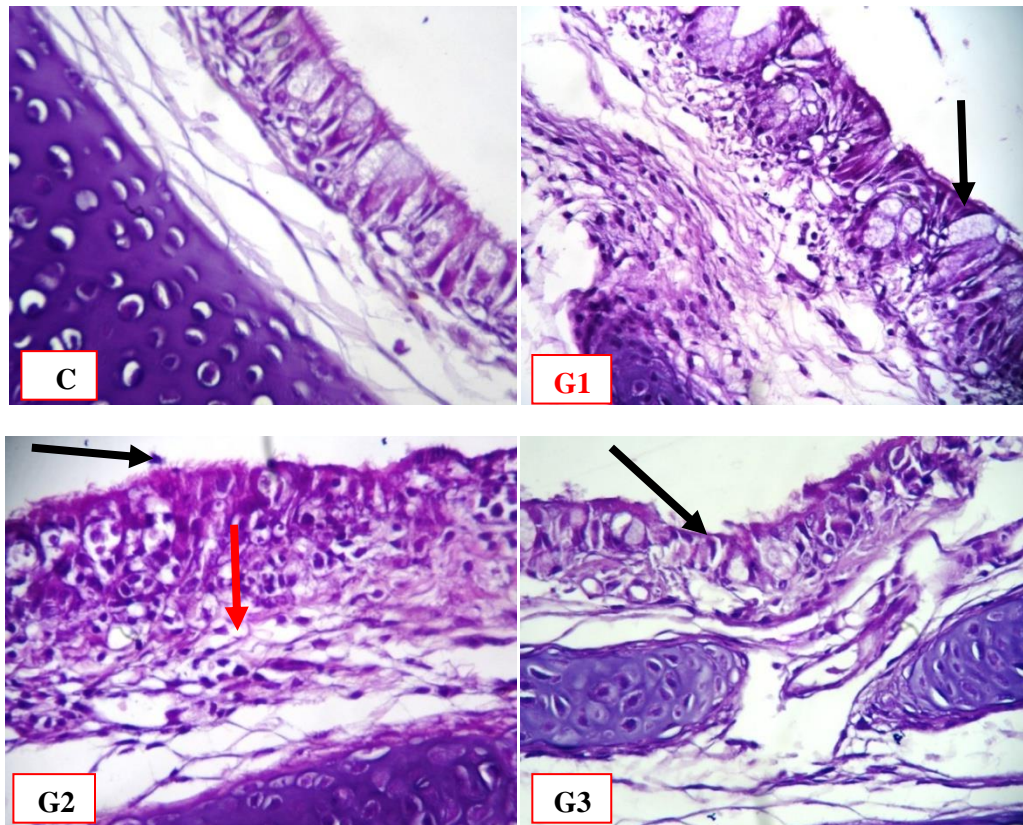


Figure 1: Histopathology of trachea at 2 day post first vaccination, (C) Normal appearance of trachea in non-vaccinated groups, (G1) showed prominence of cilia with moderate epithelial mucosal hyperplasia associated with moderate lymphocytic infiltration. (G2) showed prominence of cilia with diffuse lymphocytic infiltration in edematous sub mucosa. (G3) appear deciliation and necrosis of mucosal epithelia (X 400-H&E).

Histopathological changes of trachea at 10 day post first vaccination with Ma5

The histopathological study in all non-vaccinated groups (C) showed no clear histopathological lesions with prominence of cilia throughout mucosal layer, except little number of blood vessels congestion as in (Figure 2, C). While the vaccinated group appear as follow: the G1 exhibit a moderate hyperplasia of ciliated mucosal epithelial together with hyperplastic changes of sub mucosal gland and focal deciliation as in (Figure 2, G1). The G2 showed diffuse lymphoblastic infiltration together with goblet cell hyperplasia and hypertrophy as well as numerous blood vessels congestion (Figure 2, G2) and finally the G3 showed focal sloughing of epithelial mucosa with sever hyperplasia of sub mucosal glands together with mild to moderate lymphocytic

infiltration and blood vessels congestion and multifocal deciliation of tracheal epithelia (Figure 2, G3).

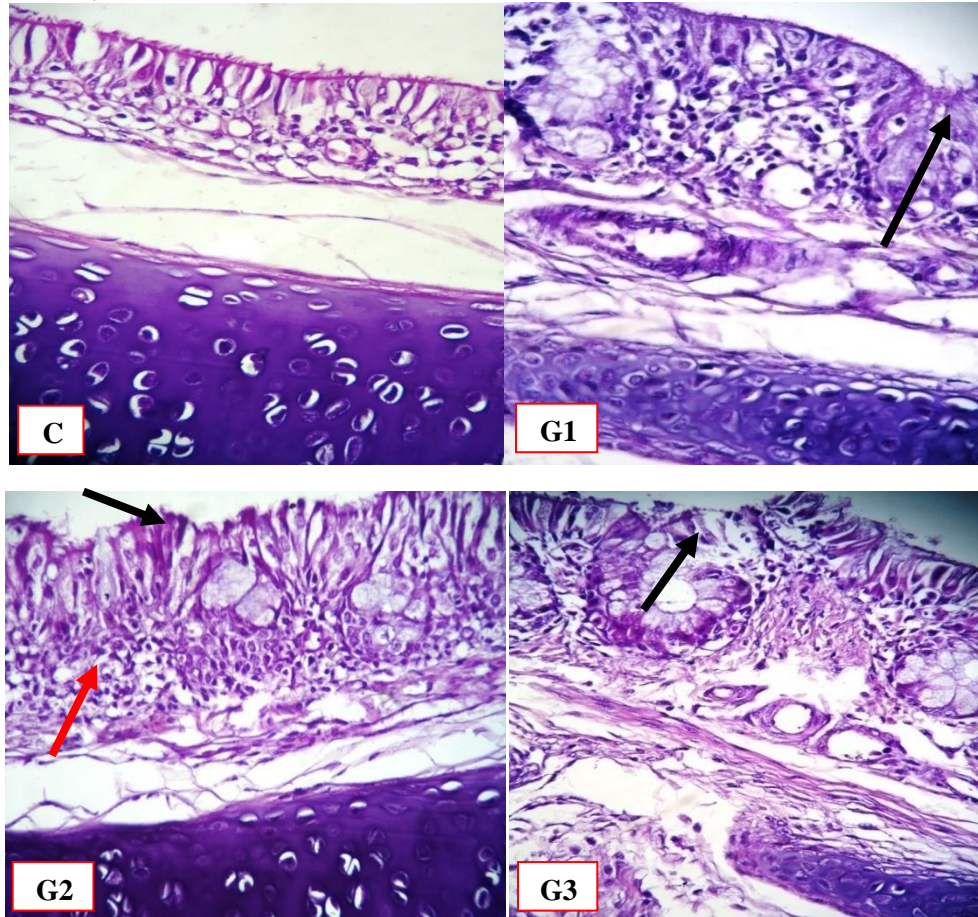


Figure 2: Histopathology of trachea at day 10 post first vaccination,(C) The normal appearance of trachea in non-vaccinated group, (G1) showed hyperplasia of ciliated mucosal epithelia (black arrow) with focal deciliation and focal lymphocytic infiltration. (G2) showed diffuse lymphocytic infiltration (red arrow) and goblet cell hypertrophy and focal deciliation. (G3) appear focal sloughing of epithelial mucosa and multifocal deciliation (X 400-H&E).

Histopathology of trachea at 2 day post second vaccination with 4/91

The histopathological results in all non-vaccinated groups of the trachea illustrate a lining with pseudostratified ciliated epithelia and no clear histopathological changes were seen (Figure 3, C). On other hand, the vaccinated groups showed differences in pathological changes among chicken strains. In G1 the tracheal lesions appear as goblet cell hyperplasia in both epithelial mucosa and mucosal gland together with blood vessels dilation, congestion and multi nucleated cells (MNCs) infiltration around blood vessels in sub mucosa (Figure 3, G1). The main lesion in G2 was focal epithelia deciliation with goblet cell hypertrophy and few numbers of cellular infiltrations mainly of MNCs (Figure 3, G2).

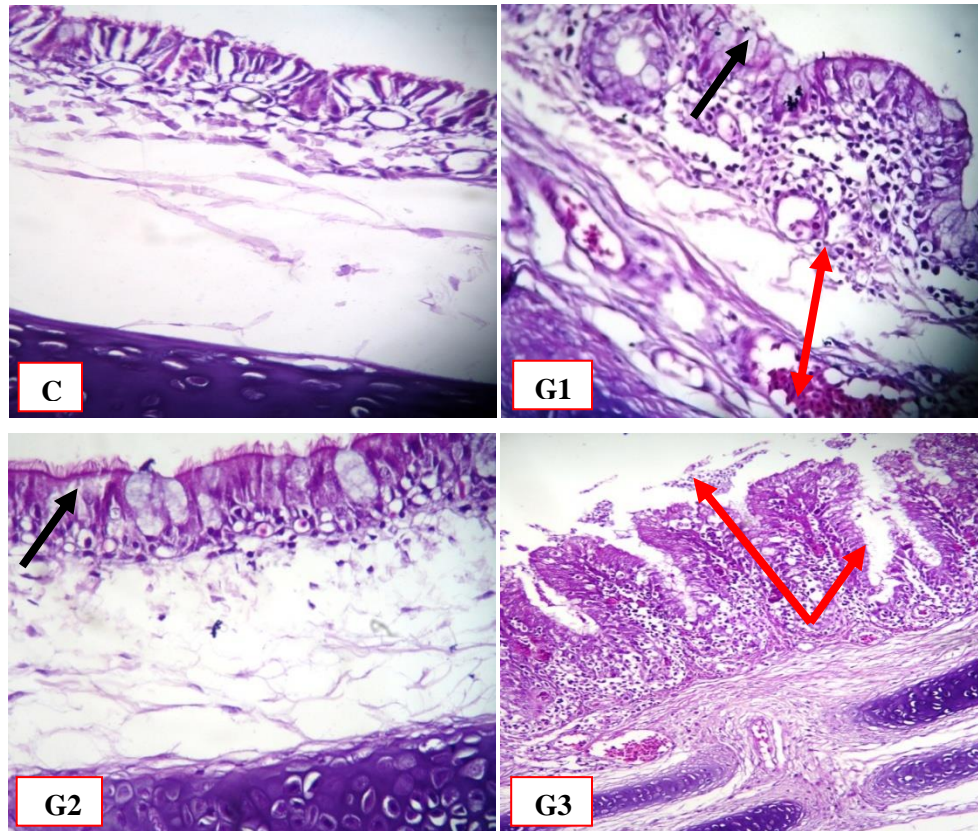


Figure 3: Histopathology of trachea at 2 day post second vaccination (C) normal appearance of trachea in non-vaccinated groups (X 400-H&E), (G1) goblet cell hyperplasia (black arrow) with congestion of blood vessels and MNCs infiltration (red arrow) around blood vessels in sub mucosa (X 400-H&E). (G2) showed focal epithelia deciliation and slight MNCs infiltration. (X 400-H&E). (G3) showed deciliation and MNCs infiltration in mucosa (red arrow) with necrosis and sloughing (X 100-H&E).

Trachea tissue epithelial of G3 showed deciliation and desquamation of mucosal epithelia and goblet cells with necrosis and sloughing with epithelial debris were seen in tracheal lumen. Also sub epithelial MNCs infiltration were evident mainly consist of lymphocyte and hetrophil together with edema and blood vessels congestion (Figure3, G3).

Histopathological changes of trachea at 10 day post second vaccination with 4/91

While normal microscopic appearance (Figure 4, C) was observed in the tracheal tissue of chickens in all non-vaccinated groups (G4, G5 and G6), the vaccinated groups have different pathological lesion at this time. The G1 group showed a diffuse MNCs aggregation in the epithelial and sub epithelial layer consist mainly of lymphocytic and plasma cells with evidence of sub mucosal edema and slight blood vessels congestion in (Figure 4, G1). In G2 tracheal lesion showed lymphocytic infiltration ranged from focal to diffuse with slight blood vessels congestion and accompanied with slight mucosal epithelial hyperplasia as in (Figure 4, G2). In the (G3) Hubbard strain the lesion appear sever more than others and showed epithelial deciliation with moderate infiltration of hetrophil and MNCs in sub mucosal layer with cystic distension of some mucosal glands with area of degeneration in mucosa and sub mucosa as in (Figure 4, G3).

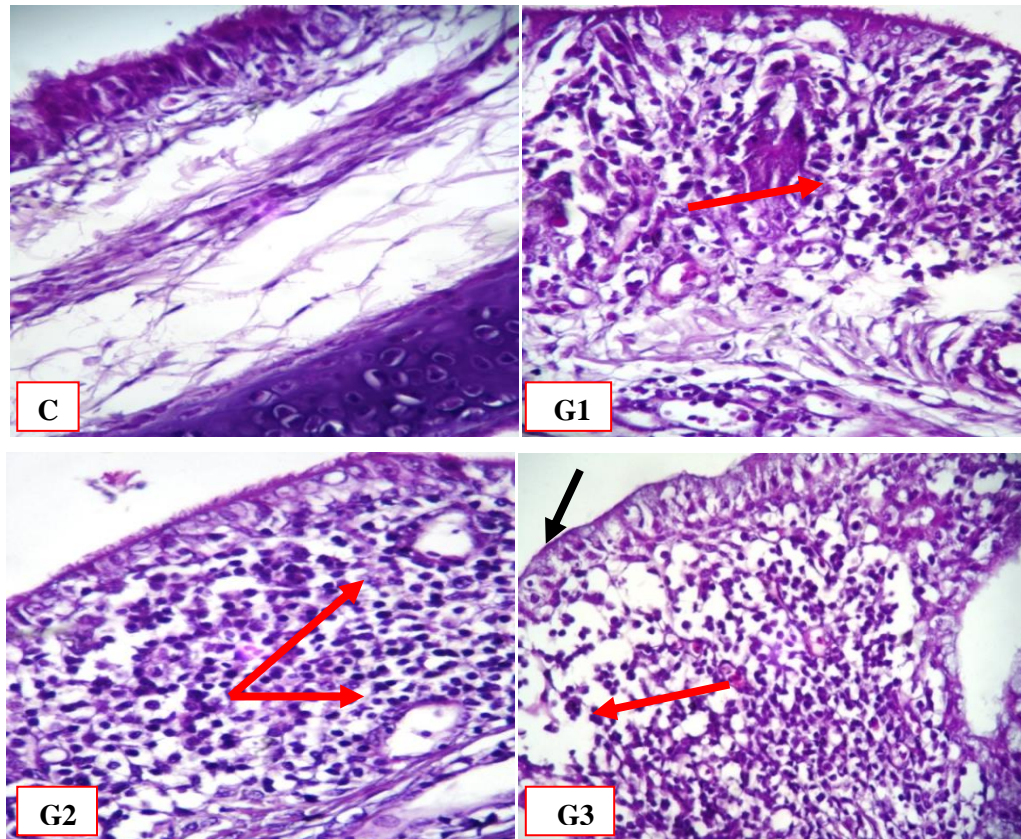


Figure 4: Histopathology of trachea at 10 day post second vaccination, (C) non-vaccinated groups revealed to no clear pathological changes were observed in tracheal tissue. (G1) showed sever and diffuse MNCs aggregation around blood vessels (red arrow). (G2) tracheal lesion showed lymphocytic infiltration (red arrow) and mucosal epithelial hyperplasia. (G3) showed epithelial deciliation (black arrow) and with area of degeneration (red arrow)in mucosa and sub mucosa (X 400-H&E).

Discussion

The IBV infection in chickens is known to be initiated by viral replication in the upper respiratory tract, which is usually restricted to the ciliated and mucus secreting cells and the trachea is a primary target organ for IBV and it is usually the main site to take the sample, especially within the first week of infection (6). Our result showed different degree of congestion in tracheal tissue ranging from mild, moderate and severe congestion this due to difference in immune response to IBV after viral tropism, lead to stimulated inflammatory cells (mainly lymphocytes and heterophils), which migrate to the

affected area through blood circulation which induced by chemotactic factors (10). It's found that the vaccination with IBV showed histopathological changes in trachea characterized by infiltration of mononuclear cells (macrophages and lymphocytes) in epithelial and sub epithelial layers and thickening of mucosa, with congested blood vessels (11). The G3 group yield severe histopathological lesions in tracheal tissue like deciliation of tracheal epithelia with necrosis and sloughing, epithelial debris were seen in tracheal lumen this lesion may be due to

secondary bacterial infection after vaccination with IBV this result compatible with Vandekerchove *et al.* (12), who proved that deciliated epithelium of trachea could be due to bacterial secondary infection after vaccination, (e.g. *Escherichia coli*), which can be the main cause of debilitating disease. In the past, the histopathology of IBV in the trachea has been extensively described, but most of the studies were limited to one strain of chickens. In the present study, histopathological lesions and the time course of the agent observed in the trachea after IBV vaccinated can be compared with the findings of Nakamura *et al.* (13), who compared the histopathology of IBV challenge in the trachea of tow chicken lines using the M41 IBV strain. However, these authors reported time frames for the various lesions that differed between the two lines of chickens studied and also differed from those found in the present study. In addition, lesions were similar for both IBV strains, indicating a similar predilection of both strains for the trachea. Lesions were more severe and persistent in both the groups of cockerels as compared with the hens, which suggest that the virus is highly pathogenic for the trachea, as evidenced by a higher incidence of hypertrophy of alveolar mucus glands and edema in the mucosa (14, 15). In our result it's found that the vaccinated G1 and G2 group (Ross, Cobb strains) had the highest resistant than vaccinated G3 group (Hubbard strain) respectively. This is may be due to the difference in the strain genotypes of Ross and Cobb breeds in comparison with Hubbard breed. This may be due to the accumulation of the genes of Ross and Cobb strain that result from massive of genetic selection to

disease resistance breeding by the primary breeders these genes are carried on MHC genes that responsible for the difference in immune response between chicken breeds (16, 17). Zhou and Lamont (18) explain that in meat-type chickens, the MHC Class IV region had significant effects in lines that had been selected for high or low early antibody response to *Escherichia coli* vaccination at 10 days of age. In conclusion, Hubbard chicken strain may have the lowest and slowest immune response in comparison with Ross and Cobb chicken strains.

References

- 1-Food and Agriculture Organization. (2010). <http://faostat.fao.org/site>.
- 2-Cheema, M. A., Qureshi, M. A. and Havenstein, G. B. (2003). A comparison of the immune response of a 2001 commercial broiler with a 1957 random bred broiler strain when fed representative 1957 and 2001 broiler diets. *Poult. Sci.* 2: 300-312.
- 3-Kemp,C. and Kenny,M. (2003). Feeding the modern broiler for more. *International Hatchery Practice*, 17:11-13.
- 4-Cavanagh, D. and Gelb, J. (2008). *Infectious Bronchitis Diseases of Poultry*. Y. M. Saif, ed. Blackwell Publishing, Iowa. pp 117-135.
- 5-Ababneh, M., Dalab, A. E., Alsaad,S., and Al-Zghoul, M. (2012). Presence of Infectious Bronchitis Virus Strain CK/CH/LDL/97I in the Middle East. *International Scholarly Research Network ISRN Veterinary Science*, Volume 2012, Article ID 201721, 6 pages.
- 6-Cavanagh, D. (2003). Severe acute respiratory syndrome vaccine development: Experiences of vaccination against avian

- infectious bronchitis coronavirus. *Avian Pathol.* 32:567-582.
- 7-Lim, T.H., Lee, H.J., Lee, D.H., Lee, Y.N., Park, J.K. and Youn, H.N. (2011). An emerging recombinant cluster of nephropathogenic strains of avian infectious bronchitis virus in Korea. *Infect. Genet. Evol.* 11:678–85.
- 8-National Research Council requirements (1994). Nutrient requirements of Poultry. Subcommittee on Poultry Nutrition Committee Animal Board on Agriculture 9thed.
- 9-Luna LG. (1968) Routine staining procedures. Hematoxylin and eosin stains. Manual of histologic staining methods of the Armed Forces Institute of Pathology. 3rd ed. New York: McGraw- Hill, 32–9.
- 10-Saif, Y.M., Barnes, H.J., Glisson, J.R., Fadly, A.M., Mc Dougald, L.R. and Swayne, D.E. (2008). "Diseases of Poultry". 12th Ed., Iowa State Univ. Press. Blackwell Publishing Company, Iowa, USA. : 117-129.
- 11-Al-Hamadany, S.M. and Qubih, T.S. (2009). Histological study on the effect of infectious bronchitis vaccine strain H120 in broilers. *Iraqi J. Vet. Med.* 23(2): 333-337.
- 12-Vandekerchove D., De Herdt P., Laevens H., Butaye P., Meulemans G., Pasmans F., (2004). Significance of interactions between *Escherichia coli* and respiratory pathogens in layer hen flocks suffering from colibacillosis-associated mortality, *Avian Pathol.* 33:298–302.
- 13-Nakamura, K., Cook, J. K. A., Otsuki, K., Huggins, M. B. and Frazier, J. A. (1991). Comparative study of respiratory lesions in two chicken lines of different susceptibility infected with infectious bronchitis virus: histology, ultrastructure and immunohistochemistry. *Avian. Pathol.* 20:241-257.
- 14-Chousalkar, K. K. Roberts, J. R. and Reece. R. (2007). Comparative Histopathology of Two Serotypes of Infectious Bronchitis Virus (T and N1/88) in Laying Hens and Cockerels *Poult. Sci.* 86:50–58.
- 15-Bezuidenhout, A. Mondal, S. P. and Buckles, E. L. (2011). Histopathological and Immunohistochemical Study of Air Sac Lesions Induced by Two Strains of Infectious Bronchitis Virus *J. Comp. Path.* 145: 319-326.
- 16-Biozzi, G., Mouton, D., Heumann, A. M., Bouthillier, Y., Stiffel, C. and Mevel, J. C. (1979). Genetic analysis of antibody responsiveness to sheep erythrocytes in crosses between lines of mice selected for high or low antibody synthesis. *Immunolo.* 36: 427- 438.
- 17-Lamont, S.J. (1998). Impact of genetics on disease resistance. *Poult. Sci.*, 77:1111-1118.
- 18- Zhou, H. and Lamont, S. J. (2003). Chicken MHC class I and II gene effects on antibody response kinetics in adult chickens. *Immunogenetics*, 55(3):133-140.