

Clinical, Histopathological and Molecular detection of cutaneous papillomatosis associated with bovine papillomavirus types 1 and 2 in cattle from Al-Qadisiya Province

Khalefa Ali Mansour

Department of Internal Medicine, College of Veterinary Medicine,
University of Al-Qadisiya

E. mail: khalefa.mansour@yahoo.com

Mobile: 07813611358

Abstract

This study was designed to evaluate the clinical, histopathological and molecular features of cattle warts disease in Al-Qadisiya government. Fourteen samples from skin lesions were collected from cattle that were diagnosed as cutaneous papilloma by clinical examination. All samples were examined for the presence of cutaneous fibropapillomatosis and confirmed histopathologically and by molecular detection by (PCR) for BPV-1 and BPV-2 as causative agents for the bovine cutaneous papillomatosis.. The results of this study showed that lesions were mostly located on the head and neck, perineal region, under the chin and around eyes. The histopathological changes of cauliflower-like growths of varying size (1-4 cm³) revealed various degrees of hyperplasia, hyperkeratosis and acanthosis in all samples .The results of multiplex PCR for genotyping (BPV-1 and BPV-2) by using specific primers for L-major capsid protein revealed that eleven out of fourteen tissue samples were positive results for (BPV-1-L1 gene) and all the samples were negative result for (BPV-2-L2 gene) .

On conclusion the bovine papillomatosis Who was diagnosed in Al-Qadisiya Province is caused by bovine papillomavirus types 1 (BPV-1-L1 gene) and has atypical characteristic clinical sings which make it easily to distinguish from other skin disease .

Key word: cattle warts, (BPV-1/2), Papillomatosis, PCR, Cutaneous lesions

التشخيص السريري, النسيجي والجزئي لمرض الورم الحليمي الجلدي والمتسبب عن الفيروس البقري الحلمي (نوع 1 و2) في ابقار في محافظة الديوانية

الخلاصة

صممت هذه الدراسة لتقييم الخصائص السريرية, النسيجية والجزئية لمرض الثآليل البقري في محافظة القادسية. تم جمع اربعة عشر عينة من الجلد من ابقار تم تشخيصها سريريا على انها مصابة بمرض الورم الحليمي الجلدي. تم فحص جميع العينات للبحث عن وجود الورم الحليمي المتليف وتم تأكيد التشخيص نسيجيا وجزئيا لوجود BPV-1 و BPV-2 كمسبب للإصابة في الابقار. أظهرت النتائج ان معظم الآفات متموضعة في الراس, العنق, المنطقة الاربية, تحت الذقن وحول العين. واطهرت التغيرات النسيجية للنمو الذي يشبه القرنبيط و بأحجام مختلفة تتراوح بين (1-4 سم3) درجات مختلفة من فرط التنسج وزيادة في الطبقة المتقرنة

والمشوكة. كما اظهرت نتائج تفاعل سلسلة البلمرة لتشخيص BPV-1 و BPV-2 وباستخدام البادئات الخاصة ان 11 عينة من بين 14 عينة كانت موجبة لنوع BPV-1 . نستنتج من هذه الدراسة ان مرض الجلد الحلمي البقري الذي تم تشخيصه في محافظة القادسية هو متسبب عن فايروس الحلمي الجلدي البقري نوع - 1 وله علامات سريرية واضحة يمكن من خلالها تمييزه بسهولة عن الامراض الجلدية الاخرى.

Introduction

Bovine cutaneous papillomatosis is a disease that caused by bovine papillomavirus (BPV) and characterized by proliferation of connective tissue ,hyperkeratosis and epithelial hyperplasia. Cattle warts have been appeared mainly on the skin, teats and mucosal surfaces of cattle (1, 2 and 3).

Bovine papillomaviruses (BPV) are the causative agent of papillomatosis tumors in skin, upper gastrointestinal tract and urinary bladder. BPV have eight identified genotyping related to squamous papillomas and cutaneous fibropapillomas of the skin and esophagus and carcinomas (4).

BPV-1 and BPV-2 are associated with fibropapillomas in cattle; BPV-1 and BPV-2 are classified in the genus deltapapillomavirus and infect the epithelium and dermis, giving rise to fibropapillomas (5 and 6).

These (BPV) induced lesions leads to hyperplastic lesions defined as warts, papillomas are initially benign in nature and self-limiting spontaneously but can developed to cancer under the effect of the environmental co-factors (7).

The most common sites for pathological changes similar to warts appear on neck, head, perianal region, around eyes, ears and may spread to other areas of the body (8, 9 & 10).

Cattle warts can appear on cattle of any age; the disease is more severe in young animals less than two years of age. The infection with bovine papillomatosis can result in significant economic losses in animal husbandry due to worse quality of hide and meat and reduced milk production (5 and 11).

The aim of this study was to detect the clinical, histopathological and molecular features BPVs type 1 and type 2 in association with cases of papillomatosis from cattle of Al-Qadissiyia governorate . This study represents the first detection of the BPV1 and BPV2

Materials and Methods

Samples collections: wart biopsies were collected from different sites of body (neck, around the eyelid, perineal region) from cow chronically affected with cutaneous papillomatosis from different fields in Al-Qadissiyia province. They were placed in sterile container and transported to the laboratory as soon as possible in cooled boxes for further investigations, another biopsies tissue samples were collected from warts lesion by incision tissue pieces about 2–5 cm³ by surgical blade and sterile artery forceps and transported into sterile container with 10% formalin to the laboratory as soon as possible. Samples were submitted to molecular analyses and histological study.

Genomic DNA Extraction: Viral genomic DNA was extracted from frozen skin lesions (warts) samples by using (Genomic DNA Mini Kit, Geneaid, USA). The extraction was done according to company instructions by using tissue extraction protocol method with proteinase K..

Measurement of genomic DNA extraction: The extracted genomic DNA was checked by using Nanodrop spectrophotometer that check genomic DNA concentration and estimation of DNA purity through reading the absorbance at (160 /210 nm).

Multiplex PCR amplification:
Multiplex PCR was performed for detection and genotyping of bovine papillomavirus virus from cattle by using BPV-1 and BPV-

12 specific primers for *L-major capsid protein gene*. These primers were designed using NCBI-GenBank and primer 3 plus design online as shown in table (1).

Table (1); Primers designed using NCBI-GenBank

Primer	Sequence		Amplicon	GenBank
BPV-1 L1 gene	F	CGGGGCCAAAACCTGTTTCCTA	399bp	KF284141.1
	R	AATTCAAGAGGAGGGCAGGC		
BPV-2 L2 gene	F	CCAGTGGATCCTTGGTGTCC	538bp	KC256805.1
	F	GCCCCTTGCTGAGCTAAGAA		

These primers were provided by (Bioneer company. Korea). PCR master mix was prepared using the protocol of AccuPower® Gold Multiplex PCR PreMix kit; Bioneer; The PCR products were examined by electrophoresis in 1.5% agarose gel, stained with ethidium bromide, and visualized under UV transilluminator.

Histopathology: samples of (2-5cm³) biopsy were collected and placed into fifty milliliter sterile disposable container with 10%formalin, the wound was sutured. Preparation of the samples to histopathological sectioning according to (12 & 13).


Results

Clinical result: The results of clinical examination showed skin lesions as group or

single take place in different sites of the body; The most common site of papillomas appears on the skin of shoulders, neck and head; most commonly around the eyes and the skin warts may spread to any part of the body ;The lesions vary in size from (1-5) cm³ and characterized by proliferative dry growth and horny cauliflower-like appearance as shown in figures 1, 2 & 3. In most animals they regress spontaneously. Another skin lesions were found around the eye, and perineal region (around anus) as shown in figure (3 & 4) .



Fig(1): Large multiple warts, showing the cauliflower-like appearance cover the head and neck



Fig(2): Small multiple lesion, distribution under the chin region



Fig (3): single small warts appears around eyes

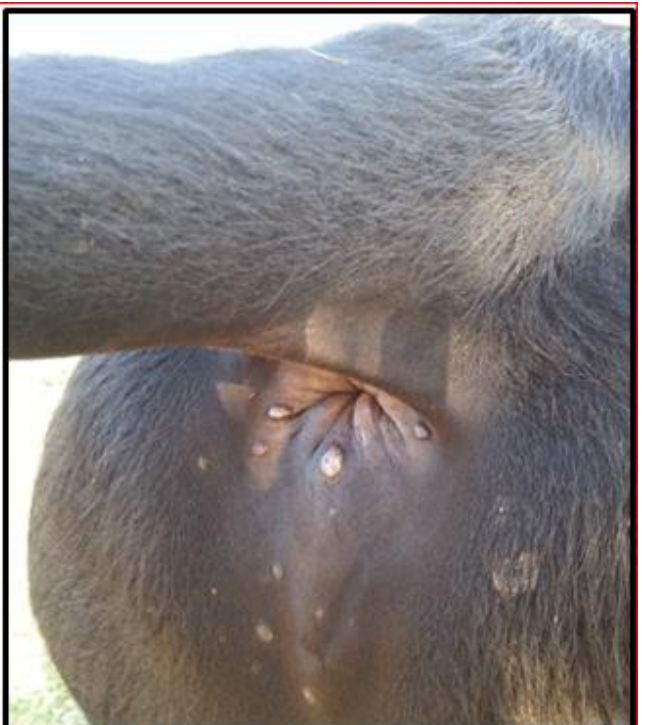


Fig (4): show distribution of multiple small warts in the perineal region

Histopathological result: The results of histopathological changes of the effected skin included a marked hyperkeratosis with downward hyperplasia like finger projection of stratum basale with presence of fibrovascular core as shown in figure (5). Also the result showed hypergranulosis (proliferation of granulocytes) with hydropic degeneration of granulocytes in the stratum granulosum as shown in figure (6). Furthermore; there was marked acanthosis, hyperkeratosis and downward hyperplasia as shown in figure (7). All former histological changes were not present in figure (8), which showed normal tissue of the skin that revealed thin keratinized layer with normal epidermal layers, presence of skin adnexar in the dermis like sweat gland and hair follicles.

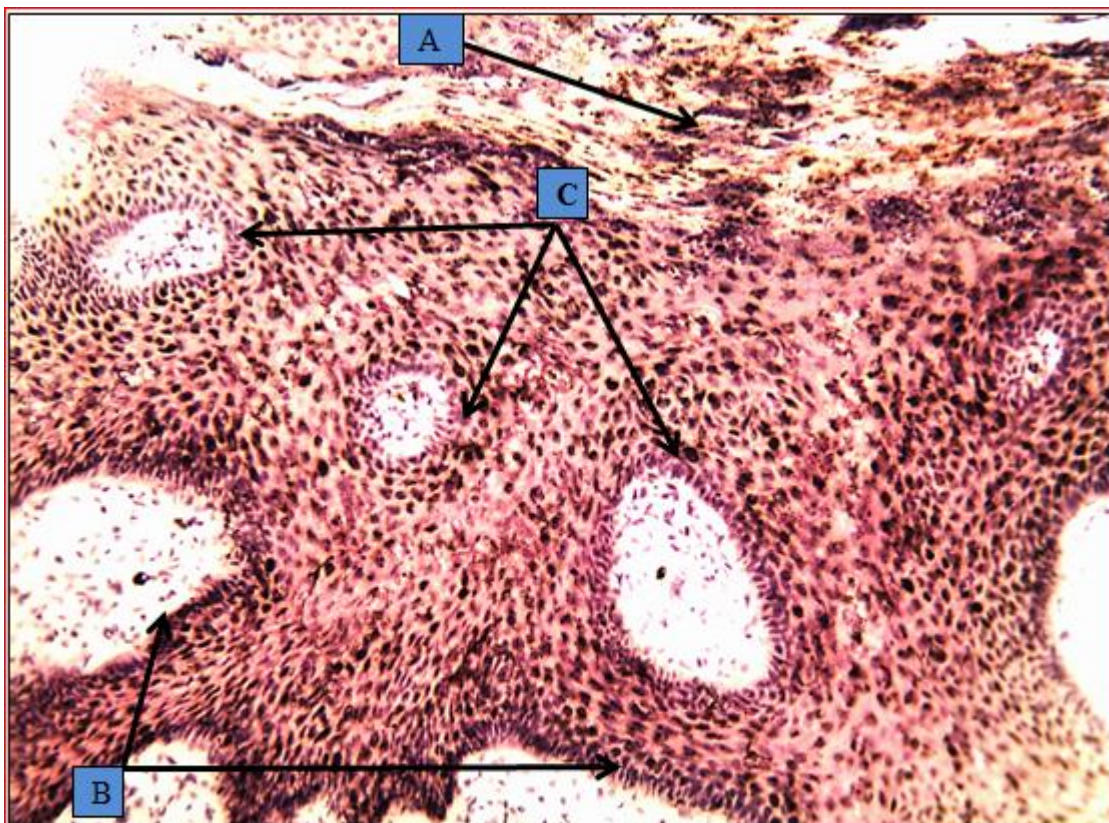


Fig (5) :
A:marked hyperkeratosis.
B:downward hyperplasia of stratum basale.
C: presence of fibrovascular

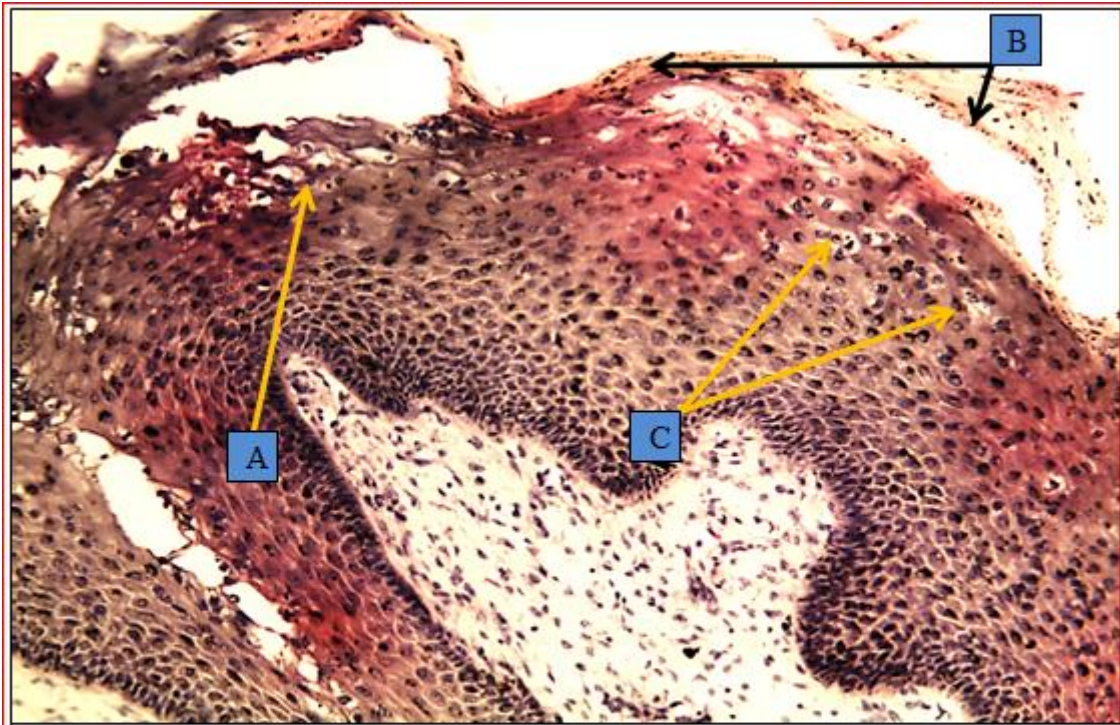


Fig (6) :
A: hydropic degeneration of granulocytes .
B: hyperkeratosis .
C: hypergranulosis (proliferation of granulocytes in the stratum granulosum

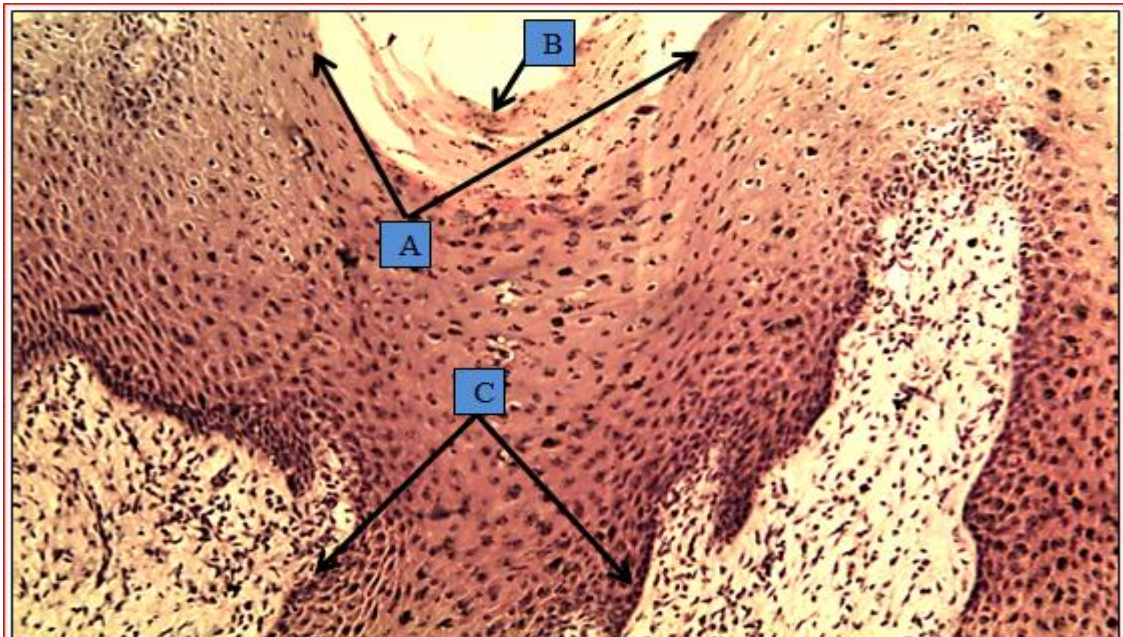


Fig (7) :
A: marked acanthosis .
B: hyperkeratosis .
C: downward hyperplasia.

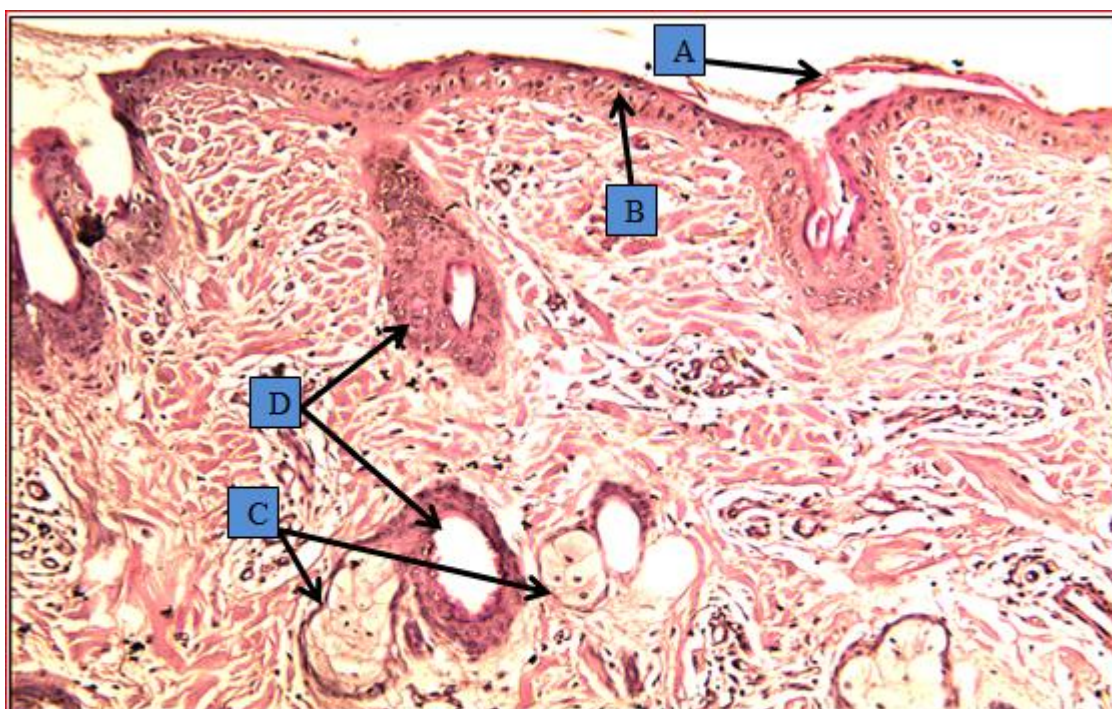


Fig (8) :


A: there is thin keratinized layer

B: normal epidermal layers .

C: skin adnexa in the dermis like sweat gland and hair follicles.

D: skin adnexa

Molecular results: The results of Multiplex PCR for detection genotypes of bovine papillomavirus virus from cattle by BPV-1 and BPV-2 specific primers for *L-major capsid protein gene* in ethidium bromide – stained agarose gel using specific primers for detection of (BPV-1/ L1 gene) (399 bp), (BPV-2/ L2 gene) and the ladder size was (20000 bp), 11 out of 14 tissue samples were positive for (BPV-1/L1 gene) and all samples were negative for (BPV-2/L2 gene), as shown in figure (9).



Fig, 9 :Agrose gel electrophoresis image that show the PCR products of Bovine papillomavirus type 1 major capsid protein (L1) gene in skin lesion of cattle.. where, M: Marker (20000-100bp). Lane (2, 3, 4, 6, 7, 8, 10, 11, 12, 13, and 14) positive samples at 399bp PCR products size.

Discussion :

The clinical examination of the skin showed the warts take place indifferent sites of the body and this result agreed with (14). Also the presence papillomas on the shoulder ,neck and head most commonly around the eyes and the warts may spread to any region of the body with vary in size from (1-5)cm³ and characterized by proliferative dry growth and horny cauliflower-like appearance this result similar to(14,15) who had that the most common warts found on the head neck and shoulder but may also occur in other location ;Another lesion were found around the eye, perinal region (around anus) which deals with the (14,16,17).

The histological changes that noted on the affected skin which include hyperkeratosis with down hyperplasia like finger projection of stratum basale with presence of fibrovascular core; also hypergranulosis with hydropic degeneration of degeneration of granulocytes in the

stratum granulosum This result agreed with (19 & 11).

Furthermore; there was marked acanthosis, hyperkeratosis and downward and presence of skin adnexar in the dermis like sweat gland and hair follicles. All of these results are similar to the results explained by (4 & 20).

In this study the result of Multiplex PCR for detection genotyping of bovine papillomavirus virus from cattle is caused by BPV-1 and this result agreed with (15,20,21,22,23).

Bovine cutaneous papillomatosis disease; as a conclusion; spread in a AL-Qadissiyia governorate and the disease have atypical clinical signs and characteristic ,histopathological feature that used in the primary diagnosis. PCR assay was confirmative and rapid that was used in detection of small amounts of DNA of the virus .

Reference

- 1- **Kumar, P, Nagarajan, N, Kumar, D, Bind, RB, and Somvanshi, R, (2013a)** Detection and quantification bovine papillomaviruses (BPVs) in cutaneous warts of cattle and buffaloes. *Advances in Animal and Veterinary Science*, 1: 53–58.
- 2- **Maeda, Y, Shibahara, T, Wada, Y, Kadota, K, Kanno, T, and Uchida, I, Hatama, S, (2007)** An outbreak of teat papillomatosis in cattle caused by bovine papilloma virus (BPV) type 6 and unclassified BPVs. *Veterinary Microbiology*, 121, 242–248
- 3- **Kumar, P, Nagarajan, N, Saikumar, G, Arya, RS and Somvanshi, R, (2013b)** Detection of bovine papillomaviruses (BPVs) in war-like lesions of upper gastrointestinal tract of cattle and buffaloes. *Transboundary and Emerging Diseases*, 10:1111/tbed.12127.
- 4- **Mustafa, K, (2011)** Clinical, pathological and immunohistochemical findings of bovine cutaneous papillomatosis. *Ankara univ Vet. Fak. Derg*, 58: 161-165.
- 5- **Campo, MS, (2002)** Animal models of papillomavirus pathogenesis. *Virus Res*, 89:249-261.
- 6- **De Villiers, EM, Faquet, C, Brooker, TR, Bernard, HU and Hausen, H, (2004)** Classification of papillomaviruses. *Virology* 324, 17–27.
- 7- **Lunardi, M, Alfieri, AA, Otonel, RA, de Alcantara, BK ,Rodrigues, WB, de Miranda, AB and Alfieri, AF (2013)** Genetic characterization of a novel bovine papillomavirus member of the Deltapapillomavirus genus. *Veterinary Microbiology*, 162: 207–213.
- 8- **Sabine, B, Rhea, H, Angelika, S, Reinhard, K, and Christian, S (2008)** Peripheral blood mononuclear cells represent a reservoir of bovine papillomavirus DNA in sarcoid-affected equines . *Journal of General Virology*, 89, 1390–1395.
- 9- **Borzacchiello, G, Iovane, G, Marcante, ML, Poggiali, F, Roperto, F, Roperto, S, and Venuti, A, (2003)** Presence of bovine papillomavirus type 2 DNA and expression of the viral oncoprotein E5 in naturally occurring urinary bladder tumours in cows. *J. Gen. Virol.* 84:2921-2926
- 10- **Wosiacki, SR, Claus, M P, Alfieri, AF, and Alfieri, AA, (2006)** Bovine papillomavirus type 2 detection in the urinary bladder of cattle with chronic enzootic haematuria. *Mem. Inst. Oswaldo. Cruz.*, 101:635-638.
- 11- **Jelinek, F. and Tachezy, R, (2005)**. Cutaneous papillomatosis in cattle. *J. Comp. Pathol.* 132, 70-81,.
- 12- **Al-Attar, A, Al-Allaf, SM, and Al-Moktar, KA, (1982)**. Microscopic preparations. (1sted.). National Library in Baghdad. Iraq. (In Arabic).
- 13- **Noory, M. A. (1989)**. Science Technology microscopic slides. Mosul University. Higher Education Press. (In Arabic).
- 14- **Radostitis, OM, Gay, CC, Hinchcliff, KW, and Constable, PD, (2007)** *veterinary medicine* , 10th Edition. London : W.B.Saunders Company Ltd, P.1421- 1423
- 15- **Mehmet, TT, Yakup, Y, Mahmut, S, Seval, BD, Volkan, Y, Ali, HK, Erhan, GA (2012)** Histopathological, Immunohistochemical and Molecular Study of Cutaneous Bovine Papillomatosis Kafkas. *Univ. Vet. Fak. Derg.* 18 (5): 739-744.
- 16- **Nenad, T, Zeljko, Z, Vilim, S, Snjezana, K, Tomislav, B, Mario, K, Stipica, C, Ljubo, B, and Zoran, M, (2005)**: detection of bovine papillomavirus in tumour tissue and efficacy of treatment

- using autogenous vaccine and parammunity inducer *Vet. arch.*, 75 (5), 391-397.
- 17- **Nenad, T, Željko, Z, Tomislav, B, Mario, KSC, Ljubo, B, and Zoran, M, (2005)** Severe bovine papillomatosis: detection of bovine papillomavirus in tumour tissue and efficacy of treatment using autogenous vaccine and parammunity inducer, *veterinary ski. Arhiv.* 75 (5), 391-397
- 18- **Giuseppe, B, Giuseppe, I, Maria, LM, Federica, P, Franco, R, Sante, R, and Aldo, V, (2003)** Presence of bovine papillomavirus type 2 DNA and expression of the viral oncoprotein E5 in naturally occurring urinary bladder tumours in cows. *Journal of General Virology* 84, 2921–2926
- 19- **Claudia, C, Tozato¹, ML, Alice, FA, Rodrigo, AA, Otonel, GW, Di, S, Brígida, K, Selwyn, AH, Amauri, AA, (2013).** Teat papillomatosis associated with bovine papillomavirus types 6, 7, 9, and 10 in dairy cattle from Brazil *Brazilian Journal of Microbiology* 44, 3, 905-1678-4405.
- 20- **Claus, MP, Lunardi, M, Alfieri, AA, Otonel, RAA, Sartori, D, Fungaro, MHP, Alfieri, AF, (2009)** Multiple bovine papillomavirus infections associated with cutaneous papillomatosis in brazilian cattle herds. *Braz. Arch. Biol. Technol.*, 52:93-98.
- 21- **Silva, MAR, Batista , MVA, Pontesa, NE, Santosa, EUD, Coutinhob, LCA, Castrob, RS, Balbinoa, VQ, and Freitas, AC, (2013)** Comparison of two PCR strategies for the detection of bovine papillomavirus *.Journal of Virological Methods* ,192 : 55– 58.
- 22- **Kumar, P, Jangir, BL, Saikumar, G, Somvanshi, (2013).**Co-infection of bovine papillomavirus type-1 and -10 in teat warts of dairy cattle *.Veterinarni Medicina*, 58, (12): 605–608.
- 23- **Silvestre, O, Borzacchiello, G, Nava, D, and Iovane, G(2009)** Bovine papillomavirus type 1 DNA and E5 oncoprotein expression in water buffalo fibropapillomas. *Vet. Pathol.* 46: 636-641.