

## Histological and surgical study of the henna on wound healing in animals Field ( Sheep )

Ahmed Jasim Mohammad

### Abstract

wounding in first group, while in second group it was more than 4 weeks. Within the clinical follow up, no complications occurred in the first group, while the second group showed some complications such as infection and abscess formation. Histopathological examination showed formation of granulation tissue in Henna treated group was faster than control group and the regular collagen fiber noticed at 15 days post treated with Henna.

The present study demonstrates that use of Henna is useful for treatment and accelerates healing of full thickness wounds of skin in the current study was conducted to evaluate the efficacy of Henna in the treatment of skin wounds in sheep ( 5 ) , Awassi rams were used in this study.

The animals were randomly 2 groups ( control & treated ) , 5cm injury full-thickness skin wound was created on the right flank region of each animal. The wounds in first group were treated with Henna single daily after operation until complete healing was occurred, while its in second group treated with sterile saline solution as control group.

The results revealed the wound healing process in Henna treated group occurred faster than the control group , the healing occurred in 14-15 days after treated .

**Keyword: Henna, Sheep's, Surgical Sutures ..**

### Introduction :

Thus medicinal plants extract are used as alternative antibacterial compounds with high activity, low toxicity, cheaper, and more effective and Henna (*Lawsonia inermis*) is one of good example for these plants .

Henna or Hine (*Lawsonia inermis*, syn. *L. alba*) is a flowering plant, 2-6m in height. It is the sole species in the genus *Lawsonia* in the family Lythraceae (1). Henna, produces a burgundy dye molecule, Lawson (2), This molecule has an affinity for bonding with protein, and thus has been used to dye skin, hair, fingernails, leather, silk and wool. The

dye molecule, Lawson, is primarily concentrated in the leaves. In some parts of the world, plants and herbs are still the prime medicines used in medical treatment (3).

*L. inermis* is widely grown in various tropical regions in Asia, America and Africa. In Arabic, the word "henna" refers to *L. inermis* (4). Its core chemical components are the main one 2-hydroxynaphthoquinone (Lawson) about 0.5-1.5% of henna, mannite, tannic acid, mucilage and Gallic acid.

The main uses of henna are as a cooling agent, astringent, anti-fungal

and anti-bacterial herb for the skin and hair (5). Also it used as an anti hemorrhagic, intestinal antineoplastic, cardio-inhibitory, hypotensive, and a sedative. It has been used both internally and locally in jaundice, leprosy, smallpox, and affections of the skin. Henna has exhibited ant fertility activity in animals and may induce menstruation. As a cooling agent it is used for burning of skin , It also has great dandruff fighting ability. Alcoholic extract of the leaves showed mild anti- bacterial activity against *Staphylococcus aureus* and *E. coli*'.

Some experimental and clinical studies have reported antibacterial and antifungal effectiveness and wound healing activity of this product (6). The purpose of this study was to evaluate the antibacterial properties of henna extracts in vitro and the anti inflammatory and wound healing activity in vivo(7).

An attempt was made to have a better understanding of wound healing in skin of adult rabbits (8).

Stages of healing showed in during microscopic changes in epidermal and dermal regions , The ratio of changes was rapid up during 48 hours (9) .

The epithelium invaded actively underlying connective tissue. There was a closely packed mass of cells immediately subjacent to the epithelium, also there was an appearance of collagen fibers laying between the cells , Close contact between dermal and epidermal cells was happened at the time when epithelial invasion and basement membrane was reformed close to the epithelium(10).

Used henna to stop the bleeding Introduction nose and bleeding Nose back and bleeding ulcer duodenal (11).

Henna counter the impact of the virus shows that clear from the results in the treatment of warts large and multiple as they are glued paste henna on the warts can also use henna to treat AIDS, a cheap treatment and has no side effects (12)

Can be used henna in preventive medicine, especially to protect the feet of diabetic patients also can be used in the treatment of back pain and disease ulcerative colitis by putting it in an enema showed some scientific studies that henna when taken as a medicine that can affect (13) the body by slowing the heartbeat rate, reduced blood pressure, muscle spasms and inflammation, fever and pain and to act as a sedative (14)

Has taken antibacterial properties and anti-fungal and viruses from henna plant leaves has been proven that (15) the henna leaves powder can be a cure for amebic intestinal (protozoan infection in the intestine) and can be treating infections caused by nematodes (16) .

The laboratory studies for medical preparations containing showed Henna having two boats (Lawson & Isoplumbagin) for two anti-cancer effect and protect the sickle cells (17) .

## Materials and methods

### Materials :

- 1- Henna powder yellow.
- 2- Lidocaine.
- 3- Surgical scalpel
- 4- Surgical scissors .
- 5- Alcohol (sterile) 70% .
- 6- Water and soap to wash the area required to cause injury .
- 7- Surgical scissors and shaver to prepare the site surgically .
- 8- Use of (5) sheep Awassi .

Prepare the area surgically cut wool in an area of the wound - shaving wool in the conduct of the wound , sterilize the area and the creation of the wound area ( 5 cm ) , we use in the sterilization of alcohol by 70%, then use a scalpel surgical events were injured and before that flank region topically using a local anesthetic ((Lidocaine each 1 cm use 1cc, after anesthesia and wound events put yellow henna powder over the entire region directly on the wound without that we suit.

Days sampling :

1- The first sample after 5 days to put henna on the wound.

Results :

The control group:

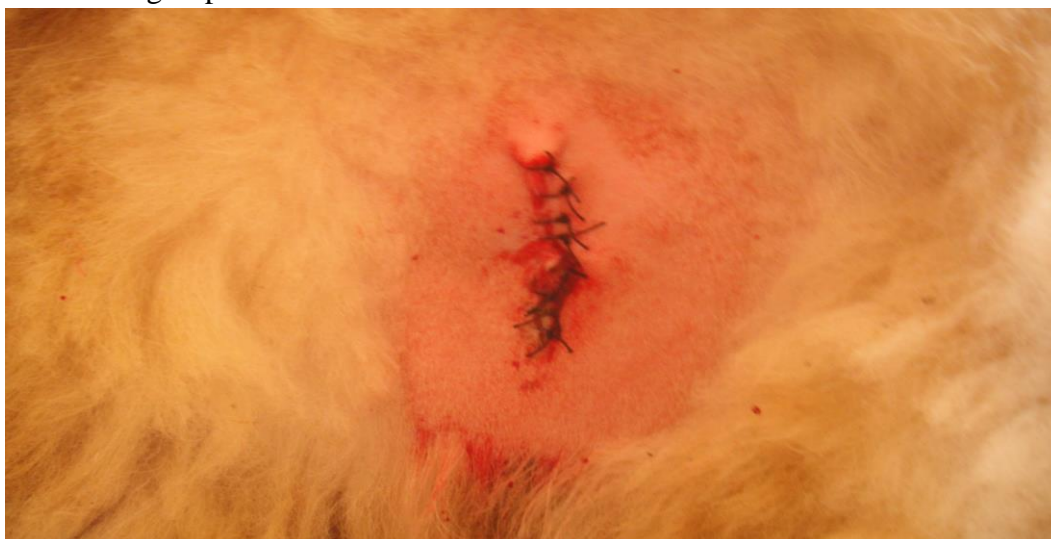2- The second sample after 10 days to put henna on the wound.

3- The third sample after 15 days to put henna on the wound.

4- The fourth sample after 20 days to put henna on the wound.

5- The control to be compared with the first four samples.

Send the samples to the Histopathological unit for the purpose of preparation of histological slides for wound healing and a stage of wound healing was.



figure(1): Stitching the wound with the use of antibiotics (control )

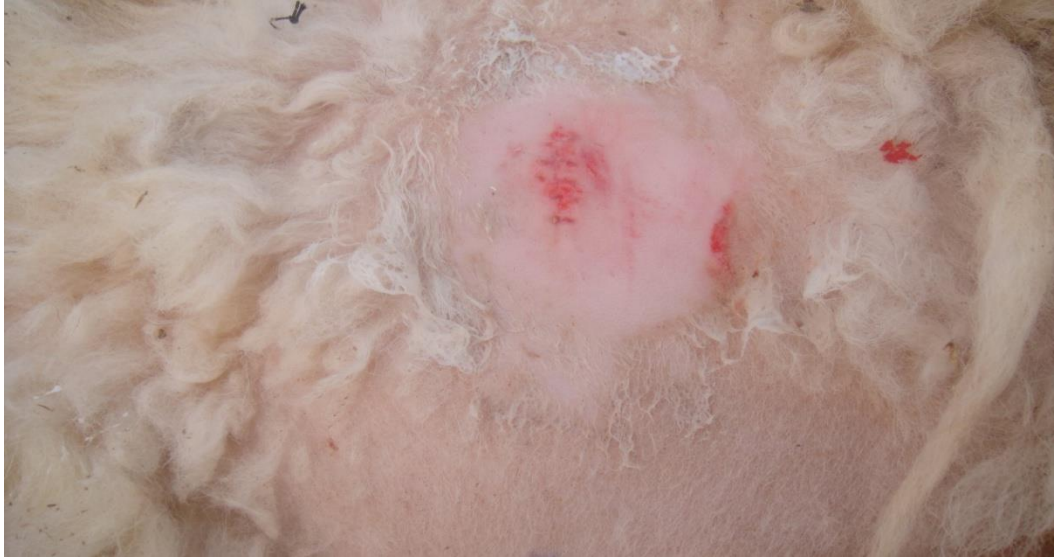

Figure (2):After the passage of (5) days notice the beginning of wound healing (formation of collagen fiber) .

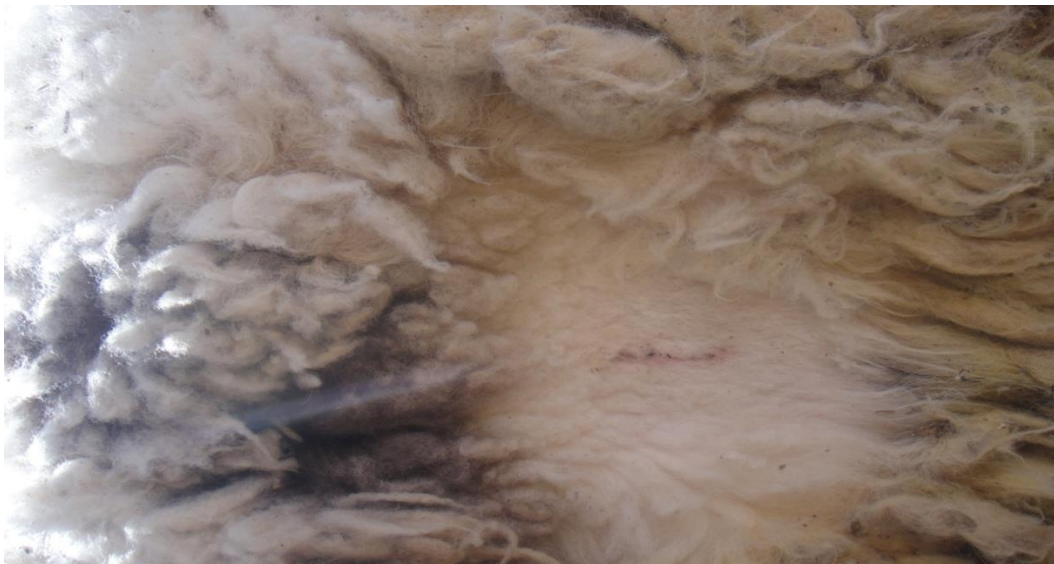

Figure (3):after (10) days, the edges of the wound healing with the beginning of the external connective tissue formation treated with henna.

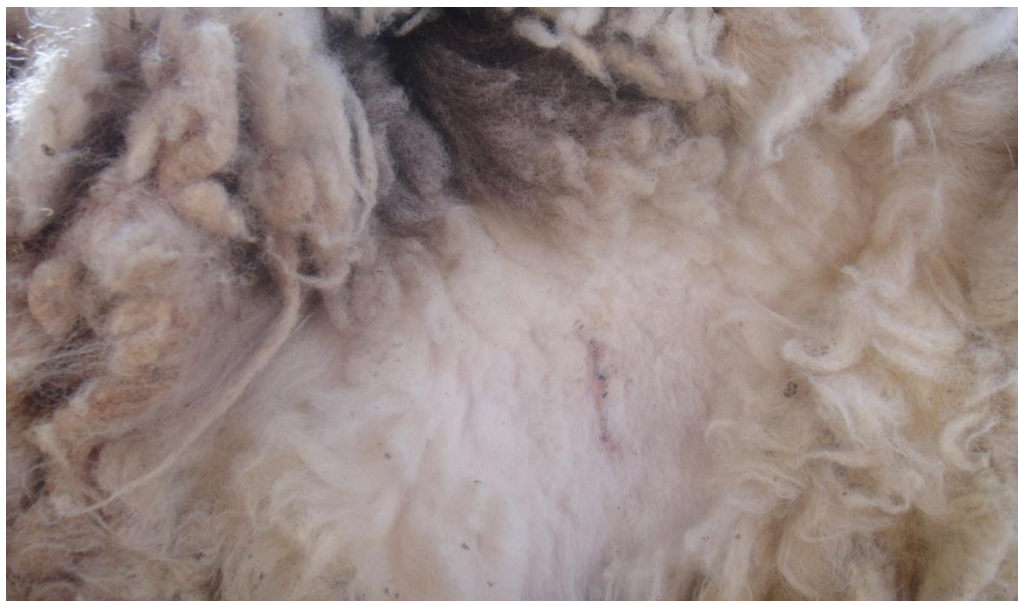

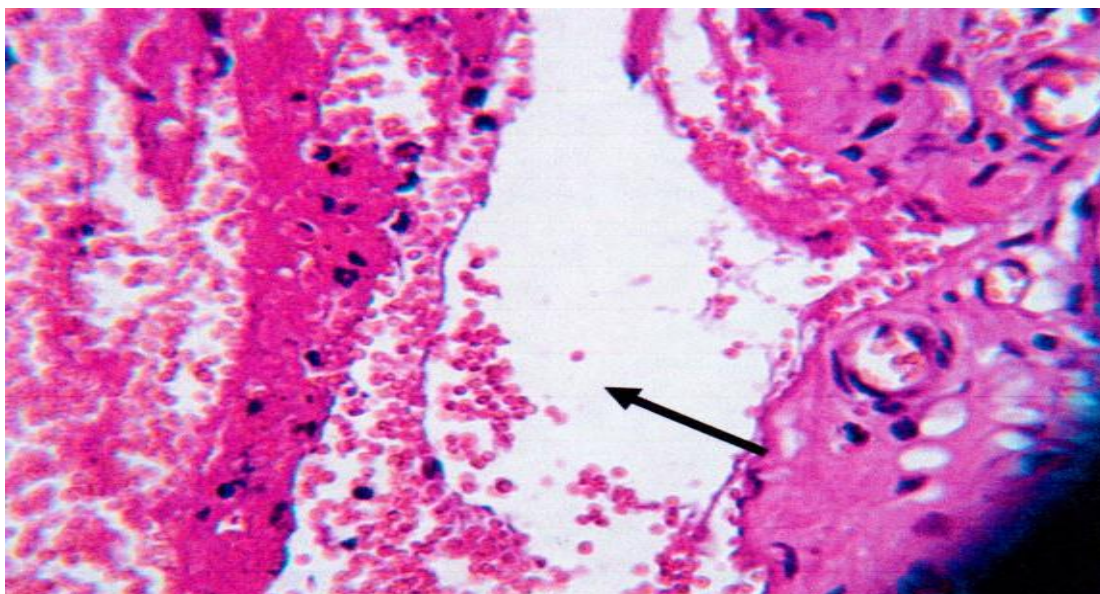
Figure (4): wound after (15 days), wound healing is with scar formation .



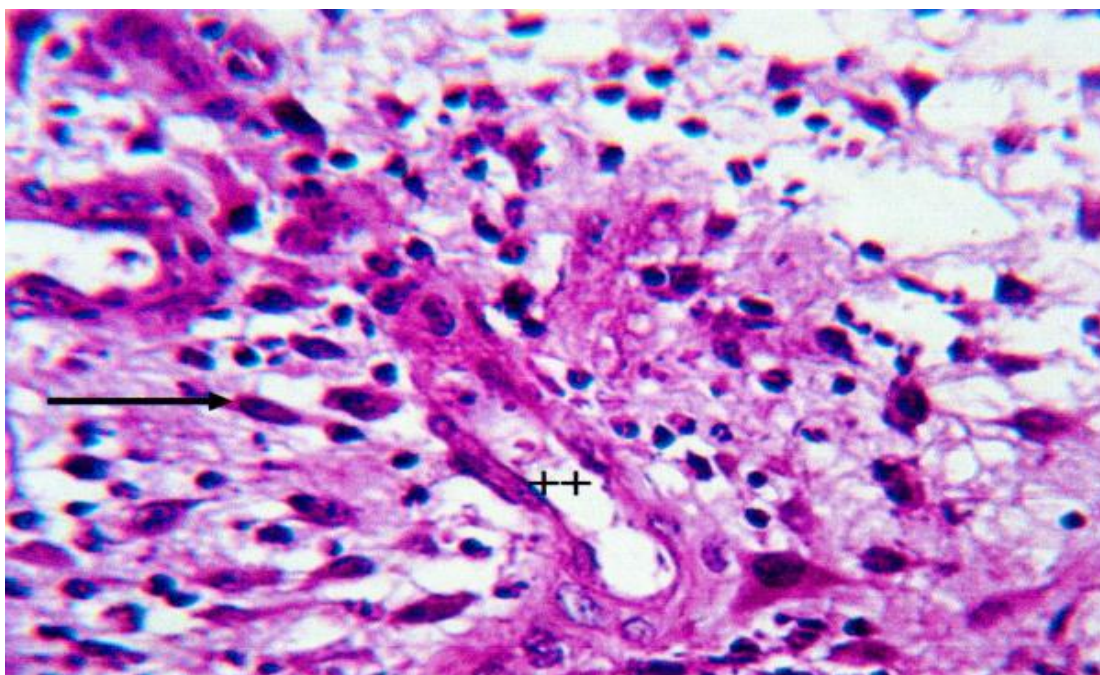
Figure (5): after the wound (20) on a complete healing of the wound using henna be topically with the fibrous connective tissues .

Histological examination:

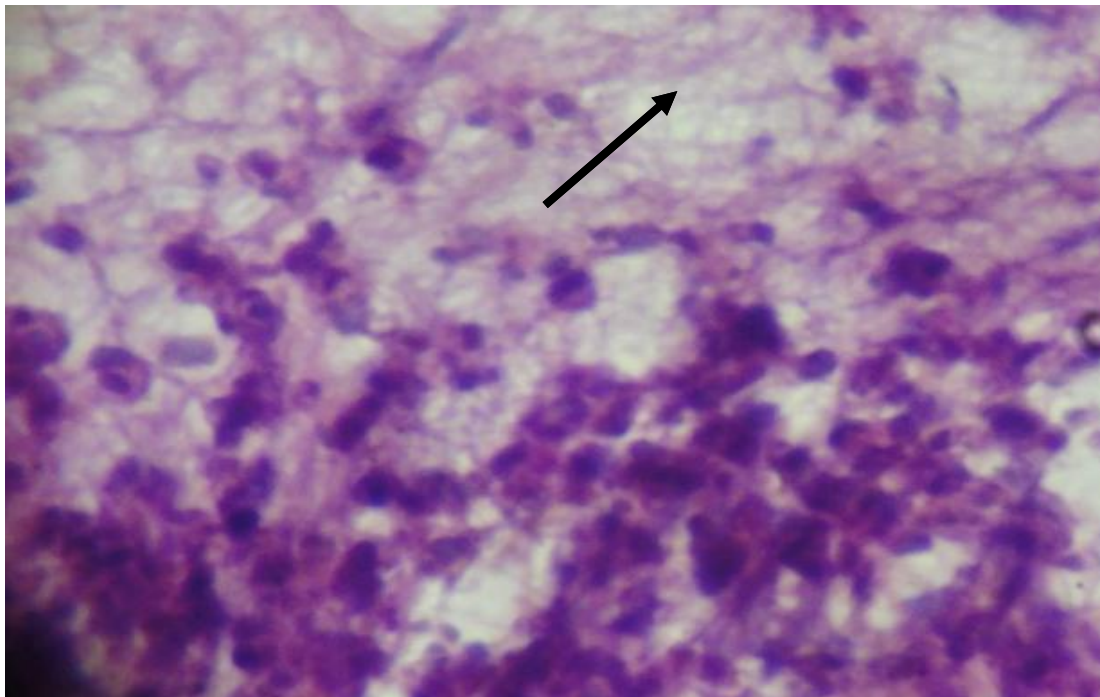
The study showed the following results:



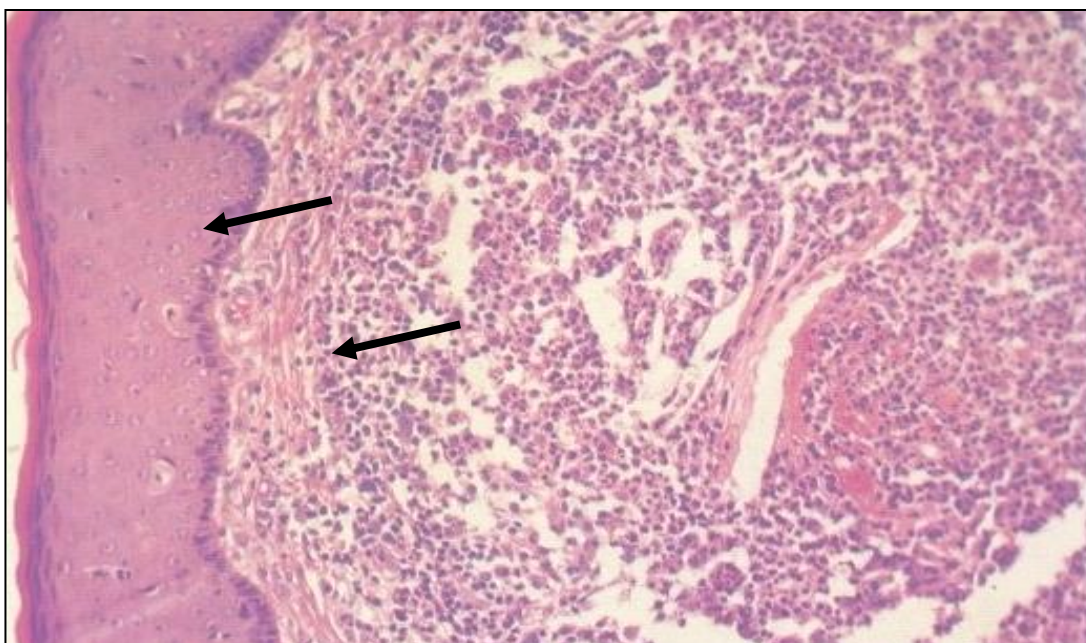
**Figure 6 :** Histopathological section in the skin at 5 days post treated with henna shows mononuclear cells and collagen fiber ( H&E 40X)



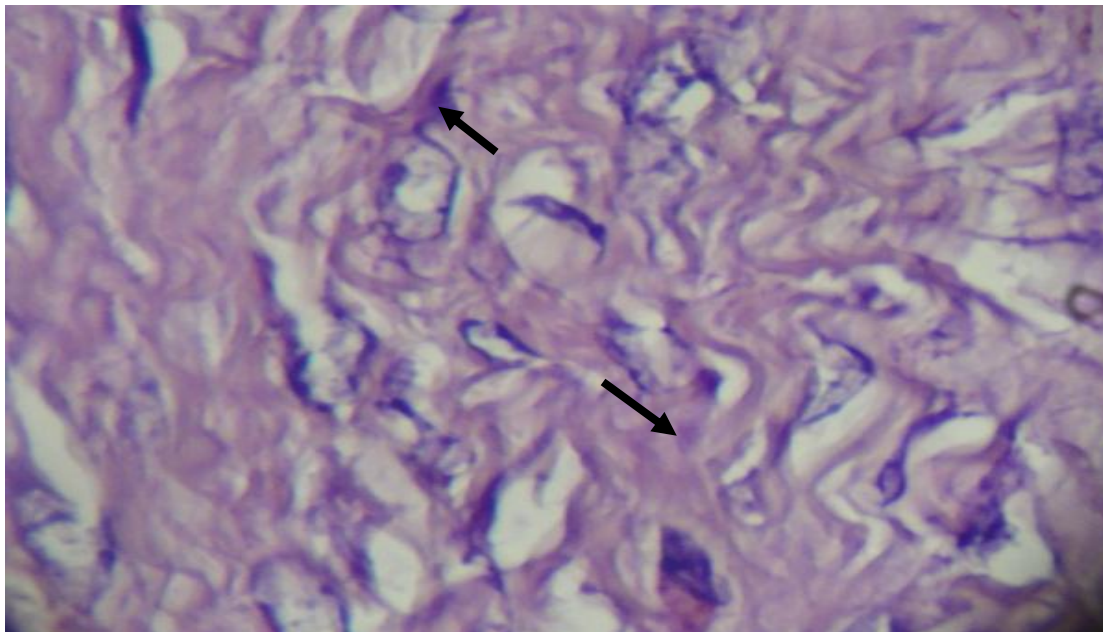
**Figure 7:** Histopathological section in the skin at 10 days post treated with henna shows large amount of granulation tissue formation and newly blood vessels (H&E).



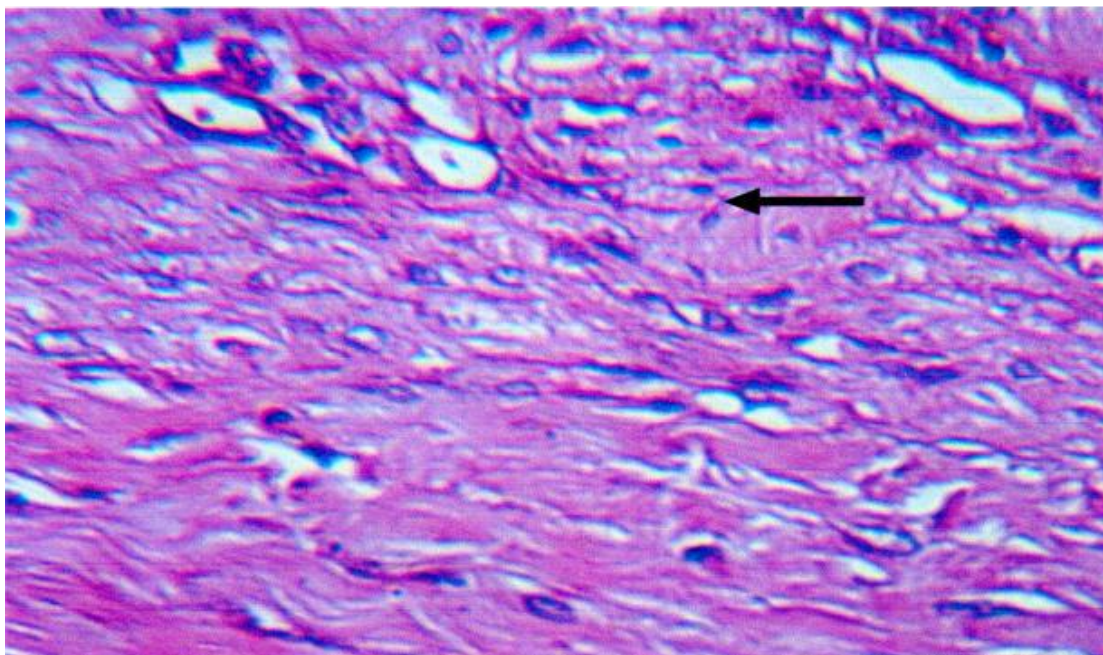
**Figure 8** : Histopathological section in the skin at 15 days post treated with henna shows abundant regular collagen fiber ( H&E 40X)



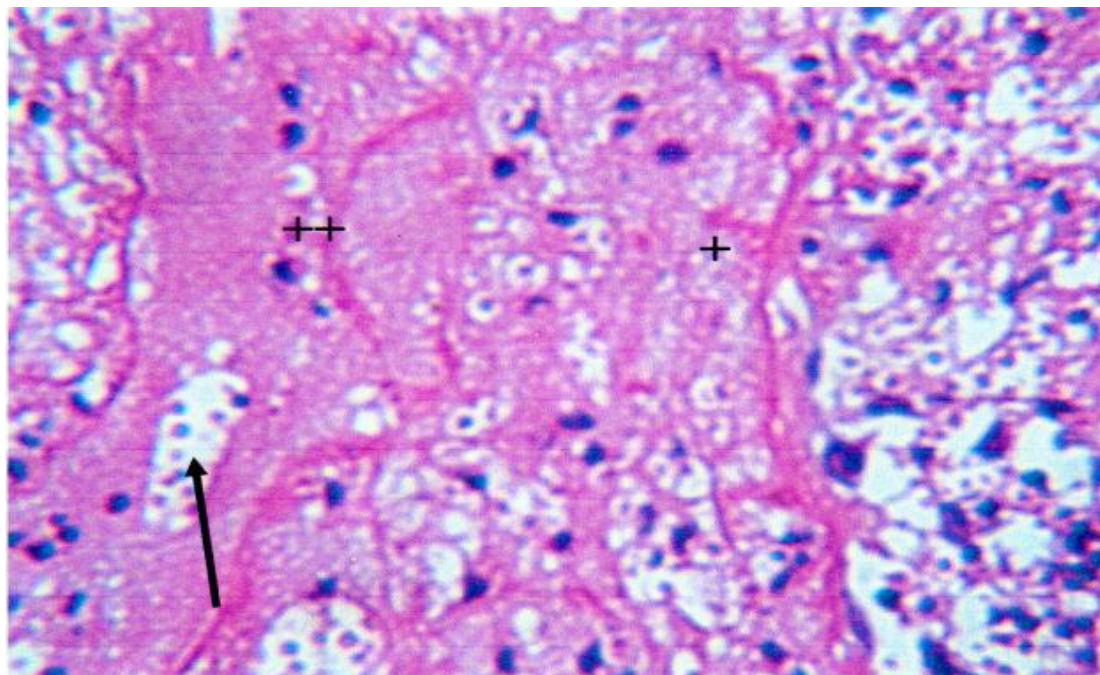
**Figure 9** : Histopathological section in the skin at 20 days post treated with henna shows Formation of fibrous connective tissue with scar formation ( H&E 40X) .



**Figure 10** : Histopathological section in the skin at 5 days in control group shows hemorrhage and inflammatory cells (H&E 40X) .



**Figure 11** : Histopathological section in the skin at 10 days in control group shows inflammatory cells infiltration and congestion of blood vessels (H&E 40X) .



**Figure 12 :** Histopathological section in the skin at 15 days in control group shows aggregation of inflammatory cells and collagen fiber ( H&E 40X) .

**Conclusions :**

Results of the study showed that the use of henna in the treatment of wounds and the prevention of pollution in the incidence of wounds as it helps in speeding up the healing process and also works as an adjunct in henna stop the bleeding and also helped to stop the inflammation .

**Discussion :**

Results of the study showed the use of henna in the treated group compared with the control group , In the treated group that sampled for the purpose of examination of tissue after (5) days, the amount of collagen in the wound more than the control group with the infiltration of inflammatory cells as well as the group sampled after 10 days was the formation of angiogenesis more than the control group after 10 days of this Mediate its results matching with (8), as well as in the group sampled after 15 days showed wound healing with the formation of scar formation more than

the control group, and these results were identical to what was done (9) , as well as the group that samples have been taken after the (20) day observed complete healing of the wound with the formation of connective tissue than in the control group and these results match with what it says (10), came the results match what was done much research in the use of other extracts in wound healing, such as honey, as well as extract Alban oil and this is what came with (14) .

**References :**

1. Singh M, Jindal SK, Kavia ZD, Jangid BL, Khem Chand.(2005). Traditional Methods of Cultivation and Processing of Henna. Henna, 1.Cultivation, Improvement and Trade: 21-14. Jodhpur, India: Central Arid Zone Research Institute .
2. Harborne SB, Baxter A.( 1995). Phytochemical Dictionary. A handbook of bioactive compounds from plants. Tylor and Francis. London

3. Muhammad HS, Muhammad S.(2005). The use of Lawsonia inermis linn. (henna) in the management of burn wound infections. African Journal of Biotechnology; 4:934-937 .
4. Habbal OA, Al-Jabir AA, El-Hag AH, Al-Mahrooqi ZH, Al-Hashmi NA. (2005). In-vitro antimicrobial activity of Lawsonia Inermis linn (henna). A pilot study on the Omani .
5. Kelmanson JE, Jager AK, Staden JV.(2002). Zulu medicinal plants with antibacterial activity. J Ethnopharmacol; 69:241-246.
6. Nayak BS, Isitor G, Davis EM, Pillai GK.( 2007). The evidence based wound healing activity of Lawsonia inermis Linn. *Phototherapy Research.*; 21(9): 827–831.
- 7-Numan, Adeeba Sharif Younes, 1998. Inhibitory effect of some plant extracts on the growth and metabolism of a number of positive and negative bacteria valued dye, Ph.D., Faculty of Science, University of Mosul.
- 8- Sharma Y. , Jeyablan G. , Singh R. and Semwal A. (2013). Current aspect of wound healing agents from medicinal plants: a review. J. of Med. Plants Studies, 1:3 Pp: 1-11 .
- 9-Nithya V. and Anusha Baskar. (2011). A preclinical study on wound healing activity of Lawsonia alba Linn. Research J. of Photochemistry, 5: 123-129.
- 10-Nayak BS, Isitor G, Davis EM, Pillai GK.( 2007). The evidence based wound healing activity of Lawsonia inermis Linn. *Phototherapy Research.*; 21(9): 827–831.
- 11-Kluytmas S.J.,VanBelkum A.,Verbrugh H.(1997).Nasal carriage of Staphylococcus aureus:epidemiology,underlying mechanisms and associated risks.Clin.Microbiol.Rev.:10:505-520.
- 12-Kulkarni SR and Karande VS, Study of the immune-stimulant activity of Naphthoquinone extract of leaves of Lawsonia alba, Indian Drugs, 1998, 35, 42 .
- 13-Dahanukar, S.A .; Kulkarni, RA, and Rag, NN, 2000. Pharmacology of medicinal plants and natural products. Indian. J. Pharmacology. PP.22-26.
- 14-HS Muhammad, S Muhammad. The use of Lawsonia inermis Linn (henna) in the management of burn wound infections. Afar J Biotechnology. 2005; 4: 934-7.
- 15-Ahmadian S, Fakhree MA. Henna (Lawsonia inermis) might be used to prevent mycotic infection. Med Hypotheses. 2009; 73: 629-30.
- 16-Jamadar MG, Bairy KL, And Kulkarni DR, Vehicle assessment for wound healing profiles, Indian Drugs, 1990, 27, 342.
- 17-Bairy KL, and Rao CM, Wound healing profiles of Gingko biloba, J Nat Remed, 2001, 1, 25.