

Effect of Dexamethasone drug on bleomycin -induced pulmonary fibrosis in experimental rats

Mahdi M.Th.1 Maha K. Ibrahim2

¹Ph.D., Department of Basic medical science, College of nursing, Thi-Qar University, Iraq

²Ph.D., Department of Biology, College of science, Basra University, Iraq

Corresponding author: College of Nursing, University of Thi- Qar;

E- Mail address; hayder9015@yahoo.com

Abstract

Pulmonary fibrosis (PF) is an irreversible and largely untreatable human disease encompasses a large group of chronic lung disorders associated with excessive remodeling, scarring, and fibrosis.

The present study investigated the protective effect of dexamethasone administration against bleomycin-induced pulmonary fibrosis in adult male rats. A total of 40 male adult albino rats (*Rattus norvegicus*) weighing from 200-250 gm each, were divided into four groups of (10) animals each. The first group received a daily intraperitoneal (i.p) injection of vehicle normal saline (0.5ml/animal, daily to end experiment), and served as control group. Animals in the second, third and fourth groups were administered i.p. with bleomycin (15mg/kg) 3 times weekly for 3 wks, dexamethasone 1mg/kg body weight (B/wt.) (diluted in 0.5ml saline) as a single dose daily for 3wks and dexamethasone a combination with bleomycin simultaneously to end experiment, respectively. The present study, displayed that the biochemical results determined the levels of Superoxide dismutase (SOD), Glutathion peroxidase (GSHpx) and Hydroxyproline(HYP) content in blood serum of animals. Where after oral administration of dexamethasone in combination with bleomycin, showed that dexamethasone significantly increase SOD $P < 0.001$ and GSHpx $P < 0.001$ levels, and decreased HYP $P < 0.001$ contents in blood stream of the rats in comparison with bleomycin group. On the contrary, study showed after intraperitoneal injection of bleomycin alone, decreased level of SOD, GSHpx and increased of HYP content in blood serum of rats in comparison of control group. On the other hand, microscopical observations clarified that bleomycin injection showed that Most lung sections of BLM treated rats showed extensive damage of the lung tissue with loss of the normal alveolar architecture and majority of the alveolar walls were occupied by collagenous fibers, Results also clarified rupture of interalveolar septa forming large irregular emphysematous air spaces, Furthermore, lung sections of bleomycin – treated rats showed heavily infiltration with mononuclear inflammatory cells mostly lymphocytes, macrophages and moderate degeneration bronchioles epithelium. The study clarified that lung sections from animals treated with both (BLM) and dexamethasone, was restored normal tissue, slight thickening, and space expansion, mild edema of the interstitium and alveolar spaces with clear terminal bronchioles. Nevertheless, still congested of interalveolar septa and scattered inflammatory cells.

This investigation has clearly identified the importance role of dexamethasone as inhibitor factor on pulmonary fibrosis induced by bleomycin, therefore, the findings

may be offer one of therapeutic strategy to prevent the lung fibrosis in experimental rats model.

Keywords: *Dexamethasone, pulmonary fibrosis, Bleomycin.*

Introduction

Fibrosis is the formation of excess fibrous connective tissue in an organ or tissue in a reparative process, which it was opposed to formation of fibrous tissue as a normal constituent in the tissues, while scarring is confluent fibrosis that obliterates the architecture of the underlying organ and tissue (Tomaseket al., 2002; Wynn, 2007).

This model of pulmonary fibrosis resembles that seen in humans and had been used to assess the effect of potential therapeutic agents (Molina et al., 2012). It has been used successfully to treat a variety of malignancies including; squamous cell carcinoma of testis, head, neck, cervix, esophagus germ cell tumors and both Hodgkin, non-Hodgkin lymphoma. The limitation of bleomycin for life threatening interstitial pulmonary fibrosis (also called fibrosing alveolitis) in up to 10 percent of patients receiving the drugs. Specific treatments for fibrotic lung diseases are not yet available, and they are limited to the control of inflammatory events in the lung with the expectation that prevention of inflammation might delay the progression of fibrotic events (Kroegel et al., 2004).

However, Dexamethasone (Dexa.) is one of the glucocorticoids, which influence and regulate functions in the body, which produced many effects and used for many indications. It is transported, metabolizes and excreted in a fashion similar to that of endogenous glucocorticoid as cortisol, but has longer duration of action (Rohdwealdet al., 1987).

Glucocorticoids increase serum glucose levels, stimulate lipolysis and increase protein catabolism. They also have catabolic effects on lymphoid

tissues, connective tissue, muscle and skin (Pearce et al., 1998). Most of the known effects of glucocorticoids are mediated through glucocorticoid receptors.

Dexamethasone, stabilizes lysosomal membrane and prevents the release of proteolytic enzymes released during the inflammatory process, also decrease edema compared to placebo steroid anti-inflammatory drugs, as distinct from non-steroid anti-inflammatory drugs reduced chemotaxis at inflammation areas as glucocorticoid receptor mediated effects. (Kurihara et al., 1984; Laue et al., 1988; Aouadet al., 2001). Like all glucocorticoids, dexamethasone acts on the glucocorticoid receptor is a member of the nuclear receptor super family. Multiple signaling pathways are involved following binding of the steroid to the receptor, including direct DNA binding which results in changes to gene literatures transcription. This result changes in carbohydrate, protein and fat metabolism as well as changes with gluconeogenesis (Diket al., 2003). Also decreased release of bradykinin, (TNF), IL-1, IL-2, IL-6 and decreased production of prostaglandins. There is decreased transmission of impulses in C fibers. Binding of steroid ligands to the glucocorticoid also alters the half-life of mRNA, which have already been produced within the cell. For example, dexamethasone decreases both bradykinin receptor mRNA expression as well as the response to bradykinin binding (Werner et al., 2002; Newton et al., 2002; Lu NZ et al., 1989).

Despite these powerful anti-inflammatory effects, numerous clinical trials with corticoids have produced poor results. Justifications

for these power results might be an incomplete understanding of the dose and duration of therapy (Cranshaw and Evans, 2002; Katzung, 2006; Lippincotts, 2008). Nonetheless, it has been reported in one study that corticoids can alleviate fibrosis and facilitate recovery of ARDs when administrated in the fibrotic phase of the disease course (Chang et al., 2003; Grunzeet al., 1988). Therefore, the main objective of this study was investigated to clarified the effect of dexamethasone on the induction of pulmonary fibrosis in rats.

Material and methods

Experimental Animals

Male wister albino Wister rats (*Rattus norvegicus*) weighing 200-250 gm were obtained from animal center of Thi-Qar university \college of science. All animal were allowed to take food and received tap water *ad libitum*, temperature (22±3) with an alternating cycle of 12-h light and dark.

Experimental design

Animals were equally distributed into four groups (10 rats) in each experiment; Group1; Control group, the animals received sterile saline solution 0.5ml \animal \daily i.p to end experiment. Group2; Induction group, the animals received bleomycin 15mg/kg \i.p. three times weekly for 3wks. Group3; Animals received dexamethasone at adose 1mg/kg \i.p. daily for end experiment. Group4; Animals received bleomycin and dexamethasone together simultaneously at doses, periods and administration similar to groups 2 and 3 so that mentioned above.

The dose level and schedule were based on previous studies (Diket al., 2003; Claudineetal. 2009). The animals were starved over night for 12hrs. Before blood was collected, rats were anaesthetized with chloroform and

venous blood samples were collected by direct heart puncture into sterilized tubes (without anticoagulant to separate the sera and then keeping in freezer to determinate some biochemical parameters like SOD, GSHpx and HYP, and (with anticoagulant) to procedure rapid hematological examination.

Estimation of GSHpx, SOD and HYP

The serum glutathione peroxidase (GSHpx), superoxide dismutase (SOD) and hydroxyproline (HYP) were measured on the basis of the instruction of kit for each, that is, Cusabio Eliza kit, catalo no. CSB-E 121144r. Briefly use a human serum tube or a serum separator tube (SST) and allow samples to clot for 30 minutes before centrifugation for 15 minutes at 3000 rpm remove serum and assay immediately or aliquot and store samples at -20 °C until required samples were read to absorbance at 450 nm.

Histopathological examination

Lung tissue samples were obtained from sagittal slices of the lungs, were fixed in 10% formalin for 24 and then washed –dehydrated–cleared and embedded in paraffin, sections about 4µm thickness was cutting stained with hematoxylin -Eosin for microscopic examination. The histological changes were evaluated by observe of lesions microscopically.

Statistical analysis

All values were expressed as mean ±SD with 95% confidence intervals (CI) of experiment statistical analysis of variance (ANOVA) followed when differences were significant. Differences between groups were testing using the paired students T-test. Differences were considered statistically significant at P<0.05 (Sabine, 2004)..

Results

Results of current study showed, effect of bleomycin injection on Hydroxyproline content in blood serum were significantly increase in rats with lung fibrosis compared to control group $P < 0.0001$. This rise were markedly inhibited by administrate of dexamethasone in combination with bleomycin $p < 0.0001$ (table 1) in compared to bleomycin group. Effect of dexamethasone on antioxidant enzymes include SOD and GSHpx in blood serum of rats with pulmonary fibrosis, appeared a depletion of SOD activities in the blood serum of Bleomycin group, where SOD activity

was significant decrease compared with the control group at $P < 0.008$, that depletion of SOD activity, after administrate of dexamethasone with bleomycin significantly prevented the depletion of SOD activity $P < 0.05$ (table 1). Furthermore, bleomycin treatment produced a significant decrease in blood serum GSHpx level at $P < 0.0001$, in rats with pulmonary fibrosis, but use dexamethasone with bleomycin caused significant attenuated of the bleomycin-induced pulmonary fibrosis in the GSHpx level $P < 0.02$ (table 1).

Table 1:- Effect of dexamethasone on antioxidant enzymes; superoxide (SOD), glutathione peroxidase (GSHpx) and hydroxyproline (HYP) in blood serum of rats with pulmonary fibrosis (mean±S.D).

Groups	SOD Pg/ml	GSHpx mIu/ml	HYP µg/ml
Control	9.42±1.08	33.180±3.444	1.44±0.204
Bleomycin	7.77±0.644a	17.040±1.527	2.86±0.125a
Dexamethasone	9.100±1.199	29.625±2.125	1.236±0.050
BLM+Dexa.	8.934±0.799b	27.066±2.748b	1.355±0.099b

Hyp; $ap < 0.0001$ vs. control group, $bp < 0.0001$ vs. blm group.

SOD; $ap < 0.008$ vs. control group, $ap < 0.05$ vs. blm group.

GSHpx; $ap < 0.001$ vs. control group, $bp < 0.02$ vs. blm group.

Results of microscopic observations on rat's lung related to control group showed normal architecture, spongy appearance of the lung with thin alveolar septa, clear alveolar cavities and normal alveolar ducts. The interalveolar septa were formed from the epithelial tissue lining of the alveoli and loose connective tissue contained extensive capillary network around the alveoli. The alveolar sacs occurred at the termination of the alveolar ducts (Figure 1).

Histological examination on lung sections related to rats treated with

each drugs dexamethasone, showed no pathological changes and the observation similar to that of control group. Most lung sections of BLM treated rats showed extensive damage of the lung tissue with loss of the normal alveolar architecture and majority of the alveolar walls were occupied by collagenous fibers with showed diffuse cellular infiltration (figures 2), as well as clarified bands of collagen fibers, increased with macrophages and fibroblast cells (figure 3). Moreover, the study clarified that lung sections

from animals treated with both (BLM) and dexamethasone, was restored normal tissue, slight thickening, and space expansion, mild edema of the interstitium and alveolar spaces with

clear terminal bronchioles, which may had minimum drained lesions. Nevertheless, still congested of interalveolar septa and scattered inflammatory cells (figure 4).

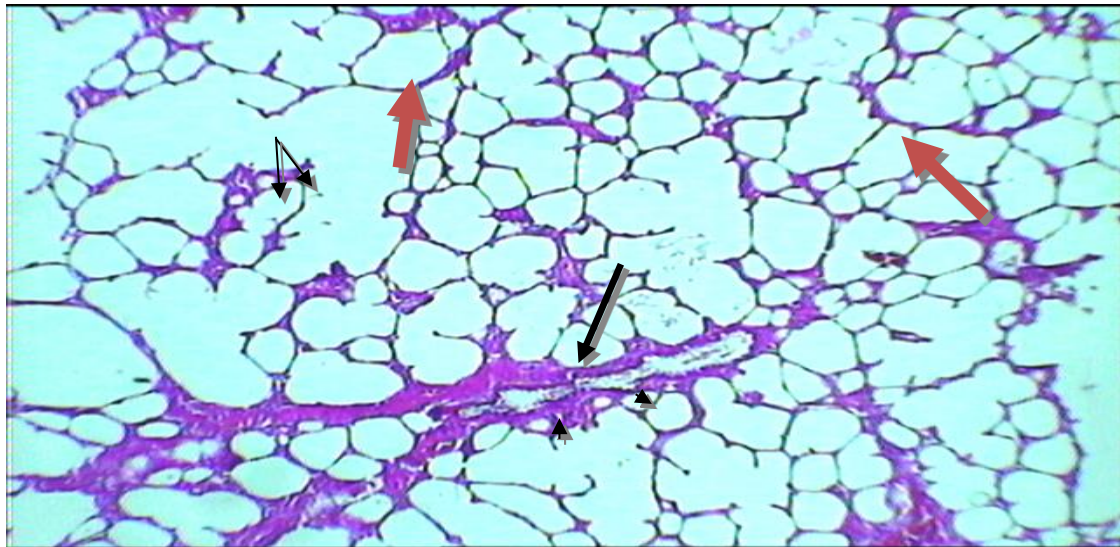


Figure 1: Section in the lung of a control rats showing normal structure of alveoli(a), thin alveolar septa (—→), and loose connective tissue containing capillary network around the alveoli, normal alveolar ducts (AD), branches of terminal bronchioles ()Pulmonary Veins alsnoticed (V) (H&E.100X).

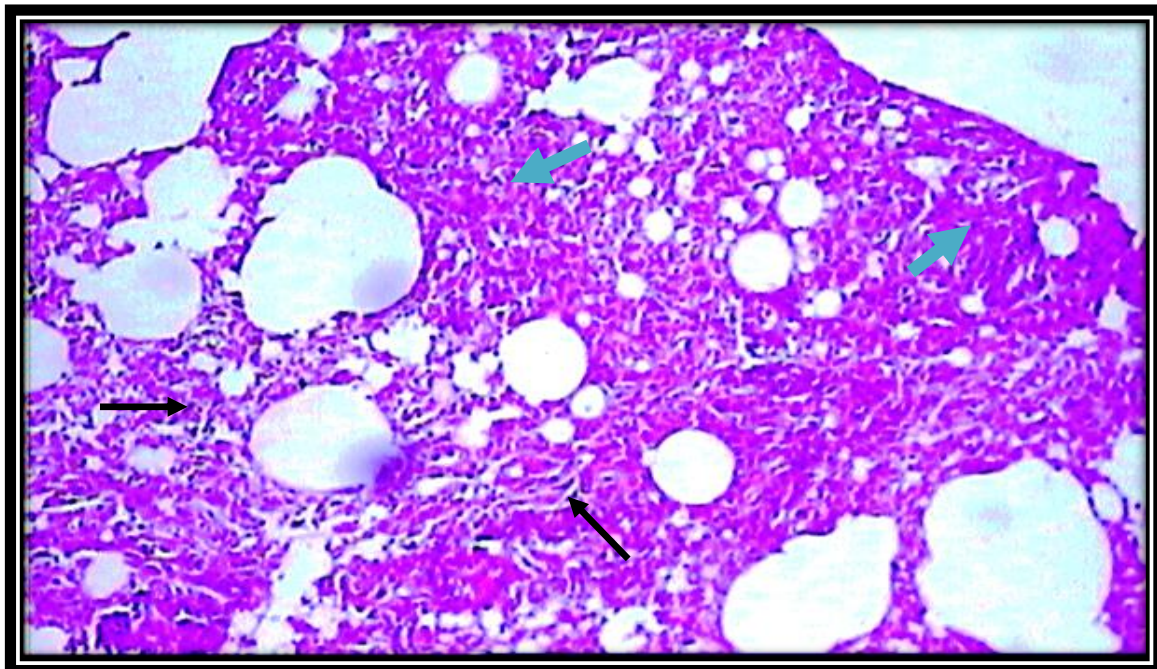


Figure 2: Section in lung of (BLM) bleomycin group with higher magnification showed diffuse cellular infiltration(H&E.200X).

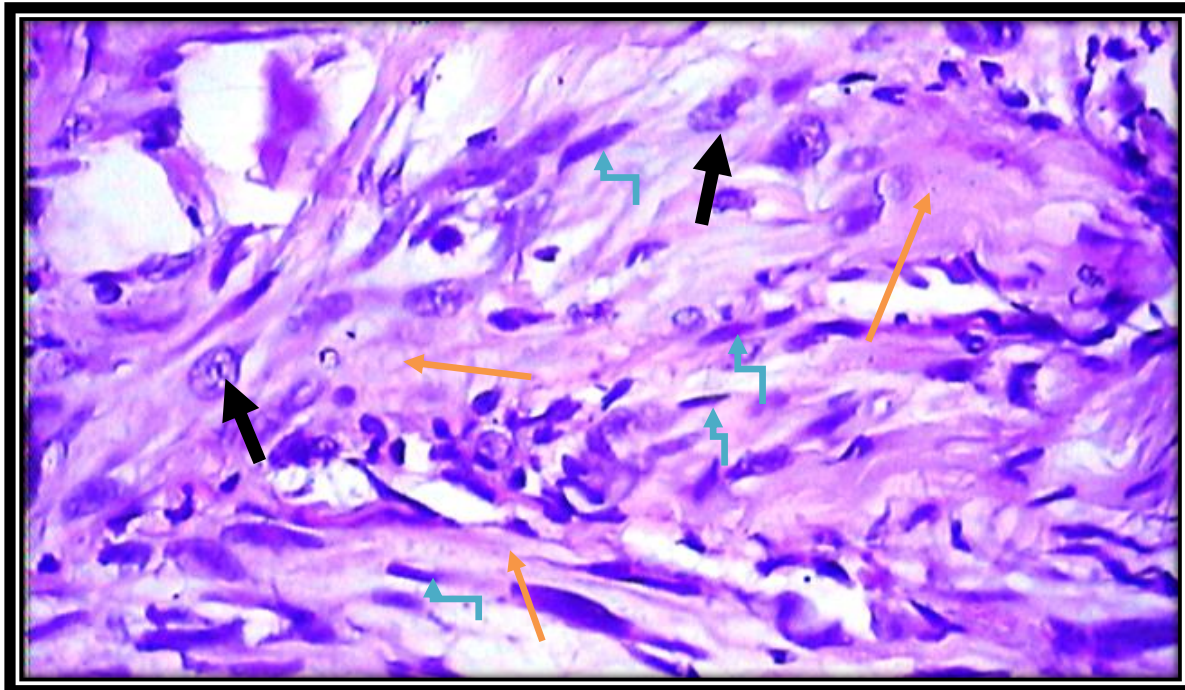


Figure3:Section in lung of rat treated with bleomycin, previous photomicrograph, clarified bands of collagen fibers (→), increased with macrophages (←) and fibroblast cells (→)(H&E.400X).

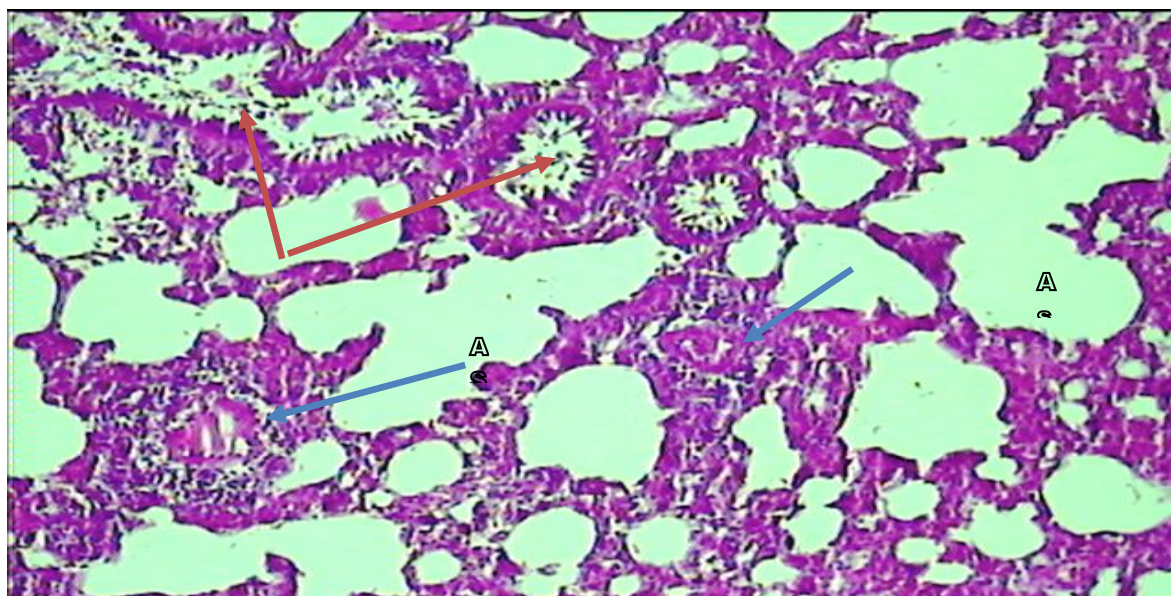


Figure 4: Section in the lung of rat treated with (bleomycin + dexamethasone) showed that most of the lung tissue was restored, and there was slight edema of the interstitium and dilated alveolar sac (A), appearance exudates areas of inflammatory cells and fibrin (→), the terminal bronchiole had minimum drained lesions (H&E. 100X).

Discussion

Pulmonary fibrosis (PF) described a group of diseases, which caused interstitial lung damage, ultimately fibrosis, and loss of the lung elasticity. Where Fibrotic lung diseases are heterogeneous groups of chronic lung disorders that may be produced by a variety of toxic agents; infections, immunomediated disorders or might be idiopathic, frequently progressive with marked tissue destruction ending by respiratory failure (Firemen et al., 1994; Alessandro et al., 2010). However, in this study albino rats (*Rattus norvegicus*) were utilized to study the effect of bleomycin administration on the lung and the probable protective role of dexamethasone. The use of rat species as model in the present study was justified by (Usuki and Fukua, 1995) who reported that administration of bleomycin to rodents produce histological alterations nearly similar to those found in human pulmonary fibrosis, where the pattern seen in the alveoli of humans with severe lung fibrosis similar to that found in rats given bleomycin.

In this experiment, we examined the effect of dexamethasone on pulmonary fibrosis induced by intraperitoneal injection with bleomycin (15mg/kg). However, the parameters taken in this study included antioxidant enzymes such as (SOD, GSHpx) and hydroxyl-proline concentration. The selection of these parameters based on many previous studies. Several studies suggest that oxidant-antioxidant imbalances in the lower respiratory

tract play a critical role in the pathogenesis of PF. For instance, pulmonary inflammatory cells of patients with PF generate higher levels of oxidants than those in control patients. Broncho alveolar lavage fluid of patients with IPF show elevated levels of myeloperoxidase and eosinophil cationic protein, suggesting a pathophysiologic role of the oxidants, neutrophils and possibly eosinophils in this disease. Mitochondrial generation of ROS has been suggested to be associated not only with increased cellular oxidative stress but also with apoptosis of alveolar epithelial cells. Broncho alveolar lavage fluid of patients with PF contains higher levels of 8-isoprostane, a biomarker of oxidative stress, than that of control subjects. These findings suggest that patients with PF have increases in oxidative stress (Lakariet al., 2002; Kharitonov and Barnes, 2001; Kuwano et al., 2003). Furthermore, fibrosis in rat lungs induced significant harmful changes in antioxidant status. Where the results showed significant decrease in SOD and GSH-Px activity in the serum of animals treated with bleomycin. These findings were also recorded by many workers (Rahman and MacNee, 2000; Fattman et al., 2003; Narayanan et al., 2009) who also concluded that the balance between oxidants and antioxidants was one of the important conditions to maintain the lung normal homeostasis and protect the lung from many pathological conditions and promote normal repair. Hasegawa et al. 1992

reported that the decrease in GSHPx and SOD is potentially ascribable to inactivation by the increase in ROS or lipid peroxidation when oxidative damage is extreme.

Meanwhile, serum blood levels of hydroxyproline was significantly higher in the bleomycin group than in others healthy groups (controls). The same observations were recorded by (Durairaj et al., 2008; Fattman et al., 2003).

Moreover, the results showed that dexamethasone in combination with bleomycin was significantly ($P < 0.0001$) increased GSHpx and SOD activities, which showed significant decline in bleomycin group. Similar to previous studies, dexamethasone significantly attenuated the BLM-induced decrease of SOD and GSHpx levels in blood serum, together; these data propose that the preventive effect of dexamethasone from BLM-induced lung fibrosis may be due to its free radical scavenging, reduction of lipid peroxidation and increases antioxidant enzymes (Diket al., 2003). Also significantly decreased ($P < 0.0001$) Hydroxyproline concentration which elevated in the bleomycin group. Our justification may be return to the role of dexamethasone in inhibited or at least delayed pulmonary fibrosis induced by BLM treatment via inhibition collagen synthesis in wound tissues to prevent stricture formation, this finding is in accordance with (Mahmutet al., 2003). Histological results referred that administration of bleomycin increase collagen deposition and histological changes in lung tissue with high degree of fibrosis; this was in agreement with findings reported previously (El-medany et al, 2005; Gli et al, 2008). In other word, bleomycin was increased hydroxyproline level in blood serum in rats with pulmonary fibrosis

,administration of dexamethasone resulted in significant reduction in the marked Hyp concentration and reduced the increase in lung coefficient without reaching those of control animals. In the current study, antioxidant enzymes were decreased in bleomycin treated rats while treatment with dexamethasone induced a significant increase in antioxidant enzymes compared to bleomycin group. In agreement, HYP and antioxidant enzymes (SOD, GSHpx) expression were up regulated in fibrotic lung (Diket al., 2003). Anyhow, there is conspicuous variation in both biochemical and histopathological changes related to (PF) and the degree of changes in lungs of rats treated with another drugs as in combination therapies has been described.

Previous studies have shown that prolonged administration of corticosteroid (dexamethasone) initiated before or simultaneously as bleomycin administration, inhibited the development of lung fibrosis in rats (Grunze et al., 1988). In the current study, the use of dexamethasone largely protected the pulmonary tissue from the injurious effect by BLM. It was observed that lungs of rats received dexamethasone concomitantly with BLM revealed minimal damage in most specimens with preservation of normal alveolar pattern. Alveolar cell injury, inflammatory cells infiltration, areas of consolidation, collapse and fibrosis were much less encountered than in rats treated with BLM alone. Besides, minimal thickening walls of the interalveolar septa, bronchiolar and blood vessels. In the available literature, there is a general agreement that dexamethasone suppress BLM-induced lung damage (Diket al., 2003; Chen et al., 2006; Serrano et al., 2003; El-drieny, et al. 2009). Nonetheless, previous workers Leibovich and Ross,

(1975) had previously stated that dexamethasone reduced inflammation, including inflammatory cell migration and proliferation, in addition it directly inhibited lung fibrosis by direct suppression of fibroblasts and decrease transcription of type1 procollagen mRNA in the fibroblast, thus suppressing collagen synthesis.

Conclusion

Communique, from this study propose that protection effect of dexamethasone against bleomycin –induced lung injury could be due to its antioxidant activity , as well as ,data suggested that the potential for corticosteroid (dexamethasone) as a therapeutic strategy in patient with pulmonary fibrosis may be advantageous. Consequently, the present study results that the dexamethasone improving effect of pulmonary fibrosis induced by bleomycin in rats, and Use of dexamethasone, in combination with bleomycin significantly change the biochemical parameters and minimize the histological lesions induced by bleomycin.

References

1. Tomasek, JJ.; Gabbium,' G.; Hinz, B.; Chaponmer, C. and Brown, RA. 2002. myofiboblasts of mechano-regulations of comrefive tension remodeling. Nat Rev. Mal. Cell Biol. 3 (5): 349 – 363
2. Wynn, TA. 2007. Common of unique mechanizes regulate fibrosis in various fibro proliferative diseases. J. clin. Merest. 117 (3). 524-529.
3. Molina Molina M ,A Serrano-mollar, O Bulbena , L. Fernandez- zabelegui,D closo , A marin-Arguedas ,A Toorego , C picaado, and yanbet ; (2012); Losartan attenuates blm-induced lung fibrosis by

increase PGE2 synthesis .Thorax ;bl; 61;604-610.

4. Kroegel C., Mock B., Hengst , and Reissing A : (2004);In terfero gamma-Ib;Theraputic option in advance IPF ? Respiration , 71;656-657.
5. Rohdweald, P.; Mollmann, H.; Barth, J.; Rehder, J. and Derendorf, H. 1987. Pharmacokinetics of Dexamethsone and Its Phosphate ester. Biopharm Drng Dispos. 8 (3): 205-212.
6. Pearce, G.; Tabensky, D.A.; Delmas, P.D.; Baker, H.w. and secman, E.G. 1998. corticosteroid induced bone loss in men. J. clin. Endocrinol. 1Metab. 83 (3): 801-806.
7. Kurihara, A.; Ohuchi, K. and Tsurufuji, S. 1984. Reduction by dexamethasone of chemotactic activity in inflammatory exudates. European Journal of Pharmacology. 101 (1-2): 11-16.
8. Laue, L.; Kawai, S.; Brandon, DD.; Brightwell, D.; Barnes, K.; Knazek, RA.; Loriaux, DL. And Chrousos, GP. 1988. Receptor-mediated effects of glucocorticoids on inflammation: enhancement of the inflammatory response with a glucocorticoid antagonist Journal of Steroid Biochemistry. 29 (6): 591-598.
9. Aouad, MT.; Siddik, SS. Rizk, L.B.; Zaytoun, G.M. and Baraka AS. 2001. The effect of dexamethasone on Postoperative vomiting after tonsillectomy. Anesthesia & Analgesia. 92 (3): 636-640.
10. Dik, W.A.; Mc Anulty, R. J.; versnel, M.A.; Nober, B.A.; Zimmermann. L.J.; Laurent,

- G.J. and Mutasers, S.E. 2003. Short course dexamethasone some treatment following injury inhibits bleomycin induced fibrosis in rats. *Thorax*. 58 (9): 765-771.
11. Werner, MU.; Lassen, B. and Kehlet, H. 2002. Analgesic effects of dexamethasone in burn injury. *Regional Anesthesia & Pain Medicine*. 27 (3): 254-60.
 12. Newton, R.; Eddleston, J.; Haddad, el-B.; Hawisa, S.; Mak, J.; Lim, S.; Fox, AJ.; Donnelly, LE. and Chung, KF. 2002. Regulation of kinin receptors in airway epithelial cells by inflammatory cytokines and dexamethasone. *European Journal of Pharmacology*. 441 (3): 193-202.
 13. Lu, NZ.; Wardell, SE.; Burnstein, KL.; Defrance, D.; Fuller, PJ.; Giguere, V.; Hochberg, RB.; McKay, L.; Renoir, JM.; Weigel, NL. and Wilson, EM. 1989. Lung is related to impaired lung function. *Am. Rev. Respir. Dis*. 139:373-377.
 14. Cranshaw, J. and Evans, T.W. 2002. Prospects for pharmacotherapy in acute respiratory distress syndrome. *Eur. Respir. Monograph*. 7: 247-265.
 15. Katzung, BG. 2006. Basic and clinical pharmacology. 11th ed. Mac Graw-Hill.
 16. Lippincotts illustrated reviews pharmacology, 4th ed. Lippincotts Williams and Wilkins, 2008.
 17. Chang, Y.; wong, R.S.; Soo, Y.o.; chui, C.H.; Lauf, Y.; Chan, N.P.; Wong, W.S. and Cheng, G. 2003. Initial treatment of immune thrombocytopenia purpura with high- dose dexamethazone. *N. Engl. J. med*. 349 (9): L 831-836.
 18. Grunze, MF.; Parkinsan, D. and sulauik, RB. 1988. Effect of cortices terodron lung volum-Pressure curves in bleomycin-induced lung injury in the rat. *Exp. lung Res*. 14:183-95.
 19. Sabine Landau and Brian S.,Everitt (Edit). *A Handbook of statistical Analyses using Spss*, Chapman and Hall\CRC, Washington.,2004
 20. Dik, W.A.; Mc Anulty, R. J.; versnel, M.A.; Nober, B.A.; Zimmermann. L.J.; Laurent, G.J. and Mutasers, S.E. 2003. Short course dexamethasone some treatment following injury inhibits bleomycin induced fibrosis in rats. *Thorax*. 58 (9): 765-771
 21. Claudine, S.; Pablo, P.L.; Pierre, H. and pascal, V. 2009. Effect of Timing of Dexamethrsone Treatment on the outcome of collagenase-Induced intracerebral Hematomas in rats. 59 (5): 444-448.
 22. Fireman, E.; Schwartz, Y.; Mann, A. and Greif, J. 1994. Effect of Montil cast a cystieny/ receptor antagonist. On my fibroblast in interstitial lung disease. *J. clin. Immunol*. 24 (4), 418-25.
 23. Alessandro P., Ronen S., Chrishan S., Samuel, Ross A., Bathgate D., Arie Zauberman, Chen H., Assaf w., Dawiclr B., and Calit R. 2010; Prevention of Bleomycion induced pulmonary fibrosis by a Novel antibiotics peptide with Relaxin- like Activity. *Am*

- society for pharm. Of excremental. Published as DOI:10.1124/jpet.110.170977.
24. Usuki, J. and Fukuda, Y. 1995. Evolution of three patterns of intra-alveolar fibrosis produced by bleomycin in rats *Pathol Int.* Aug 45(8):552-64
 25. Lakari, E.; Soini, Y.; Saily, M.; Koistinen, P.; Paakko, P. and Kinnula, VL. 2002. Inducible nitric oxide synthase, but not xanthine oxidase, is highly expressed in interstitial pneumonias and granulomatous diseases of human lung. *Am. J. Clin. Pathol.* 117:132-142?
 26. Kharitonov, SA. And Barnes, PJ. 2001. Exhaled markers of pulmonary disease. *Am. J. Respir. Crit. Care Med.* 163:1693-1722.
 27. Kuwano, K.; Nakashima, N.; Inoshima, I.; Hagimoto, N.; Fujita, M.; Yoshimi, M.; Maeyama, T.; Hamada, N.; Watanabe, K. and Hara, N. 2003. Oxidative stress in lung epithelial cells from patients with idiopathic interstitial pneumonias. *Eur. Respir. J.* 21:232-240.
 28. Rahman, I. and Mac Nee, w. 2000. Oxidative stress and regulation of glutathione in lung inflammation. *Eur. Respir. J.* 16(3):534-554.
 29. Fattman, CL.; Schaefer, LM. And Oury, TD. 2003. Extracellular superoxide dismutase in biology and medicine. *Free Radic. Biol. Med.* 35:236-256.
 30. Narayanan, S.; Srinivasan, K. and Ganapasam, S. 2009. Epigallocatechin-3-gallate exhibits anti-fibrotic effect by attenuating bleomycin-induced glycoconjugates, lysosomal hydrolases and ultrastructural changes in rat model pulmonary fibrosis. *Chemico-Biological Interactions.* 180:271–280.
 31. Hasegawa T, Kaneko F, Niwa Y. 1992; Changes in lipid peroxide levels and activity of reactive oxygen scavenging enzymes in skin, serum and liver following UVB irradiation in mice. *Life Sciences.* 50: 1893-1903.
 32. Durairaj, P.; Narayanan, V. And Mary, B. 2008. Protective effects of curcumin against amiodarone-induced pulmonary fibrosis in rats during experimental pulmonary fibrosis, *Biol. Pharm. Bull.* 31:1306–1311
 33. Mahmut Durmus, Erol Karaaslan, Erdogan Ozturk, Mukaddes Gulee, Mustafa Iraz, Naci Edali and ozcan Ersoy. 2003. The effect of single – dose dexamethasone on Wound Healing in rats. *Anesthesia and Analgesia.* 97(5):1377-1380.
 34. A El-medany ,H .Hagara ,M. Moursib,R.At mohammed F. , El-Rakhawys and G-El-mednay ;attenuation of blm – induced lung fibrosis in rats by mesna ,*EUR J pharmacol*,2005509(1);61-70
 35. . Gli,S.,Pi,z.,Xu., C.Liu ,X.,Wang B.,Liao and y.yin; (2008);signal transducer and activator of transcription 6expression in blm – induced lung fibrosis in rats .*J chin clin med* , 3(9);481-487
 36. Chen, Y., Shi-wen, X., Eastwood, M., Black, C.M., Denton, C.P., Leask, A, Abraham D.J. (2006). ALK5 (TGFβ receptor type I)

- signaling contributes to the fibrotic phenotype of scleroderma fibroblasts. *Arthritis Rheum.*, 54:1309-1316.
37. Serrano, MA.; Closa, D.; Prats, N.; Blesa, S.; Martine Zeosa, M.; Cortijo, J. Estrela, JM.; Morcillo, EJ. and Bulbena, O. 2003. In vivo antioxidant treatment protects against bleomycin – induced lung damage in rats. *BR. J. pharmacol.* 138(6):1037-1048.
38. El-drieny, E A. Shalaby, MN. Amany, M.M. and Abdel-Hamid, AM. 2009. The Possible Protective Effect of Corticosteroids on bleomycin Induced Pulmonary Toxicity. Light and Electron Microscopic Study. *Egypt. J. Histol.* Vol. 32, No. 2, Dec. 2009: 296 - 305
39. Leibovich, SJ. And Ross, R. 1975. The role of the macrophages in wound repair: a study with hydrocortisone and antimacrophage serum. *Am. J. pathol.* 78:71-100. Medline. Cited by muhmut et al., anesthesia and analgesic. 2003; vol 97 no.5:1377-1380.