

Anatomical and Histological study of the Tongue of wild adult male Rabbits (*Oryctolagus cuniculus f. domestica*) in AL-Najaf province

Aqeel Mohsin Mahdi AL-Mahmodi

Veterinary Anatomy and Histology Department Veterinary Medicine College AL-Kufa University

aqeelm.mahdi@uokufa.edu.iq

Abstract

Macro and Microscopical explorations of the tongue in the ten of the adult male Rabbits collected from AL-Najaf city markets, this work expect will provide a support for future research and subsequent clinical applications as regards the biology of the tongue. After rabbits preparation the tongue distinguished then the shape, position, dimensions were record. The apex of the tongue was almost rounded. The body was square-shape thickening decreased gradually toward root. Root which slopes ventrocaudally toward the base of the epiglottis. Torus linguae at the caudal part of the dorsal surface. Lateral surface of tongue contain several fossa touching the premolar teeth. The mean length of the total tongue, apex, body, and root were (4.5 ± 0.5 cm), (1.25 ± 0.23 cm), (2.95 ± 0.2 cm), and (0.9 ± 0.26 cm) respectively. The mean width of the apex, body, and root at the widest part were (1 ± 0.49 cm), (1 ± 0.17 cm), and (1.26 ± 0.22 cm) respectively. Skeletal muscle fibers and loose connective tissue surrounded by stratified squamous epithelium keratinized at the dorsal and lateral lingual surfaces, non-keratinized at the ventral lingual surface. Filiform papillae heavy distribution on the dorsal surface of body, scanty at the apex, at the lateral surface of the body they are smaller than body papillae and longer than apex papillae. Circumvallate papillae were oval-shape, surrounded by a moat-like furrow, taste buds on the dorsal and lateral sides. Foliate papillae were leaf-like non-keratinized; with taste buds on the lateral walls. Fungiform papillae had broad rounded keratinized surface, with taste buds on the dorsal surface. Lamina propria - submucosa was loose connective tissue with rich bundles of collagen fibers.

Key words Filiform, Circumvallate, Fungiform, Foliate
دراسة تشريحية ونسجية للسان ذكور الأرانب البالغة البرية (*Oryctolagus cuniculus f. domestica*)

عقيل محسن مهدي المحمودي
فرع التشريح والأنسجة كلية الطب البيطري جامعة الكوفة

الخلاصة

ألفحص العيني و المجهرى للسان عشرة من ذكور الأرانب البالغة التي جمعت من أسواق مدينة النجف. هذا العمل سيقدم دعم للبحث المستقبلي والتطبيقات السريرية اللاحقة بالنسبة إلى علم أحياء اللسان. بعد تحضير الأرانب، ميّز اللسان ثم سُجِّل الشكل و الموقع و أقياسات. قمة اللسان مدوّرة الشكل تقريباً. الجسم مربع الشكل وسماكته تقل تدريجياً باتجاه جذر اللسان. جذر اللسان ينحدر بطنيا خلفيا نحو قاعدة لسان المزمار. المرتفع اللساني في الجزء الخلفي للسطح الظهري. يحتوي السطح الجانبي للسان عدّة حفيرات يمسّ الأسنان قبل

الطواحن. الطول المتوسط للسان الكلي والقمة و الجسم والجذر كانت (0.5 ± 4.5 سم) و (0.23 ± 1.25 سم) و (0.2 ± 2.95 سم) و (0.26 ± 0.9 سم) على التوالي. عرض القمة و الجسم و الجذر في الجزء الأوسع كانت (1 ± 0.49 سم) و (1 ± 0.17 سم) و (1.26 ± 0.22 سم) على التوالي. الألياف العضلية الهيكلية و النسيج الضام الرخو أحيط بظهارة حرشفية مطبقة متقرنة في سطح اللسان الظهري والجانبى وغير متقرنة في السطح اللسان البطني. الحليمات الخيطية تنتشر بكثافة على السطح الظهري لجسم اللسان و أقل كثافة في القمة. في السطح الجانبى للجسم تكون الحليمات الخيطية اقصر من حليمات الجسم والأطول من حليمات القمة. الحليمات الكاسية بيضوية الشكل محاطة بأخدود وبراعم الذوق على الجوانب الظهرية والجانبية. الحليمات الورقية تشبه الورق غير متقرنة وبراعم الذوق على الجوانب الجانبية. الحليمات الفطرائية لها سطح واسع دائري متقرن وبراعم الذوق على الجانب الظهري. الصفيحة الأساسية و تحت المخاطية نسيجاً ضاماً رخوا وغنياً بحزم من الألياف الغراوية.

الكلمات المفتاحية: الخيطية الكاسية الفطرائية, الورقية

Introduction

The rabbit is a widely distributed animal species, commonly used in the laboratory and for economical purposes. It is a model for numerous medical experiments and extensively used in teaching. The rabbit given a separate order because of dentition differences, chiefly the incisors. Addition to that it is an herbivore designed to exist on a diet of succulent green vegetation (1, 2, and 3). The tongue is muscular organ consist of two surfaces and two borders. The tongue regarded highly mobile muscular organ (4 and 1). The lingual surface was characterized by large number projection called the lingual papillae which different in shape and size such as (filiform, fungiform and circumvallate) which found in all animals (2 and 3). The tongue of rabbit has four types of lingual papillae which were dissemination on lingual surface: filiform, foliate, fungiform and circumvallate (5). Filiform papillae were conical in shape and show different heights and thicknesses at various levels. Fungiform papillae were rounded and surrounded by robust filiform papillae. They can also be observed on the tip of the ventral surface. They had taste pores on their surfaces. Circumvallate papillae were encircled by a primary groove and an annular pad. Their taste pores open into

this groove (6). Fungiform, circumvallate, and foliate papillae contain taste buds therefore called lingual gustatory papillae that specialized peripheral sensory organs involved in perceiving chemical stimuli and in taste transduction. Fungiform papillae located on the anterior dorsal surface of the tongue, and a single circumvallate papilla located in the midline at the posterior part of the tongue in rodents (7,8).

This is study designed for available study related with anatomical features and biometrical parameters deals with the anatomy and histology of tongue in wild rabbits due to modicum the researches special with wild rabbits and most it depended on lab. Rabbits in study inside Iraq.

Materials and methods

Anatomical study:

Ten healthy adult male Rabbits randomly had chosen from the AL-Najaf city markets for this study. Anaesthetized with an intramuscular injection of ketamine (35 mg/kg) and xylazine (5 mg/kg) (9), The induction time recorded from the time of injection of Ketamine to the complete loses of consciousness then opened the thoracic cavity and well bleeding by puncher of the heart at the right atrium.

Experimental design in the animals divided into two groups five of rabbits for anatomical study and other five for histological study.

Anatomical depiction was done position, shape, and dimensions were recorded, then the target organ separated carefully and remove of the extrinsic muscles (styloglossal, hypoglossal and genioglossal) from the tongue were done and record the morphological features and biometrical parameters by using vernier callipers, threads and a centimeter scale. Subsequently listed the following data:

- 1- Measured mean length of the total tongue, apex, body, and root.
- 2- Measured mean width of the apex, body, and root at the widest part.

Histological Study:

Five specimen of tongue were dissected out and washed with normal saline solution (0.9% NaCl), after organ cleaned and segmented to four parts (apex, body, and root) put in the special casket were fixed immediately in neutral buffer formalin (NBF10%) at room temperature for 12-24-24 hrs seriatim. The routine histological processing had been doing: (10).

- 1- Digital tissue processor: its contain the serial steps
 - a- Dehydration: seven serial steps of deferent concentrations of ethanol, two hours for each step.
 - b- Clearing: two steps of xylene, one hour for each step.
 - c- Impregnation: two steps of melted paraffin wax (graniferous) (58-60 °C) two hours for each step.
- 2- Semi digital embedding center: contain special molds for formed wax blocks.
- 3- Semi digital rotary microtome: Sectioning measured 5-micrometer thickness.

Staining by:-

- a- Harris hematoxylin and eosin stains. Routine stains used to demonstrate the general histological structure.
- b- Periodic acid-schiff stain (PAS) used this stain to demonstrate the type of glands secretions.
- c- Van Gieson's Stain:- Used this stain for collagen fibers demonstrate.

Results

Anatomical results:

Tongue of adult male rabbit occupies the greater part of oral cavity, extends into oropharynx, root attached with hyoid bone, palatoglossal arch joined the soft palate with the tongue, and its supported by extrinsic lingual and hyoid muscles. The general appearance of the tongue was elongated oval-shape. The tongue was also supported by paired mylohyoideus muscles that sling it between the lower jaws. The tongue can be divided into a free apex, body and attached root (Fig. 1). The apex of the tongue was nearly rounded which formed by meeting of the dorsal and the ventral surfaces, has rounded lateral borders(Fig. 2). Decreased the width and increased the thickness of the apex gradually toward the body. Largest part of the tongue, the body that square-shape, confined between apex and root that starts narrow, then thickening decrease gradually toward root(Fig. 1). The last part of the tongue was the root which slopes ventrocaudally toward the base of the epiglottis. The dorsal surface of the tongue characterized by elevated triangular mass in the caudal part of the body cranial to the root called torus linguae the base toward root and apex toward apex, addition to that the median longitudinal groove which divided this surface to two equal halves which extend from apex of torus linguae to the initial part of the apex of

the tongue (Fig. 1). The ventral surface was shiny-smooth had not any papillae end by frenulum attachment at the body of the tongue. Lateral surface of tongue contain several fossae touching the premolar teeth (Fig. 2 and 3).

The mean length of the total tongue, apex, body, and root were (4.5 ± 0.5 cm), (1.25 ± 0.23 cm), (2.95 ± 0.2 cm), and (0.9 ± 0.26 cm) respectively. Wide of the apex, body, and root at the widest part were (1 ± 0.49 cm), (1 ± 0.17 cm), and (1.26 ± 0.22 cm) respectively. Addition to that four types of lingual papillae were distribution on the tongue surfaces filiform, circumvallate, foliate papillae, and fungiform. The predominant and smallest type of the lingual papillae was filiform which very tiny horny threadlike structures impart a velvety feel of the dorsal surface of the tongue, lateral surfaces of the body, and small part of the ventral surface of the apex. Circumvallate papillae, round and have a depression around the center, with minute elevation from lingual surface, surrounded by papillary furrow at the dorsal surface of the root caudal of the base of the torus linguae (Fig. 1). The foliate papillae appear as several folds, which were located on both posteroperipheral parts of the tongue (Fig. 2). Dome-like fungiform papillae were distributed among the conical filiform papillae of the antero-dorsal part of tongue.

Histological results

The tongue of rabbits in this study histologically made up of interlacing bundles of skeletal muscle fibers and loose connective tissue surrounded by stratified squamous epithelium keratinized at the dorsal and lateral lingual surfaces, non-keratinized at the ventral lingual surface. Dermal papillae at the apex longer than other parts of the tongue (Fig. 4). Numerous

irregular elevations papillae were distribution on the dorsal and lateral lingual surfaces. Filiform papillae elongated cone-shaped heavy distribution on the body characterized by vertico-caudally orientation and a depression on the posterior part (Fig. 5), whereas at the apex Filiform papillae were scanty distribution characterized by small keratinized caudal pointed projection (Fig. 4). At the lateral surface of the body filiform papilla near foliate papillae they smaller than dorsal papillae and longer than apex papillae (Fig. 6). Two Circumvallate papillae were round to oval-shape, surrounded by a moat-like trough and were level with the dorsal surface of the root of tongue caudal of bas of torus linguae. Numerous oval intraepithelial organs (taste buds) were found on the dorsal and lateral sides of the Circumvallate papilla and in the epithelium on the wall of the furrow facing the moat and appear as lighter staining areas in the epithelium (gave negative reaction with PAS stain) (Fig. 7). Serous glands (von Ebner's) opened at the base of circular furrow via excretory ducts (gave negative reaction with PAS stain). Foliate papillae were non-keratinized and leaf-like parallel with each other made up of a series of parallel mucosal folds with taste buds on the lateral walls (Fig. 6). Fungiform papillae had broad rounded keratinized surface, and projects above the surface of the tongue, with taste buds on the dorsal surface, they distributed at anterior part of the tongue between the filiform papillae.

Lamina propria-submucosa was loose connective tissue with rich bundles of collagen fibers (gave positive reaction with VG stain) (Fig. 5). Thickness of lamina propria-submucosa varied, at the root related with furrow of circumvallate papillae

very restricted lamina propria-submucosa (Fig. 8), at the lateral surface related with foliate papillae it was more than the later (Fig. 6), at the apex it was more than the later (Fig. 4), and at the body it was more than the later (Fig. 9). Lamina propria-submucosa very vascular, mucous salivary acini with excretory ducts which scattered at the body and root of

the tongue (gave positive reaction with PAS stain) (Fig. 9), skeletal muscle fibers were grouped into bundles separated by connective tissue cross each other in three planes each plane arranged at right angles to the other two, and adipose and lymphatic tissues were scattered between skeletal muscle fibers (Fig. 6, 7, 8, and 9).

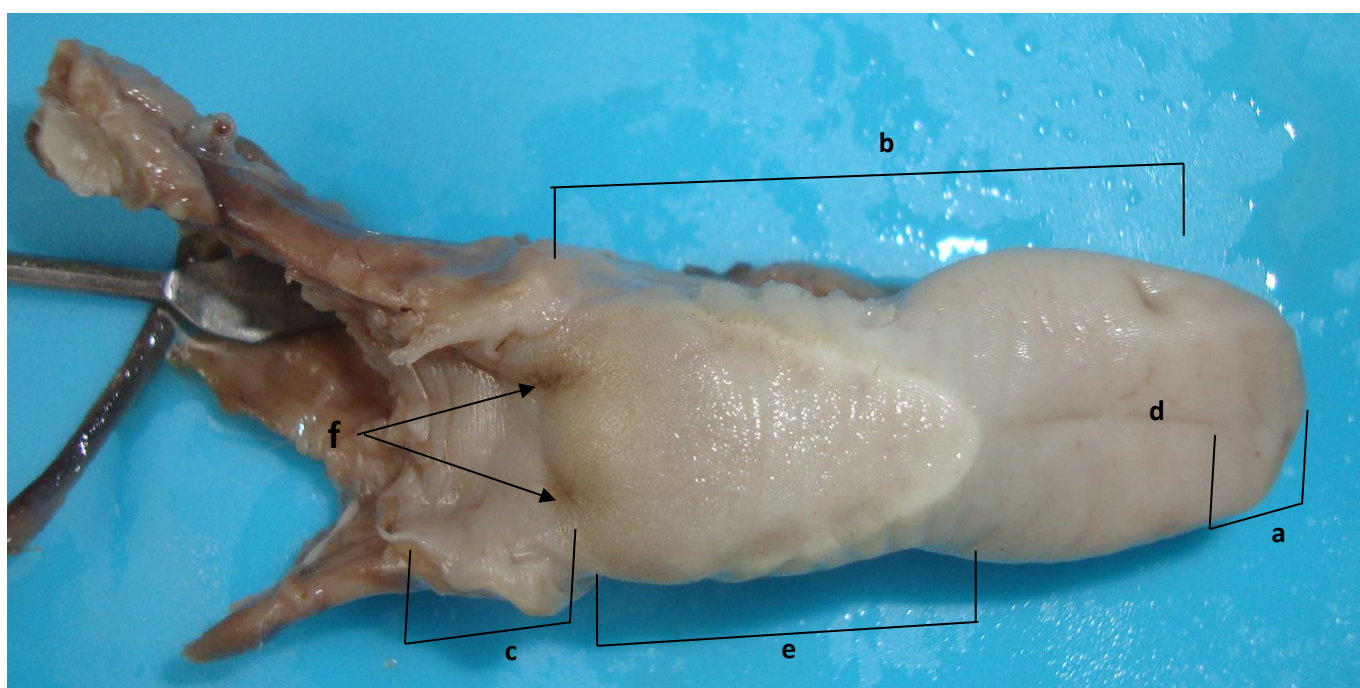


Fig. (1): Dorsal view of the tongue of the rabbit showing: Apex (a), Body (b), Root (c), Median longitudinal groove (d), Torus linguae (e), Circumvallate papillae (f).

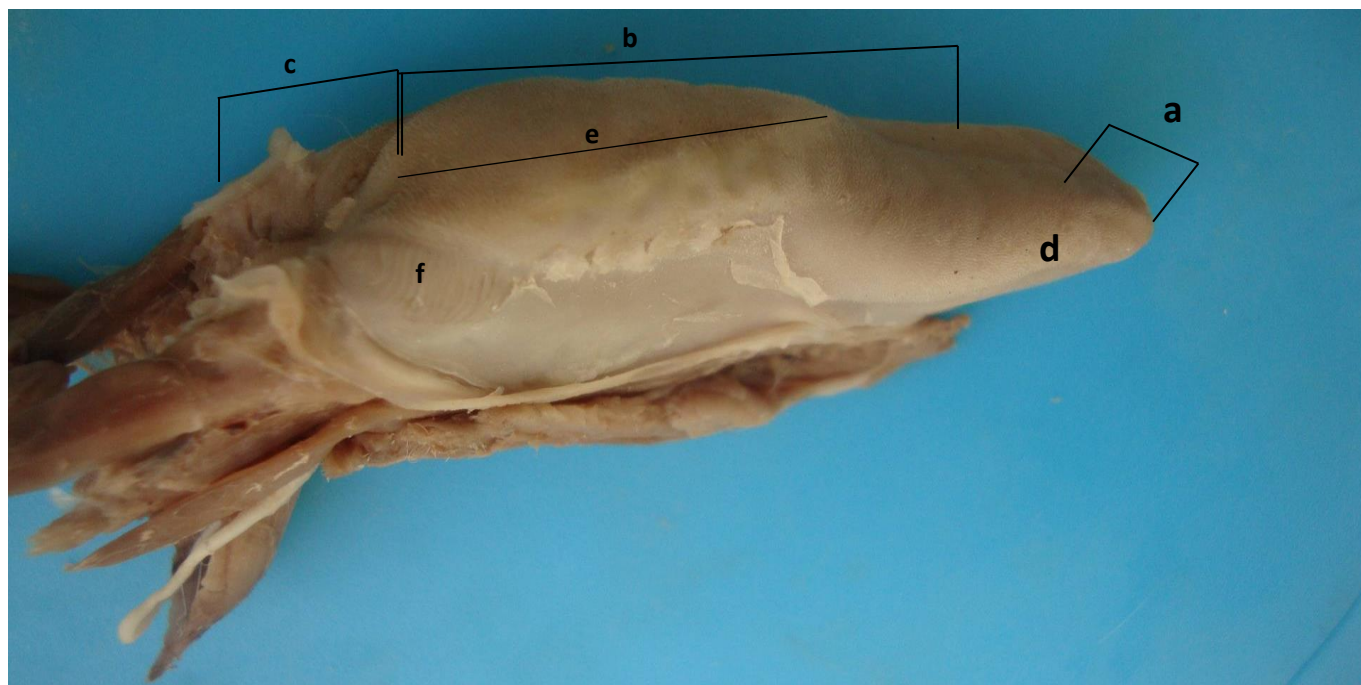

Fig. (2): Laterodorsal view of the tongue of the rabbit showing: : Apex (a), Body (b), root (c), lateral border of apex (d), Torus linguae (e), Foliate papillae (f).

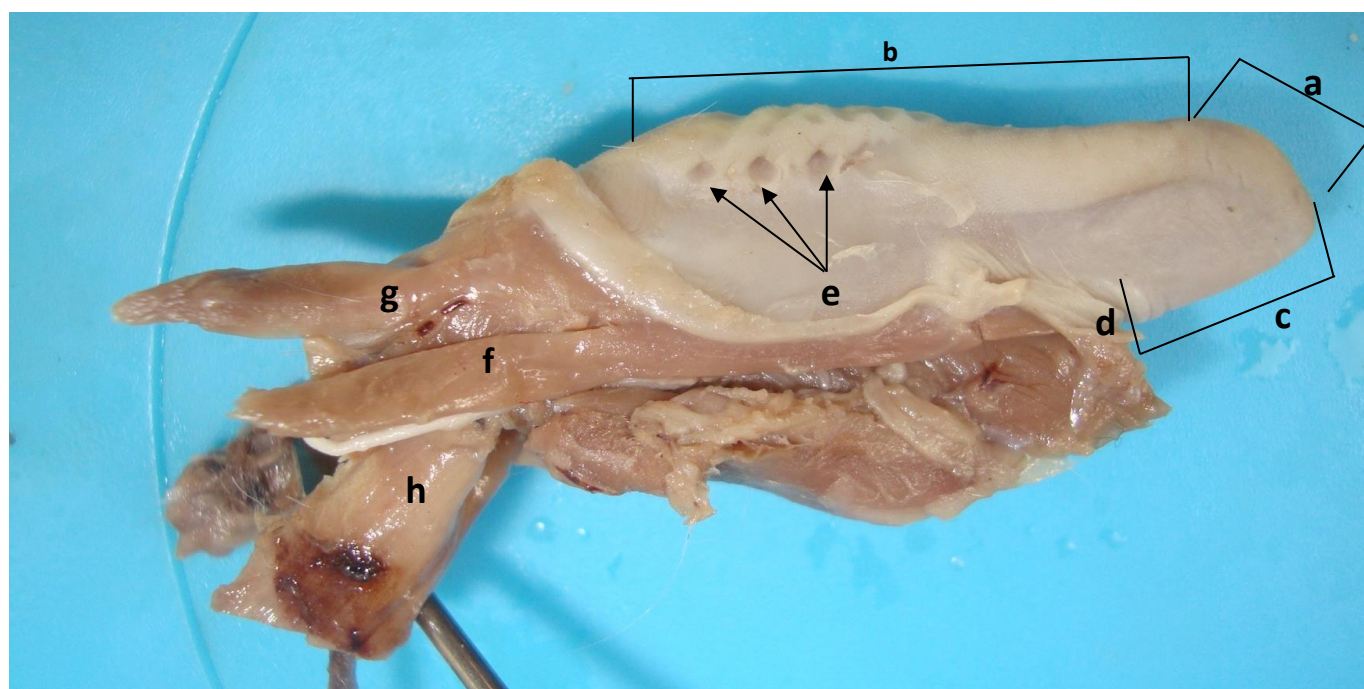


Fig. (3): Lateroventral view of the tongue of the rabbit showing: : Apex (a), Body (b), ventral surface (c), frenulum of tongue (d), Lateral fossae (e), Geniohyoideus muscle(f), Styloglosseus muscle (g), Larynx(h).

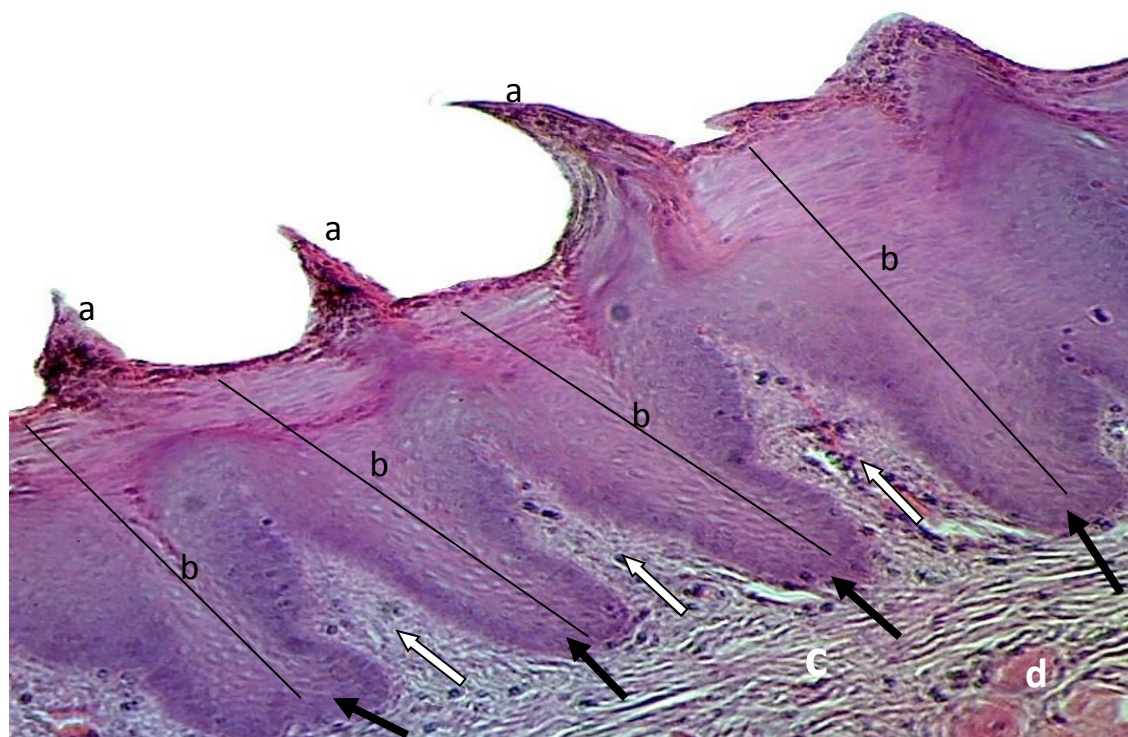


Fig. (4): Dorsal view of the apex part of the tongue of the rabbit showing: Filiform papillae (a), stratified squamous epithelium keratinized(b), dermal papillae (white arrows), epidermal pegs (black arrows), lamina propria-submucosa (c), skeletal muscle fibers (d). **H & E Stain X40**

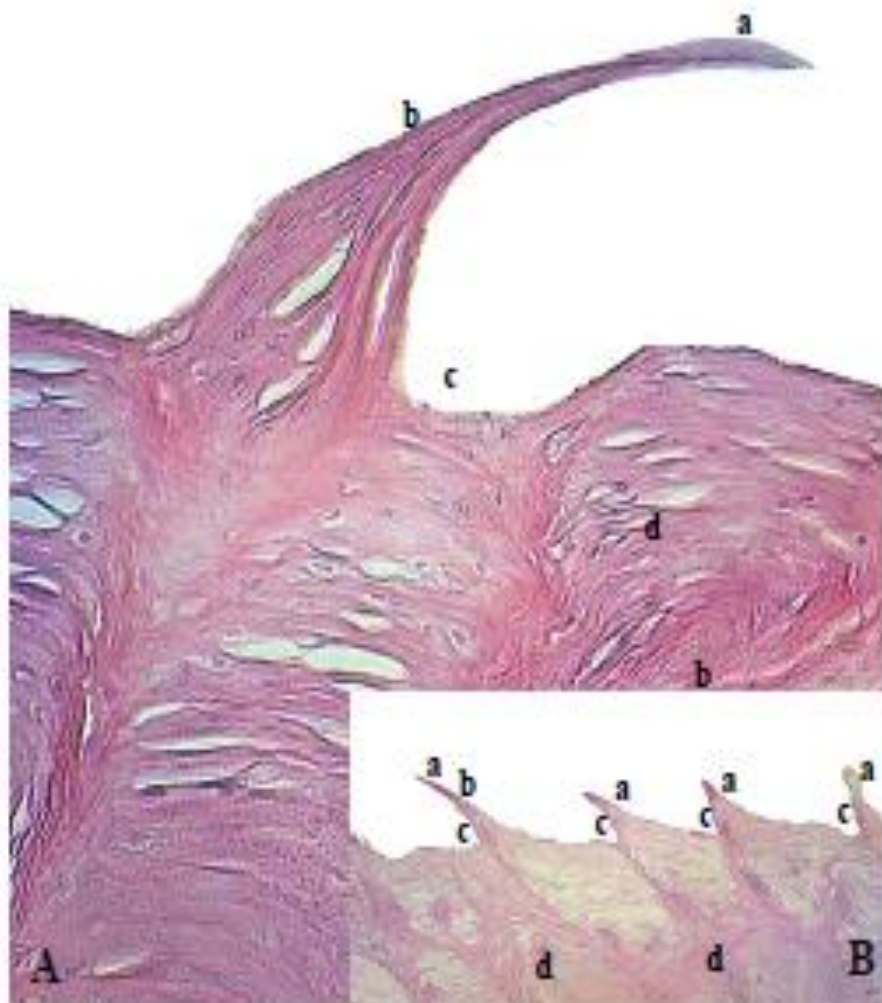

Fig. (5): (A & B) Filiform papillae of the dorsal surface of the body showing: keratinized tip of the filiform papillae (a), shaft of the filiform papillae (b), posterior depression of the filiform papillae (c), keratin of the dorsal surface of the tongue(d).

H & E Stain X40

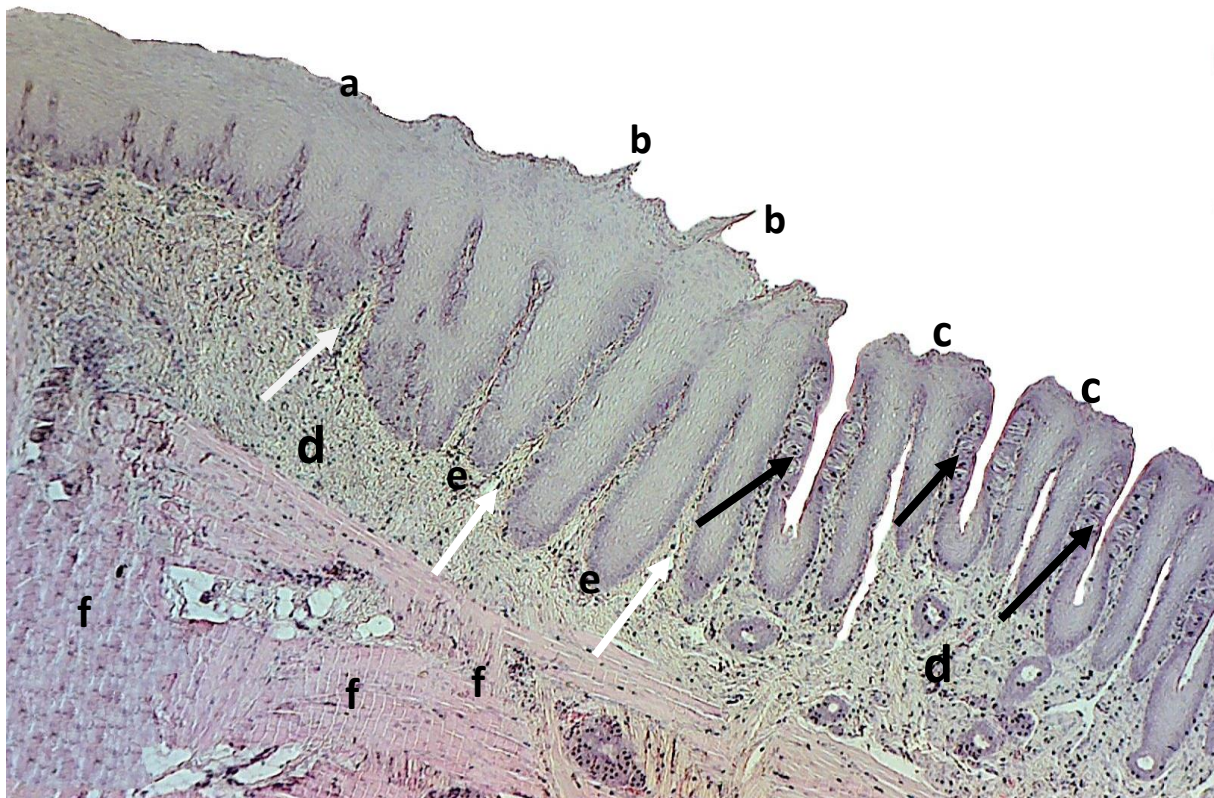


Fig. (6): lateral view of the root part of the tongue of the rabbit showing: stratified squamous epithelium keratinized (a), filiform papillae (b), foliate papillae (c), lamina propria-submucosa (d), epidermal pegs (e), dermal papillae (white arrows), skeletal muscle fibers (f), taste buds (black arrows).
H & E Stain X40

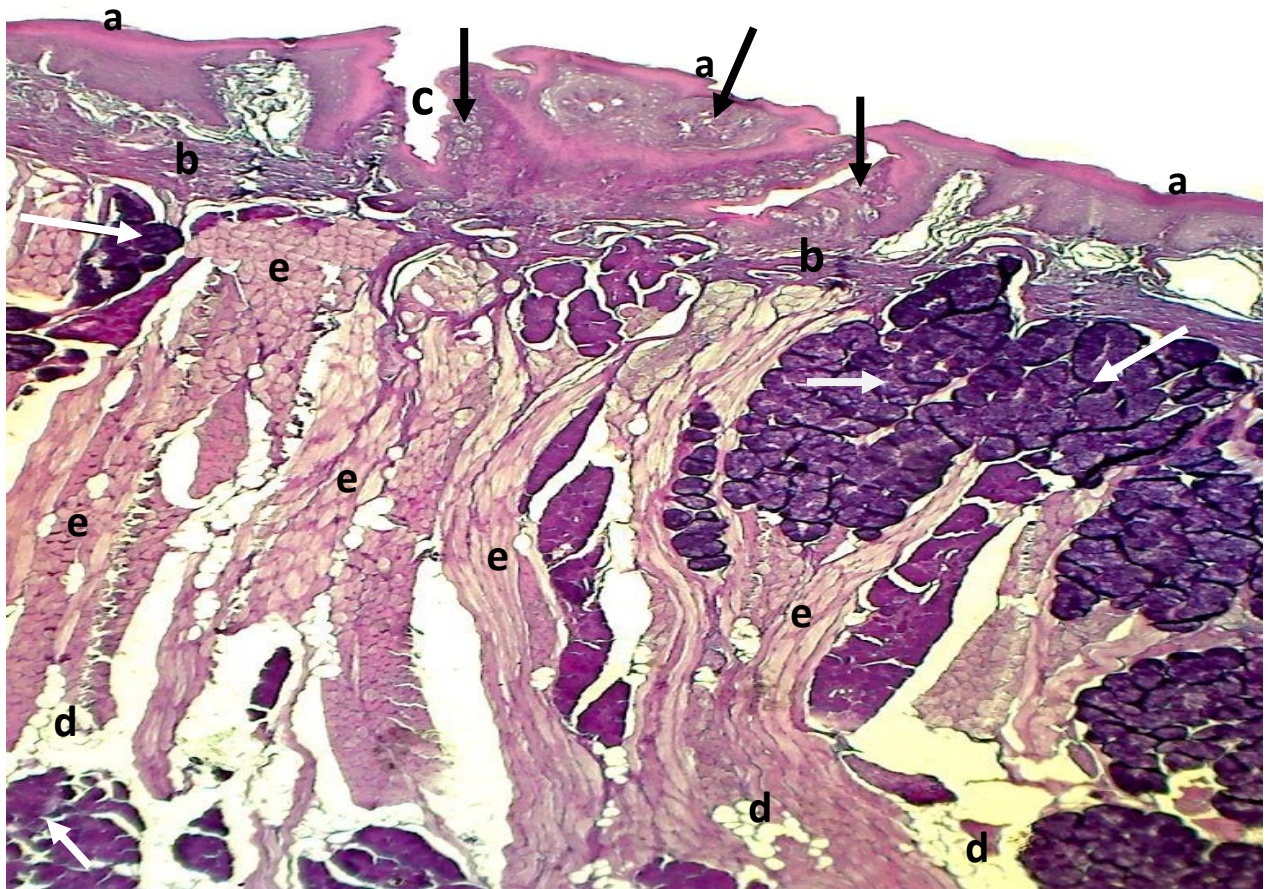


Fig. (7): Circumvallate papilla at dorsal surface of the root part of the tongue of the rabbit showing: stratified squamous epithelium keratinized (a), restricted lamina propria-submucosa (b), circular furrow (c), adipose tissues (d), skeletal muscle fibers (e), taste buds (black arrows), mucous salivary glands (white arrows).
PAS Stain X40

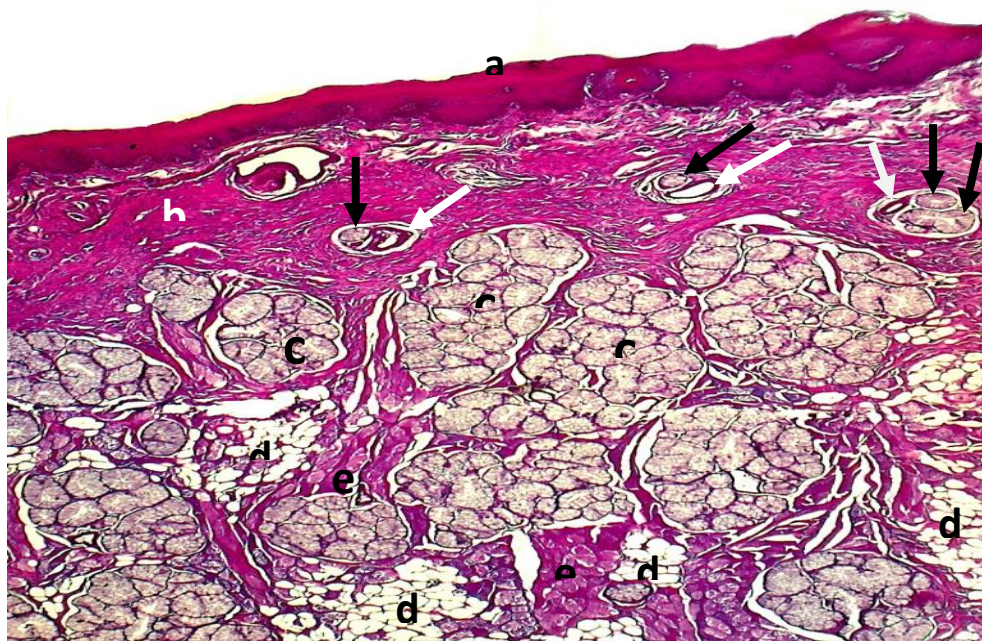


Fig. (8): Dorsal view of the body part of the tongue of the rabbit showing: stratified squamous epithelium non-keratinized (a), laminapropria-submucosa rich by collagen fibers (b), mucous salivary glands (c), adipose tissues (d), skeletal muscle fibers (e), glandular ducts (black arrows), blood vessels (white arrows).

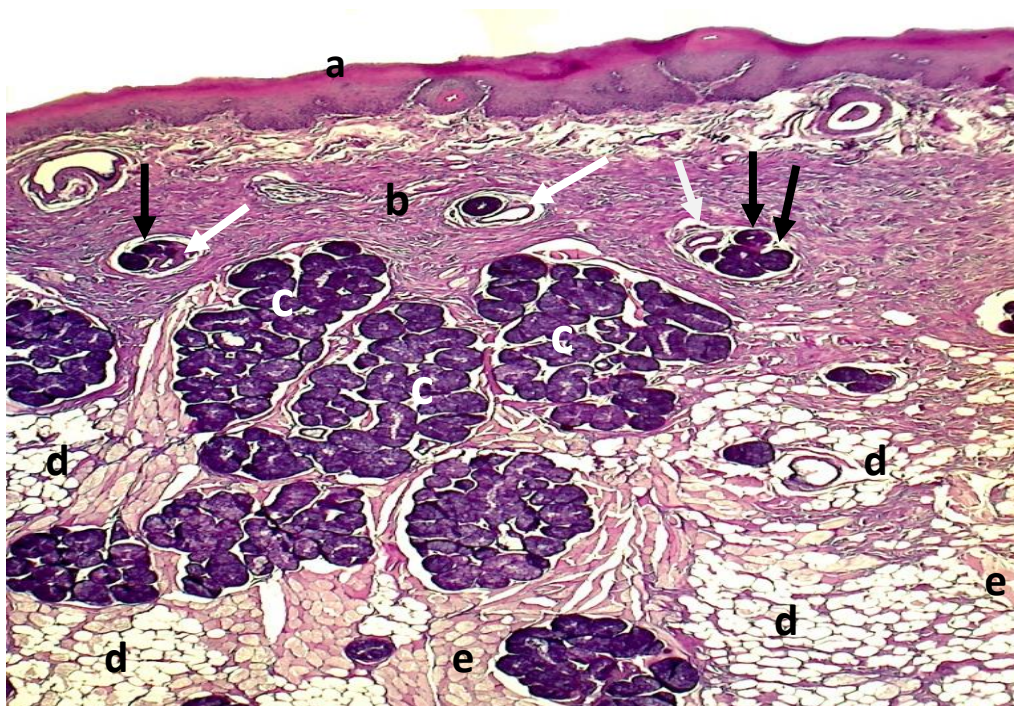


Fig. (9): Dorsal view of the body part of the tongue of the rabbit showing: stratified squamous epithelium keratinized (a), laminapropria-submucosa rich by collagen fibers (b), mucous salivary glands (c), adipose tissues (d), skeletal muscle fibers (e), glandular ducts (black arrows), blood vessels (white arrows).

PAS Stain X40

Discussion

Appearance of the tongue was appropriate with the anatomical structures of the oral cavity like rabbit in this study different from tongue in other animals like donkey *Equus asinus* observed that the spatula-shaped tongue (11). Type of food play very important role in the all anatomical features of the tongue, its highly muscular organ capable of both vigorous and precise movements, the mobility was achieved by restricting the attachments to the more caudal part, which leaves the apex free to roam both within and beyond the mouth as in prehension, lapping, grooming, and manipulating the food within the mouth on the one hand and speech articulation on the other, (4, 1, and 12). Color of the tongue of the rabbits in this study was homogenous white-pink this outcome unaccordance with (13, 14) who said the tongue of sheep was pigmented. The apex characteristics of the tongue of the rabbits in this study corresponded with of the (14) in sheep, but uncoincided with him in the shallow median longitudinal groove on the dorsal surface of apex, with (15) who mentioned that, the apex of the tongue was notched in the center and somewhat flattened in goat, and with (16, 17, 18, and 19) who elucidated the apex of the tongue was free and pointed with blunted rounded margin in ox and buffalo, The differences related to the species of animals. The prominent torus linguae of the posterior area of the body of the tongue like other grass eating animals which have a well-developed torus linguae (16, 13, 15, 19, 20, 21, 22, 23, and 18). While incompatibility with the (24) who elucidated in the rabbit tongue, a torus lingual was observed in the middle part of the tongue. Distribution

of the four types of the lingual papillae coordinated with (24) in the rabbits. But uncoordinated with (14, 20, and 19) who elucidated that the filiform papillae were densely pavement distributed on the dorsal and ventral surfaces of the apex of the tongue, the height of papillae increased caudally toward the pharynx in sheep, small ruminants, and buffalo, (17, 20) who clarified they present only on the dorsal surface in ox, buffalo, and horse, and with (25) said the filiform papillae are most numerous and distributed over the dorsal anterior portion of the tongue of the adult Egyptian bat (*Pipistrillus kuhli*). Addition to that (26) mentioned that the filiform papillae, which found in apex is larger than that found on the body and the height of papillae increased toward the apex in cattle. Density and shape of filiform papillae impart a velvety feel and gave the tongue a rough surface assist to grooming, movement of the food toward the pharynx and provide additional protection for the tongue (17, 19, 20 and 27). Position and number of the circumvallate papillae fully confirmed with (anatomy of horse) in horse. While deferent with small and large ruminants they arranged in two row has "V" shape (14, 28, 29, 30, 20, 31). Foliate papillae in rabbit they are well developed, whereas in the cats were rudimentary, and in ruminants were not present (32, 33). Anatomical appearance and distribution of the fungiform papillae in our study were agreement with (34, 35) in rabbit, while (36) said it was found on the dorsal surface of the apex and body of the tongue in the front of the torus of the tongue, on the margins of the tongue, and laterally in relation to the torus of the tongue and are arranged linearly in rabbit. And (37) said they were most numerous in the

peripheral region than the dorsal surface in cat. Whereas (38) explained they were present on the dorsal surface of the apex in horse. And they scattered on the dorsum of tongue among the filiform papillae of ruminants. in sheep (6-28, 7-28, 39, and 40), in goat (15, 18, 30, and 5), in camel (5 and 6), in cow (41).

Wide mobility of the tongue necessary for phonating, chewing, and swallowing depend upon the Interlacing bundles of skeletal muscle fibers and its connective tissue, they may enable the dorsum of the tongue to harden for pressing food during mastication and shifting the food posteriorly for swallowing (42, 43, 44). Addition to that coarseness of the lingual surfaces depends on the type and degree of contact of food and cornified nature of these surfaces, this cornified because types and heavy distribution of the lingual papillae on the other hand. These were effectively increased on the surface areas and play the functional role of receiving the taste sense. (45)

The dorsal surface of the tongue in this study appears bristlier than the other, and ventral surface non-keratinized this fact irregularity with (24) said all surfaces of the tongue were had cornified epithelium, but the dorsal epithelium was thicker than the lateral and lower ones in rabbit. Variety of filiform papillae in this study incongruity with (24) who explained filiform papillae in the anterior part were numerous, conical shaped with vertical orientation, and a depression on the posterior part; but in front of the torus they were relatively tighter and taller than the papillae in the anterior part. These variations depend upon the degrees of food contact and animal used of the tongue in the daily uses. Appearance of the

fungiform papillae were not in agreement with (24) who said fungiform papillae were elliptical or circular shape. foliate and vallate papillae corresponding with (24).

References

- 1- Hristovl H, Kostoll D, and Vladova D (2006). Topographical anatomy of some abdominal organs in rabbits. *Trakia J. of Sci*, **4 (3) pp: 7-10**
- 2- Brewer N R (2006). Historical Special Topic overview on Rabbit Comparative Biology. Biology of the Rabbit. *J. of the American Asso. for Lab. Ani. Sci.* **45(1) pp: 8-24.**
- 3- Herron FM (2002). A study of digestive passage in Rabbits and Ringtail possums using markets and models. **PhD. Thesis. Sydney Uni. School of Bio. Sci. PP: 1-20.**
- 4- Frandson RD, Wilke WL, and Fails AD (2009). Anatomy and Physiology of Farm Animals 7th (ed.): **Wiley-Black Well. PP: 335-350**
- 5-Korans N S and Bachir M H (2004). Morphofunctional Study of Different Tongue Papillae in Ruminants and Rodentia, a Scanning Electron Microscopic and Histological Studies. *Cairo Dental J.* (1) **215-220.**
- 6- [Qayyum](#) MA, [Fatani](#) JA, and [Mohajir](#) AM (1988): Scanning electron microscopic study of the lingual papillae of the one humped camel, (*Camelus dromedaries*). *J. Anat.* (160) **pp 21–26**
- 7- Ringstedt T, Ibáñez CF, and Nosrat CA (1999). Role of Brain-Derived Neurotrophic Factor in Target Invasion in the Gustatory System. *J. of*

- Neuroscience, 19(9): 3507-3518.**
- 8- Bacha WJ, and Bacha LM (2000). Color Atlas of Veterinary Histology 2nd (ed.): **Lippincott Williams & Wilkins. PP: 119-121**
 - 9- Fish RE, Brown MJ, Karas AZ (2008). Anesthesia and Analgesia in laboratory Animals. 2nd (ed.): **American coll. of Lab. Ani. Med. Serv. pp: 302-305**
 - 10- Luna LG (1968). Manual of histologic staining methods of the armed forces institute of pathology 3rd (ed.): **Mc Graw-Hill book Co. N.Y. PP: 32-153**
 - 11- Abd-Elnaeim [M MM](#), Zayed A E, Leiser R (2002) Morphological characteristics of the tongue and its papillae in the donkey (*Equus asinus*): a light and scanning electron microscopical study. **Ann. Anat. 184 (5) pp 473-480**
 - 12- Dyce KM, Sack WO, Wensing CJG (2010). Veterinary Anatomy. 4th (ed.): **Sauders 3251 River port Lane st. Louis Missouri 63043. pp: 104-105**
 - 13- May N D (1970). The Anatomy of the Sheep. 3rd (ed)., **Brisbane. Australia Uni. of Queen land Press.**
 - 14- Murad NA, Hassan NH, Abid TA (2010): Anatomical study of the tongue in adult Rams. **Al. Qadisiya sci. J of vet. Medi.1 (2).**
 - 15- Qayyum M A, and Beg M A (1975). Anatomical and neurohistological observations on the tongue of the Indian goat (*Capra aegagrus*). **Acta. Anat. (93) pp 554-567.**
 - 16- Getty R (1975). The Anatomy of Domestic Animals. 5th ed. **W.B. Saunders Company. Philadelphia.**
 - 17- Prakash P, and Rao G (1980). Anatomical and neurohistological studies on the tongue of the Indian buffalo (*Bubalus bubalis*). **Acta. Anat. (107) pp 373-383.**
 - 18- Kurtul I, and Atalginb S H (2008). Scanning electron microscopic study on the structure of the lingual papillae of the Saanen goat. **Small Ruminant Research 80, 52-56.**
 - 19- Al-jebori J G (2007). Anatomical and Histological Study of the Tongue in Buffaloes (*Bubalus bubalis*) in Middle of Iraq. **Msc.thesis, Univ. of Baghdad.**
 - 20- Nickel R Schummer A and Seiferle E (1979). The Viscera of the Domestic Mammals "Digestive System" Verlag Paul Parey, **Berlin Hamburg. pp 23-203.**
 - 21- Agungpriyono S Yamada J Kitamura N Nisa C Sigit k and Yamamoto Y (1995). Morphology of the dorsal lingual papillae in the lesser mouse deer, *Tragulus javanicus*. **J. Anat.(187) pp. 635-640.**
 - 22- Eerdunchaolu K, Takehana E, Yamamoto A, Kobayasi A, Co G, Baiyin H, Lleda H, and Tangkawattana P (2001). Characteristics of dorsal lingual papillae of the Bactrian camel (*camelus bactrianus*). **Anat. Histo. Embryo. (30) pp147-151.**
 - 23- Zheng J and Kobayashi K (2006). Comparative morphological study on the lingual papillae

- and their connective tissue cores (CTC) in reeves' muntjac deer (*Muntiacus reevesi*). **Ann. Anat. (188) 555-564**
- 24- Silva MCP, Watanabe I, Kronka MC (2002). Three-dimensional architecture of the connective tissue core and surface structures of the lingual papillae in the rabbit. **Histol. Histopathol. (17) pp: 455-461**
 - 25- Selim A, Nahla N E, Shelfeh M (2008). Comparative Anatomical and Histological Studies of the Tongue between the Egyptian Bat (*Pipistrillus Kuhli*) and the Syrian Bat (*Pipistrillus Kuhli*). **Tishreen Univ. J. for Research and Sci. Studies – Bio. Sci. 30(1) pp 247-255**
 - 26- Sari E K Harem M K and Harem I S (2010). Characteristics of dorsal lingual papillae of zavot cattle. **J. Ani. Vet. Advances 9 (1) pp 123-130.**
 - 27- Reece, W.O. (2005): Digestion and absorption. In: Function Anatomy and Physiology of Domestic Animals 3rd (ed.): **Lippincott Williams and Wilking. pp 316-316**
 - 28- Tadjalli M (2004). Scanning electron microscopic study of the lingual papillae in newborn lambs. **Iranian J. 5 (2).**
 - 29- Tadjalli M, and Pazhoomand R (2004). Tongue papilla in lambs: a scanning electron microscopic study. **Small Rum. Res. (54) pp157–164.**
 - 30- Kumar P Kumar S and Singh S (1998). Tongue papillae in the goat: a scanning electron microscopic study. **Anat. Histol. Embryo. (27) pp 355-357.**
 - 31- Parvez MNH, Rahaman MT (2005). Anatomical study of tongue of indigenous Cow(*Bos Indicus*) in Bangladesh with special emphasis on papillae distribution. **Bangladesh J. of Vet. Med. 3 (2).**
 - 32- Samuelson, D.A. (2007): Text book of Veterinary Histology. **Saunders Elsevier. PP. 315-320**
 - 33- Ojima K, Mitsunashi F, Suzuki Y, Matsumoto S (1999). Classification of angioarchitectural structures of the rabbit tongue foliate papillae in scanning electron microscopic specimens. **J. Shigaku (Odontology) Springer-Verlag 86 (4) pp 759-767**
 - 34- Ojima K, Matsumoto S, Saiki C, Takahashi T, Takeda M and Mitsunashi F (1997). Angioarchitectural structure of the fungiform papillae on the anterodorsal surface of the rabbit tongue. **Ann. Anat.179 pp 329–333.**
 - 35- Ojima K, Mitsunashi F, Nasu M, Suzuk Y (2000). Functional angiocarchitectural comparison of the fungiform papillae of rat, rabbit, cat in scanning electron microscopic specimens. **Ann. Anat. 182 (5) pp 451–457.**
 - 36- Kulawik M, Godynicki S (2007). Fungiform papillae of the tongue in the rabbit (*Oryctolagus cuniculus*). **J. Vet. Sci 10 (1) pp 25-27.**
 - 37- Ojima K (1998). Quantitative and distributive study of the fungiform papillae in the cat tongue in microvascular cast specimens. **Ann. Anat. 180 (5) pp 409–414.**

- 38- Budras KD, Sack WO, Röck S (2009). Anatomy of the horse. 5th (ed.). **Schlütersche Verlagsgesellschaft mbH and Co. KG. Hans-Böckler-Alle pp 44-45.**
- 39- Emura S, Tamada A, Hayakawa D, Chen H, and Shoumura S (2000). Morphology of the dorsal lingual papillae in the Barbary sheep. **Ammotragus lervia. Okajimas Folia Anat Jpn. 77(2-3) pp 39-45.**
- 40- Kumar P Sagar D Ganganaik S Jain R K and Gupta A N (2003). Scanning electron microscopic studies on the tongue papillae of sheep. **Indian J. of Ani. Sci. 73(5) pp. 488-490.**
- 41- Tabata S Kudo K I Takemura A W Nishimura S and Iwamoto H (2006). Structure of bovine fungiform taste buds and their immunoreactivity for gustducin . **J. Vet. Med. Sci. 68(9) pp 953-957.**
- 42- Davies RR, and Davies J (2003). Rabbit gastrointestinal physiology. **Vet. Clinics Exotic Animal (6) pp: 139-153**
- 43- Saito H, Itoh I (2003). Three-dimensional architecture of the intrinsic tongue muscles, particularly the longitudinal muscle, by the chemical-maceration method. **Anat. Sci. International 78 (3) pp 168-176**
- 44- Oliveira J L, Watanabe I, Ogawa K, Motoyama A A, Silva M C P d, Kronka M C (2004). Ultrastructural aspects of the muscle of the anterior third of Rabbit tongue. **Braz. J. morphol. Sci. 21(1) pp25-29.**
- 45- Ojima K, Takeda M, Matsumoto S, Nakanishi I (1997). Microvascular fin-like structure of the foliate papillae of the rabbit tongue using scanning electron microscopic specimens. **Ann. Anat.179 (6) pp 511-515**